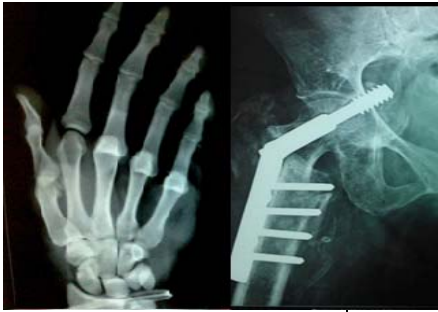



# International Journal of Orthopaedics Sciences

ISSN: 2395-1958  
IJOS 2016; 2(4): 214-217  
© 2016 IJOS  
www.orthopaper.com  
Received: 04-08-2016  
Accepted: 05-09-2016

**Dr. Ravikumar AS**  
Assistant Professor Department  
of Orthopaedics Sri Siddhartha  
Medical College Agalakote,  
Tumkur, Karnataka, India

**Dr. Veeranna HD**  
Professor Department of  
Orthopaedics Sri Siddhartha  
Medical College Agalakote,  
Tumkur, Karnataka, India

**Dr. Jaipalsinh R Mahida**  
Junior Resident Department of  
Orthopaedics Sri Siddhartha  
Medical College Agalakote,  
Tumkur, Karnataka, India

## Treatment of fracture shaft humerus with dynamic compression plate osteosynthesis – A prospective study

**Dr. Ravikumar AS, Dr. Veeranna HD and Dr. Jaipalsinh R Mahida**

**DOI:** <http://dx.doi.org/10.22271/ortho.2016.v2.i4d.34>

### Abstract

**Background and Objectives:** Fractures of Humeral shaft account for approximately 3% of all long bone fractures. Most will heal with appropriate conservative care, although a small but consistent number will require surgery-for optimal outcome. The aim of this study is to assess the results of humeral shaft fractures with dynamic compression plate (DCP).

**Methodology:** This is a prospective study of 20 cases of fracture shaft of humerus admitted to Sri Siddhartha Medical College & Research Center, Tumkur, between July 2005 to October 2006. Cases were taken according to inclusion and exclusion criteria.

**Results:** In our series of 20 cases there were 18 males and 2 females, with average age of 33.4 yrs. 16(80%) cases were admitted due to road traffic accident and with copal side affected. Out of 20 cases, 2(10%) were proximal third, 16(80%) were middle third and 3 (9%) were distal third. Transverse or short oblique fractures were most common i.e., 14(70%) patients. 7(35%) cases were having associated injuries. The fractures united in 19(95%) patients with 1(5%) cases going for non-union due to deep infection in one, in other case may be due to immediate weight bearing activity done by the patient. Good or full range of mobility of shoulder and elbow joints was present in 19 (95%) patients.

**Conclusion:** Internal fixation of the humerus with DCP achieves higher union rates and comparable better results as compared to other modes of treatment.

**Keywords:** Humeral shaft, fractures, dynamic compression plate, transverse, short oblique, non-union, delayed union

### 1. Introduction

A fracture of the humeral shaft is a commonly encountered by orthopaedic surgeons and representing between 3% and 5% of all fractures [1, 2]. Most will heal with appropriate conservative care, although a small but consistent number will require surgery for optimal outcome [1, 3, 4]. Given the extensive range of motion of the shoulder and elbow, and the minimal effect from minor degrees of shortening, a wide range of radiographic malunion can be accepted with little functional deficit [5].

Current research in this area focuses on defining the incidence and health care resources required to treat this injury, refining the indications for surgical intervention, decreasing the surgical failure rate through new implants and techniques, and minimizing the duration and magnitude of disability postinjury [2, 6, 7].

The successful treatment of a humeral shaft fracture may not end with bony union: in the current emphasis on a "holistic" approach to patient care the treating orthopaedic surgeon may be in an ideal position to intervene and improve a patient's life beyond what is traditionally recognized as the surgeons' role [8].

As with most orthopaedic injuries, the successful treatment of a humeral shaft fracture demands a knowledge of anatomy, surgical indications, techniques and implants, and patient functions and expectations [8].

With this background, this study is to determine the efficacy of Dynamic Compression Plate in the treatment of humeral shaft fractures.

**Correspondence**  
**Dr. Jaipalsinh R Mahida**  
Junior Resident Department of  
Orthopaedics Sri Siddhartha  
Medical College Agalakote,  
Tumkur, Karnataka, India

## 2. Material and Methods

A prospective study of 20 patients who had sustained fracture shaft of humerus were treated by open reduction and internal fixation using dynamic compression plate at Sri Siddhartha Medical College and Hospital from July 2005 to October 2006. All skeletally matured patients willing to give consent were included. Patients were assessed clinically to evaluate their general condition and the local examination where palpation revealed tenderness, abnormal mobility, crepitus and shortening of the affected arm. Distal vascularity was assessed by radial artery pulsations, capillary filling, pallor, paresthesia at fingertips. Radial nerve was tested by active wrist and metacarpophalangeal joint dorsiflexion. Sensation in the autonomous zone of 1st web space was checked for any abnormality. Standard radiographs of the humerus with shoulder and elbow joint in anteroposterior and lateral views were obtained. The limb was immobilized in a U-slab with sling. Injectable analgesics were given.

Adequate medical management of associated comorbid condition were initialized to optimize patient's fitness.

### 2.1 Surgical Approach

All cases were operated under general anesthesia via Anterolateral approach (Thompson, Henry) in supine position and Posterior (Berger & Buckwalter) approach in lateral or prone position.

**2.1.1 Anterolateral approach:** Skin was incised in line with the anterior border of the deltoid muscle from a point midway between its origin and insertion, distally to the level of its insertion and then proceed in line with the lateral border of the biceps muscle to within 7.5 cm of the elbow joint<sup>[9, 10]</sup>.

Divide the superficial and deep fascia and ligate the cephalic vein. In the proximal part of the wound retract the biceps medially and the deltoid laterally to expose the shaft humerus. Distal to the insertion of the deltoid, expose the brachialis muscle, split it longitudinally to the bone, and retract subperiosteally the lateral half to the lateral side and medial half to the medial. Retraction is easier when the brachialis is relaxed by flexing the elbow to a right angle. The radial nerve as it winds about the humeral shaft, is protected by the lateral half of the brachialis muscle.

**2.1.2 Posterior approach:** Make a longitudinal incision in the midline of the posterior aspect of the arm, from 8cm below the acromion to olecranon fossa.

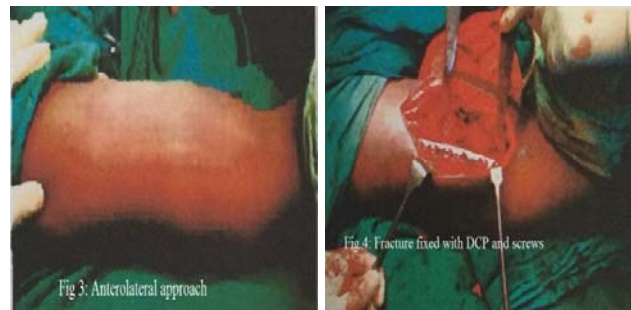
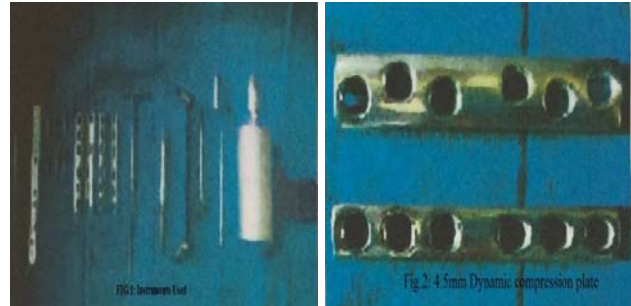
To identify the gap between the lateral and long heads, begin proximally, above the point at which the two heads fuse to form a common tendon. Proximally, develop this interval between the heads by blunt dissection, retracting the lateral head laterally and the long head medially. Distally, the muscle will need to be divided by sharp dissection along the line of the skin incision. Incise the exposed medial head in the midline, continuing the dissection down to the periosteum of the humerus. Then strip the muscle off the bone by subperiosteal dissection. The bone cannot be exposed effectively above the spiral groove using the posterior approach. At this point, the deltoid muscle also crosses the operative field. More proximal exposures should be accompanied by the anterior route. The skin incision can be extended distally over the olecranon; deepening the approach provides access to the elbow joint via olecranon osteotomy.

Fractured reduced and fixed with contoured 4.5mm DCP self-compression plate. Lag screw were placed in oblique type of fractures. Remaining screw were inserted in neutral position. Wound closed in layers and clean dressing applied. And

immobilized with arm pouch<sup>[11]</sup>.

All patients were followed at monthly interval for first 3 months, later at 2 monthly till fracture union and once in six months till completion of study. At each follow up patients were evaluated for function pain, range of movement and functional outcome with the American shoulder and elbow surgeons score (ASES) and radiological fracture union.

### 2.2 Operative Photographs



### 3. Results

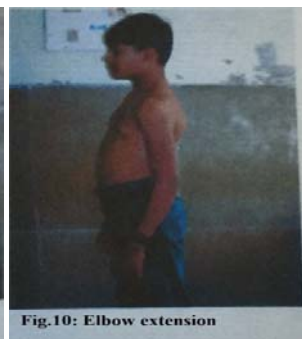
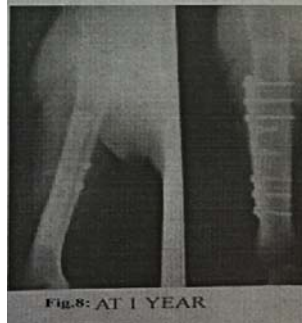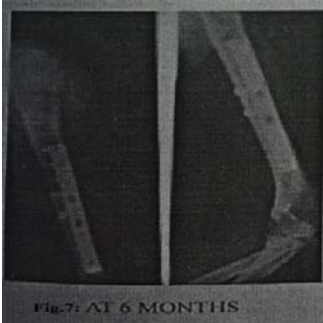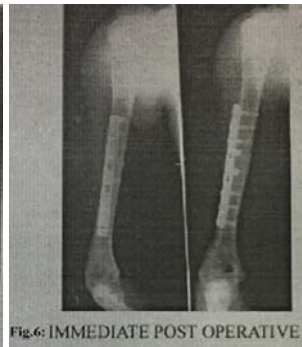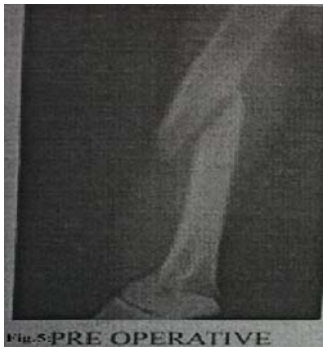Data was collected based on detailed patient evaluation with respect to history, clinical examination and radiological evaluation. The postoperative evaluation was done both clinically and radiologically. Out of 20 patients all cases were available for follow up.

The mean age of patient was 33.4 years (18- 65 yrs) which included 18(90%) male and 2 (10%) females. Laterally pattern was 50% both right and left. Road traffic accident was most common mode of injury accounting for 80% whereas injury due to fall accounted 20%. Majority of fractures were at the level of middle third of humerus (80%) and mainly closed type. 70% (14 cases) were transverse or short oblique type of fractures where comminuted 20% (4 cases) and long oblique 10% (2 cases) were present. Majority of patients 19(95%) has sound union in 6 months with non-union seen in one patient.

There were 2 cases of postoperative complications, 1(5%) non-union and 1(5%) radial nerve palsy. 15(75%) patients recovered full range of motion of shoulder and elbow joint while A 4 patients recovered good range of motion (within 10-15% of full range) and 1 (5%) patient had poor range of movements.

The American Shoulder and Elbow Surgeons (ASES) shoulder score is for 13 activities of daily living requiring full shoulder and elbow movement. The maximum possible score is 52 points. The average ASES score obtained was 48. The number of days spent in the hospital ranged between 12 days and 40 days (due to associated injuries and complications).

### 3.1 Radiographs and clinical photos of results



### 4. Discussion

This study was done to determine the efficacy of DCP in the treatment of fractures of the shaft of humerus. 20 cases of fracture of shaft of humerus were treated with open reduction and internal fixation using DCP. We evaluated our results and compared them with those obtained by various other studies utilizing different modalities of treatment.

Fractures of the shaft of humerus are commonly seen in young adults. The average age in our series was 33.4 years with the

maximum number of patients in 2nd and 3rd decades and this finding were similar to the observation of McCormack RG *et al* (2000) [12] avg age 49, Gongol T and MracekD [13] (2002) avg age 47. There was a male preponderance in the present study with 18 (90%) of the patients being males. This finding different to the observation of most of other studies, Strong GT *et al* [7] (1998) 44.6% males, Tingstade EM *et al* (2000) 53.6% males. Both sides were equally affected in injury in present study which is similar to Heimd *et al* (1993) 55.1%, Strong GT *et al* (1998) 55.8%.

Majority of the fractures were sustained due to Road traffic accidents i.e. 16 (80%) patients in present study which is similar to Dayez J (1999) and Tingstade EM *et al* (2000). Majority of the fractures were in the middle third i.e 16 (80%) patients which is almost similar to Strong Gt *et al.* [7] (1998) 64.2%. Most of the fractures in our series were transverse or short oblique, 14 (70%) patients which were similar to Strong Gt *et al.* [7] (1998) 63.3% and Tingstade EM *et al.* [14] (2000) 64%.

19(95%) of our 20 fractures united with 1(5%) fracture going for non-union. Result in our series is comparable to Gongol T *et al.* [13] (2002) non-union 3.1% and Tingstade EM *et al.* [14] (2000) 6%. Out of 20 patients in our series, one patients (5%) had poor mobility and other 19(95%) had good mobility of elbow and shoulder joints, this results were similar to Gongol T *et al.* [13] (2002) 97% and McCormack RG *et al* (2000) 100%.

The average ASES score obtained was 48 in our series. This is comparable to the ASES score of 48 obtained by McCormack RG *et al.* [12] when treating humeral shaft fractures with DCP and a score of 47 when treating with interlocking intramedullary nail fixation. We had 19(95%) patients with excellent or good results out of 20 patients in our series. It is comparable to Gongol T *et al.* [13] (2002) 93.8% and McCormack RG *et al.* [12] (2000) 95.7%.

### 5. Conclusion

Fractures of shaft of humerus are common in young male adults. This is probably due to road traffic accidents being the commonest mode of injury in our series. Majority of the fractures were transverse or short oblique in the middle third and most of them were closed injuries. Injury to the radial nerve is rare, 5% in our series. Yet, it is necessary to look for neurovascular injury and rule out the same. Early post-operative mobilization following rigid fixation of the fracture of humerus, "with DCP lowers the incidence of stiffness and Sudecks dystrophy. Conservative management has provided good union rates but has been plagued with the complications of stiffness and Sudecks dystrophy. Prolonged immobilization goes against the AO principle of obtaining early, active, pain free mobilization. Internal fixation of the humerus with DCP avoids these complications and achieves higher union rates as compared to conservative management.

Dynamic compression plating of the humerus produces comparable better results.

### 6. References

1. Schemitsch EH, Bhandari M. Fractures of the diaphyseal humerus. In: Browner BD Jupiter JB, Levine AM, Trafton PG, editors. Skeletal trauma, 3rd ed. Toronto. WB Saunders. 2001, 1481-1511.
2. Brinker MR, O'Connor DP. The incidence of fractures and dislocations referred for orthopaedic services in a capitated population. J Bone Joint Surg Am. 2004; 86:290-297.
3. Gregory PR. Fractures of the humeral shaft. In: Bucholz RW, Heckman JD editors. Rock wood and Green's fractures in adults, 5th ed. Philadelphia: Lippincott

- Williams & Wilkins. 2001, 973-996.
4. Fears RL, Gleis GE, Seligson D. Diagnosis and treatment of complications: Fractures of the diaphyseal humerus. In: Browner BD, Jupiter JB, Levine AM, Trafton PG, editors. *Skeletal Trauma*, 2nd ed. Toronto: WB Saunders. 1998, 567-578.
  5. Sarmiento A, Zagorski JB, Zych G. Functional bracing for the treatment of fractures of the humeral diaphysis. *J Bone Joint Surg Am*. 2000; 82:478-486.
  6. Standard JP, Harris HW, McGwin G Jr. Intramedullary nailing of humeral shaft fractures with a locking, flexible nail. *J Bone Joint Surg Am*. 2003; 85:2103-2110
  7. Tytherleigh- Strong G, Walls N, McQueen MM. The epidemiology of humeral shaft fractures. *J Bone Joint Surg Br*. 1998; 80:249-253.
  8. Mckee MD. Fractures of the shaft of the humerus. In: Bucholz RW, Heckman JD, Court-Brown CM, Koval KJ, Tometta III P, Wirth MA. editors. *Rockwood and Green's Fracture in adults*. 6th ed. Philadelphia: Lippincott Williams & Wilkins. 2006, JU7-1160.
  9. Kocaoglu M, Eralp L, Tomak Y. Treatment of humeral shaft non- unions by the Ilizarov Method. *Int Orthop*. 2001; 25(6):396-400.
  10. oppenfeld HS, deBoer P. *Surgical exposures in orthopaedics - the anatomic approach*. 3rd ed. Philadelphia: Lippincott Williams and Wilkins, 1994, 67-104.
  11. Schatzker J. Screws and plates and their application. In: Muller ME, Allgower M, Schneider R, Willenegger H editors. *Manual of Internal Fixation*. 3rd ed. Berlin: Springer Verlag. 1991, 179.
  12. McCormack RG, Brien D, Buckley RE, Mckee MD, Powell J. Fixation of fractures of the shaft of the humerus by dynamic compression plate or intramedullary nail. *J Bone Joint Surg Br*. 2000; 82(3):336-339.
  13. Gongol T, Mracek D. Functional therapy of diaphyseal fractures of the humeral bone. *Acta Chir Orthop Traumatol Cech*. 2002; 69(4):248-253.
  14. Tingstad EM, Wo linsky PR, Shyr Y, Johnson KD. Effect of immediate weight bearing on plated fractures of the humeral shaft. *J trauma*. 2001; 49(2):278-280.