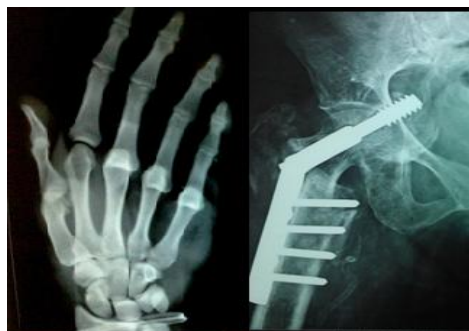

International Journal of Orthopaedics Sciences

ISSN: 2395-1958
IJOS 2016; 2(4): 86-90
© 2016 IJOS
www.orthopaper.com
Received: 13-08-2016
Accepted: 14-09-2016

Dr. Manish Raj
Assistant Professor, Department
of Orthopaedics, UPUMS, Saifai,
Uttar Pradesh, India.

Dr. Jasveer Singh
Assistant Professor, Department
of Orthopaedics, UPUMS, Saifai,
Uttar Pradesh, India.

Dr. John Mukhopadhy
HMRI Patna, Bihar, India.

Dr. S P S Gill
Professor, Department of
Orthopaedics, UPUMS, Saifai,
Uttar Pradesh, India.

Dr. Sunil Kumar Sheopaltan
Professor, Department of
Orthopaedics, UPUMS, Saifai,
Uttar Pradesh, India.

Dr. Harish Kumar
Assistant Professor, Department
of Orthopaedics, UPUMS, Saifai,
Uttar Pradesh, India.

Dr. Ajay Kumar Rajput
Lecturer, Department of
Orthopaedics, UPUMS, Saifa,
Uttar Pradesh, India.

Correspondence
Dr. Manish Raj
Assistant Professor, Department
of Orthopaedics, UPUMS, Saifai,
Uttar Pradesh, India.

Evaluation of single stage protocol using Locked plate as primary fixation in treatment of infected non-union of long bones

Dr. Manish Raj, Dr. Jasveer Singh, Dr. John Mukhopadhy, Dr. S P S Gill, Dr. Sunil Kumar Sheopaltan, Dr. Harish Kumar and Dr. Ajay Kumar Rajput

DOI: <http://dx.doi.org/10.22271/ortho.2016.v2.i4b.14>

Abstract

Background: Infected non-union of long bones is one of the most challenging problems in clinical practice. In the treatment of infected non-union it is often difficult to achieve union and eradication of infection. The treatment strategy of infected non-union generally involves two stages: control of infection by local radical debridement of dead tissue and external fixator application followed by definitive treatment of bone stabilization and bone-grafting. Treatment with different methods of external fixators like Ilizarov, Orthofix had been gold standard in the past decade. However due to complications like prolonged fixation time, poor patient compliance, pin loosening and refracture after removal, there is need for alternative method of primary bone stabilization in infected non-union of long bones. The present study evaluates the results of single stage protocol of aggressive local radical debridement and internal fixation with locking compression plate as a primary means of stabilization in the treatment of infected non-union.

Materials and Methods: Twenty one cases of infected non-union (5 femurs, 15 humerus, 1 tibia) were included in present study. The procedure included single stage protocol of exploration of the nonunion with aggressive local debridement, implant removal and reaming of intramedullary canal, antibiotic spacers and beads and Locking compression plate (LCP) as primary means of stabilization. Based on requirement and judgment by treating surgeon, revision debridement and removal of antibiotic bead with bone grafting was done as planned procedure. The evaluation of results included the union of the bone (both clinically and radiological), eradication of infection, complication rate, number of reintervention surgery.

Result: The mean follow-up was 14 months (range 6 months to 5 years). We had achieved infection free union in 19 cases out of total 21 cases. In 1 patient with previous infection had recurrence for which revision surgery with implant removal and refixation with L.C.P and bone grafting done? In another patient additional L.C.P plate with bone graft is applied. Infection free union is achieved in both cases. The functional outcome was satisfactory in most cases. The time to bone healing averaged 4.2 months (range 3 to 7 months)

Conclusion: The proposed technique is effective in treating infected nonunion with resolution of infection and bone union. The inclusion of locking compression plate as internal splint improves stability of fixation, and along with proper and adequate local radical debridement, can be used as alternative method of fixation for obtaining fracture union with a good functional result.

Keywords: Inter-trochanteric fractures, Sub-trochanteric fractures, Clinical profile

Introduction

The aim of treatment in infected non-union is to obtain stable bony union, eradication of infection with maximal functional use of extremity (5). The treatment strategy of infected non-union traditionally involves two stages: control of infection by local radical debridement of dead tissue and external fixator application followed by definitive treatment of bone stabilization and bone-grafting (2, 7, 8, 24, 30, 32). Treatment with different methods of external fixators like Ilizarov, Orthofix had been gold standard in the past decade.

However due to complications like prolonged fixation time, poor patient compliance, pin loosening and refracture after removal, there is need for alternative method of primary bone stabilization in infected non-union of long bones. Helfet *et al.* (17) used a protocol that includes

stable internal fixation rather than prolonged treatment with an external fixator that is only relatively stable, and is problematic for the soft tissues and many times results in pin track Complications.

The main risk of this technique is the possibility of spreading the infection. Conventional plating presents some problems, such as damage to periosteal blood flow and creation of osteoporotic areas beneath the plate; these disadvantages have been partially resolved by the development of LCP plates. The present study evaluates the results of aggressive local radical debridement and internal fixation with locking compression plate as a primary means of stabilization in the treatment of infected non-union.

Material and Methods

Twenty one cases of infected non-union (5 femur, 15 humerus, 1 tibia) were included in present study. The procedure included single stage protocol of exploration of the nonunion with aggressive local debridement, implant removal and reaming of intramedullary canal, antibiotic spacers and beads and locking compression plate (LCP) as primary means of stabilization. Debridement include accurate and complete excision of the sinus tract and all infected avascular tissues, i.e., avascular soft tissue bed (including skin, subcutaneous tissue, fascia, muscle, and scar tissue between bone ends) and avascular bone bed (avascular bone bed can result in persistent infection with drainage). Moreover, proximal and distal medullary canals are curetted and reamed to remove all necrotic debris. Intra operative culture specimen are taken during debridement. After debridement fracture site was stabilized with LCP plate. Repeated debridement, performed every 3–5 days, is often done as to rule out any recurrence of

infection. The quality of the surgical debridement is the most critical factor for successful management of chronic orthopedic infection. Antibiotic therapy during treatment is established according to the results of susceptibility studies of the intraoperative cultures. After debridement, treatment with closed suction-irrigation may sometimes be indicated (particularly in large cavities where an important bleeding can be expected). If there is any evidence of active infection, i.e. gross purulence or actively draining sinus tracts, antibiotic beads made with tobramycin and vancomycin are placed deep in the wound. In the absence of active infection, then bone graft, either iliac crest or demineralised bone matrix, is applied to the nonunion site.

Result

Using this single stage protocol we have treated 21 cases of infected non-union. The intra-operative specimen reported positive culture for all 21 cases, out of which in 14 samples are positive for staphylococcus aureus, 5 samples were positive for Pseudomonas aeruginosa and 2 sample was positive for Klebsiella. Except 1 case patients achieved infection control with no sign of infection or active discharge. The mean follow-up was 14 months (range 6 months to 5 years). Bone union was achieved in 19 cases within a mean period of 4.2 months (3 to 7 months). Out of 2 cases, in which non-union is found, plate is removed and wound debridement and refixation with another L.C.P plate with bone grafting done in one case, while in other case additional L.C.P plate is applied and bone grafting done. Union is achieved in both cases. The functional outcome was satisfactory in most cases. The time to bone healing averaged 4.2 months (range 3 to 7 months).

Table 1: All patient Data

Case	Sex	Bone involved	Fracture Location	S.A	D.O.I	Previous Implant	Refixation with	Bone grafting	Antibiotic bead	Infection Control	Fracture union	R.O.M
1	M	Femur	Distal 1/3rd	Rt	7	D.C.P	L.C.P	No	No	yes	United	0-95
2	F	Femur	Middle 1/3rd	Lt	2	I.M nail	L.C.P	Yes	No	yes	United	0-110
3	M	Femur	Middle 1/3rd	Lt	3	D.C.P	L.C.P	No	No	Yes	United	0-90
4	M	Humerus	Distal 1/3rd	Lt	12	D.C.P	L.C.P	No	Yes	yes	United	0-95
5	M	Humerus	Distal 1/3rd	Lt	36	2 Square nail	L.C.P	Yes	No	Yes	United	0-120
6	M	Humerus	T-Y#	Lt	6	JESS	2 L.C.P	Yes	Yes	Yes	united	0-110
7	F	Humerus	Middle 1/3rd	Lt	10	L.C.P	L.C.P	Yes	No	Yes	united	0-95
8	M	Humerus	Proximal 1/3rd	Rt	12	PHILOS plate	PHILOS Plate	No	No	Yes	United	0-70
9	M	Humerus	Proximal 1/3rd	Lt	2	D.C.P	PHILOS Plate	Yes	Yes	Yes	United	0-130
10	F	Humerus	Middle 1/3rd	Rt	6	D.C.P	2 L.C.P	Yes	Yes	Yes	United	0-95
11	M	Humerus	Distal 1/3rd	Rt	4	Tubular Plate	2 L.C.P	No	No	Yes	United	0-110
12	F	Humerus	Distal 1/3rd	Lt	3	2 plate	L.C.P	Yes	Yes	Yes	United	0-80
13	F	Humerus	Middle 1/3rd	Rt	12	D.C.P	L.C.P	Yes	Yes	Yes	United	0-95
14	M	Femur	Distal 1/3rd	Rt	36	D.C.P	L.C.P	No	Yes	Yes	United	0-95
15	M	Tibia	Middle 1/3rd	Lt	2	D.C.P	L.C.P	No	Yes	Yes	United	0-90
16	F	Humerus	Distal 1/3rd	Lt	8	No	3 L.C.P	Yes	Yes	Yes	United	0-120
17	M	humerus, ulna	Distal humerus, mid shaft ulna	Lt	2	JESS, Square nail	L.C.P	Yes	No	Yes	United	0-110
18	M	Femur	Proximal 1/3rd	Rt		L.C.P plate	L.C.P	Yes	No	Yes	United	0-95
19	F	Humerus	Middle 1/3rd	Rt	2	I.M nail	L.C.P	No	Yes	Yes	United	0-110
20	M	Humerus	Middle 1/3rd	Lt	26	Square nail	L.C.P	No	No	No	Not united, R.S done	0-95
21	M	Humerus	Distal 1/3rd	Lt	3	D.C.P	L.C.P	Yes	Yes	Yes	Not united, R.S done	0-100

Abbreviations : S.A - Side Affected, D.O.I - duration of injury in months, W.D - wound debridement, L.C.P - Locking compression plate, D.C.P - dynamic compression plate, R.O.M - Range of motion in degree, I.M nail - Intra-medullary nail, R.S - Revision Surgery

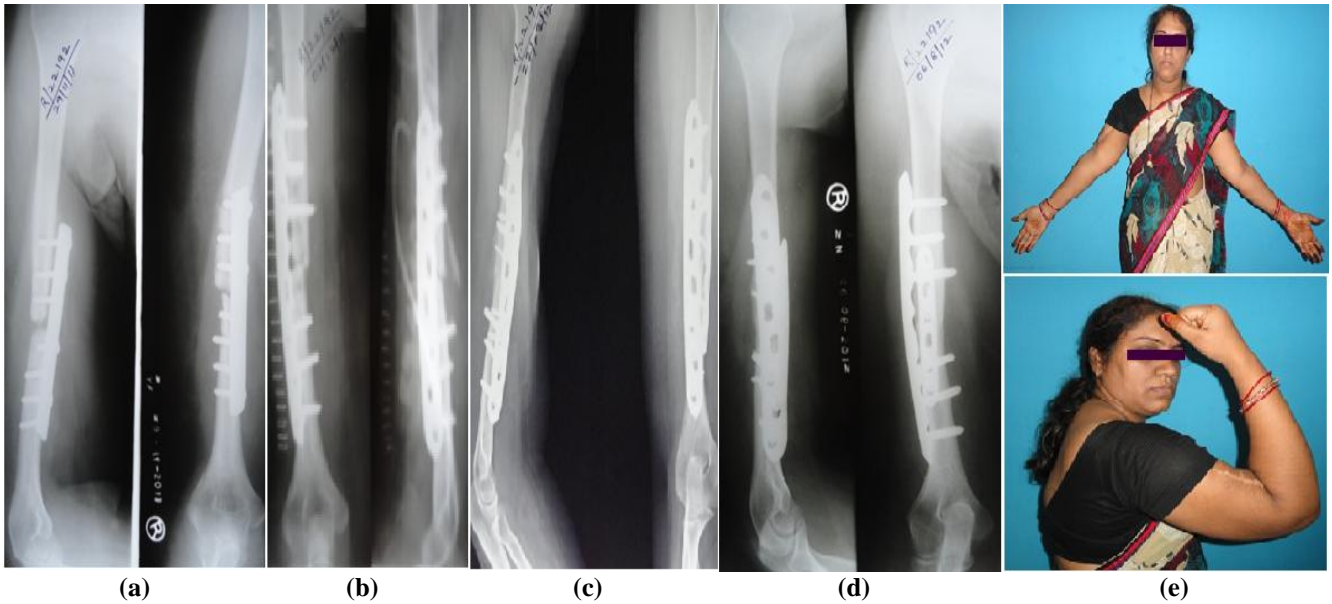


Fig 1

a) A.P and Lateral view of 6 month old infected non-union of shaft of humerus with implant in situ b) Post-operative X-ray following revision ORIF c) 4 month post-operative

X-ray showing sign of bone union d) 9 month post operative X-ray showing fracture is united e) Functional range of movement attained after fracture is united.

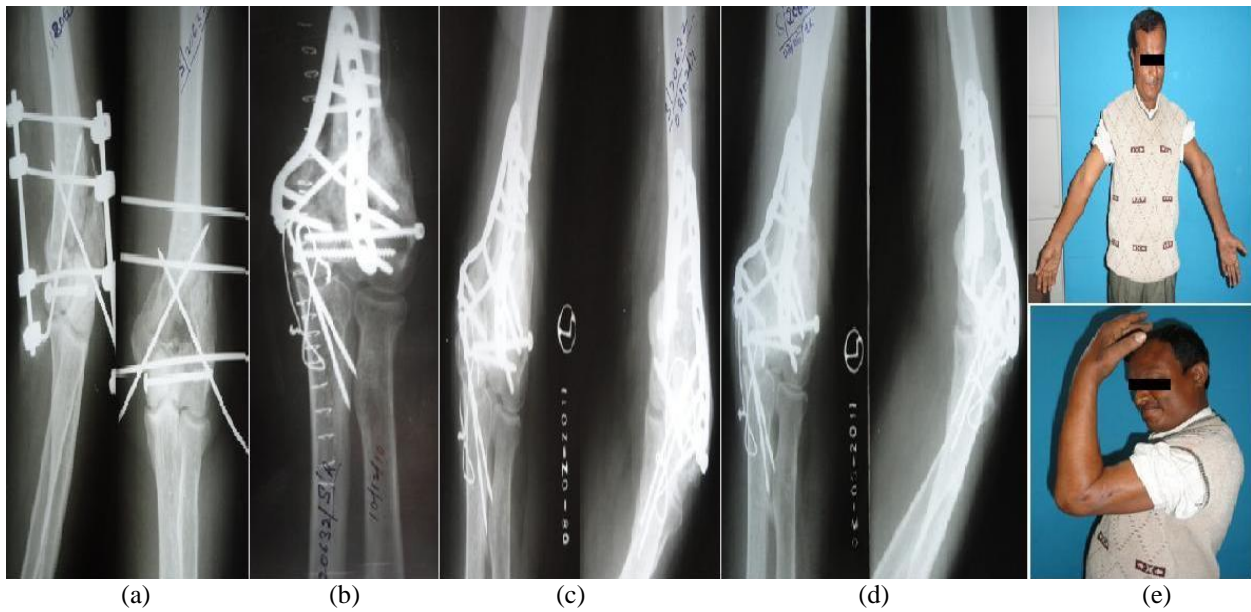


Fig 1

a) 6 month old fracture distal humerus treated with jess presents with non-union and infection b) Revision ORIF done with 2 L.C.P plate done c) 2 month post-operative X-ray showing sign of union c) 6 month post-operative X-ray shows fracture is united d) Functional range of movement attained after fracture is united.

and refixation with L.C.P and bone grafting done? In another patient additional L.C.P plate with bone graft is applied. Infection free union is achieved in both cases

Conventional treatment of infected non-union combines, in several operative stages, debridement, stabilization, and reconstruction. Debridement associated with antibiotic therapy, attempts to sterilize the non-union site. Stabilization aims to allow consolidation and to fight infection more effectively. Skin and bone grafts can be used for reconstruction. Stability can be achieved by several means. If we look through literature, although many treatment modalities have been proposed (1, 3, 4, 11, 13, 16, 18, 21, 27, 28). None has been accepted as the gold standard. Nonoperative techniques such as skeletal traction or cast immobilization cannot provide acceptable stability and should only be used as a temporary measure in selected cases. The

Discussion

Using this single stage protocol of treating infected non-union that combines aggressive surgical debridement with implant removal, local and systemic antibiotics, revision internal fixation with L.C.P and bone grafting and antibiotic bead application, we had achieved infection free union in 19 cases out of total 21cases. In 1 patient with previous infection had recurrence for which revision surgery with implant removal

advantages of using axial external fixation techniques are: insertion of the bone fixation elements far from the infected bone, easy care of the infected wound, and the possibility of further procedures such as bone and skin grafts without injuring the surrounding tissues (14, 19). Axial devices, therefore, have many important limitations compared to circular external devices (less stability, little versatility in axial or torsion deviations, and impossibility of immediate weight bearing). In brief, they do not allow a “dynamic” treatment of the infected nonunion. Ilizarov ring fixator (6, 9, 16, 20, 26, 29) and bone transport has become the solution for every kind of non-union, but is easier said than done, as this needs knowledge of instrumentation (10), techniques of application and expertise. It has its own complications and disadvantage like pain, pin tract infection, joint stiffness, vascular and neurological injury as described by Paley as problems, obstacles and complications (22, 23). Persons working in periphery may not be able to use this apparatus and it is costlier also in our set up and overall assembly is quite cumbersome. Antibiotic impregnated intramedullary nailing has been performed with discrete success rates by many authors (1, 15, 25, 28, 30). This technique has the risk of spreading infection to the entire medullary canal of the long bone, too. Plating, performed during debridement and irrigation or later (during the second or third debridement) in patients in whom local signs of infection are present, is employed in combination with bone grafting and is considered by some authors a good method of treatment, with high success rates (5, 17). Helfet *et al.* (17) achieved infection free union in all 13 patients of infected femoral nonunion with a single-staged protocol utilizing internal fixation. Internal fixation with plating is more comfortable and less cumbersome than external fixators that require daily pin care and often times become infected.

The main limitation of our series is small number of patients, lack of control group, and absence of functional outcome scores. However, using our single stage protocol we had achieved infection free union in 90% cases of infected non-union treated by us and ultimately all patients had union with the use of internal fixation and majority of our patients had attained full range of motion.

Conclusion

The proposed technique is effective in treating infected nonunion with resolution of infection and bone union. The inclusion of locking compression plate as internal splint improves stability of fixation, and along with proper and adequate local radical debridement, can be used as alternative method of fixation for obtaining fracture union with a good functional result.

Reference

- Babhulkar S, Pande K, Babhulkar S. Nonunions of the diaphysis of long bones. *Clin Orthop Relat Res.* 2005; 431:50-6.
- Beals RK, Bryant RE. The treatment of chronic open osteomyelitis of the tibia in adults. *Clin Orthop Relat Res* 2005; 433:212-7.
- Boyd HB. The treatment of difficult and unusual non-unions. *J Bone Joint Surg.* 1943; 25:535-52.
- Boyd HB, Anderson DL, Johnson DS. Changing concepts in the treatment of nonunion. *Clin Orthop.* 1965; 34:37-54.
- Brinker MR. Non-union. Evaluation and Treatment. In: *Skeletal Trauma. Basic science, management and reconstruction.* 3rd ed. Saunders. 2003, 507-604.
- Cattaneo R, Catagni M, Johnson EE. The treatment of infected non unions and segmental defects of the tibia by the methods of Ilizarov. *Clin Orthop Rel Res.* 1992; 280:143-52.
- Chen CE, Ko JY, Wang JW, Wang CJ. Infection after intramedullary nailing of the femur. *J Trauma* 2002; 55:338-44.
- Court- Brown CM. Fractures of the tibia and fibula. In: Bucholz RW, Heckman JD, Court-Brown CM, editors. *Rockwood and Green's fractures in adults.* 6th ed. Lippincott Williams and Wilkins, 2006, 2080-146.
- Dendinos GK, Kontos S, Lyritis E. Use of Ilizarov technique for treatment of non-union of the tibia associated with infection. *J Bone Joint Surg Am.* 1995; 77:835-46.
- Fleming B, Paley D, Kristiansen T, Pope M. A biomechanical analysis of Ilizarov external fixation. *Clin Orthop.* 1989; 241:95.
- Helfet DL, Jupiter JB, Gasser S. Indirect reduction and tension band plating of tibial nonunion with deformity. *J Bone Joint Surg Am.* 1992; 74:1286-1297.
- Jain AK, Sinha S. Infected nonunion of the long bones. *Clin Orthop Relat Res.* 2005; 431:57-65.
- Lifeso RM, Al-Saati F. The treatment of infected and uninfected nonunion. *J Bone Joint Surg Br.* 1984; 66:573-9.
- Lortat-Jacob A. Principes de traitement chirurgical de l'infection osseuse. Infection sur os non solide. *Encycl Méd Chir, Techn Chir-Orthop Traumatol* 44-082 Elsevier, Paris, 1977.
- Madanagopal SG, Seligson D, Roberts CS. The antibiotic cement nail for infection after tibial nailing. *Orthopaedics.* 2004; 27:709-12.
- Maini L, Chadha M, Vishwanath J, Kapoor S, Mehtani A, Dhaon BK. The Ilizarov method in infected non-union of fractures. *Injury.* 2000; 31:509-17.
- Mark L, Prasarn, Jaimo Ahn, Timothy Achor, Paul Matuszewski, Dean G. *et al.* Management of infected femoral nonunions with a single-staged protocol utilizing internal fixation. *Injury, Int. J Care Injured.* 2009; 40:1220-1225.
- Marsh DR, Shah S, Elliot J, Kurdy N. The Ilizarov method in nonunion, malunion and infection of fractures. *J Bone Joint Surg Br.* 1997; 79b:273-9.
- Marsh JL, Nepola JV, Meffert R. Dynamic external fixation for stabilization of nonunions. *Clin Orthop Relat Res* 278:200-208.
- Mckee MD, Yoo DJ, Zdero R, Dupere M, Wild L, Schemitsch EH *et al.* Combined single stage osseous and soft tissue reconstruction of the tibia with the Ilizarov method and tissue transfer. *J Orthop Trauma.* 2008; 22:183-9.
- Meyer S, Weiland AJ, Willenegger H. The treatment of infected non-union of fractures of long bones. Study of sixty-four cases with a five to twenty-one-year follow-up. *J Bone Joint Surg Am.* 1975; 57:836-42.
- Paley D. Problems, Obstacles and complications of limb lengthening by Ilizarov technique. *Clin orthop.* 1990; 250:81-104.
- Paley D, Catagni MA, Argnani F, Villa A, Benedetti GB, Cattaneo R. Ilizarov treatment of tibial nonunions with bone loss. *Clin Orthop Relat Res.* 1989; 241:146-165.
- Patzakis MJ, Zalavras CG. Chronic posttraumatic osteomyelitis and infected non-union of the tibia: Current

- management concepts. *J Am Acad Orthop Surg* 2005; 13:417-27.
25. Qiang Z, Jun PZ, Jie XJ, Hang L, Bing LJ, Cai LF. Use of antibiotic cement rod to treat intramedullary infection after nailing; Preliminary study in 19 patients. *Arch Orthop Trauma Surg*. 2007; 127:945-51.
 26. Song HR, ChoSH, Koo KH, Jeong ST, Park YJ, KoJH. Tibial bone defects treated by internal bone transport using the Ilizarov method. *Int Orthop*. 1998; 22:293-7.
 27. Struijs PAA, Poolman RW, Bhandari M. Infected nonunion of the long bones. *J Orthop Trauma*. 2007; 21:507-11.
 28. Thonse R, Conway J. Antibiotic cement coated interlocking nail for the treatment of infected non unions and segmental bone defects. *J Orthop Trauma*. 2007; 21:258-68.
 29. Toh CL, Jupiter JB. The infected non-union of the tibia. *Clin Orthop Relat Res*. 1995; 315:176-91.
 30. Ueng S, Wei FC, Shih CH. Management of femoral diaphyseal infected nonunion with antibiotic beads local therapy, external skeletal fixation, and staged bonegrafting. *J Trauma*. 1999; 46:97-103.
 31. Ueng SW, Chuang DC, Cheng SL, Shih CH. Management of large infected tibial defects with radical debridement and staged double-rib composite free transfer. *J Trauma*. 1996; 40:345-9.
 32. Wu CC, Shih CH. Distal tibial non-union treated by intramedullary reaming with external immobilization. *J Orthop Trauma*. 1996; 10:45-9.