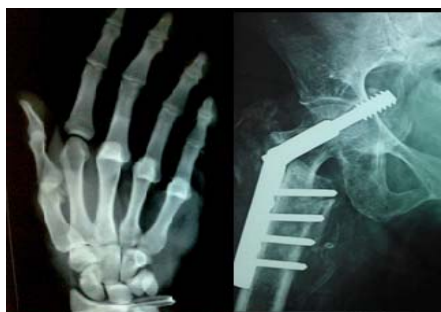



International Journal of Orthopaedics Sciences

ISSN: 2395-1958
IJOS 2016; 2(4): 17-21
© 2016 IJOS
www.orthopaper.com
Received: 04-08-2016
Accepted: 05-09-2016

Dr. Sarabjeet Kohli
MGM, Medical College,
Kamothe, Panvel, Navi Mumbai
India.

Dr. Shaival Chauhan
MGM, Medical College,
Kamothe, Panvel, Navi Mumbai
India.

Dr. Nilesh Vishwakarma
MGM, Medical College,
Kamothe, Panvel, Navi Mumbai
India.

Dr. Kuldip Salgotra
MGM, Medical College,
Kamothe, Panvel, Navi Mumbai
India.

Correspondence
Dr. Shaival Chauhan
MGM, Medical College,
Kamothe, Panvel, Navi Mumbai
India.

Functional and radiological outcomes of distal femur intra articular fractures treated with locking compression plate

**Dr. Sarabjeet Kohli, Dr. Shaival Chauhan, Dr. Nilesh Vishwakarma and
Dr. Kuldip Salgotra**

DOI: <http://dx.doi.org/10.22271/ortho.2016.v2.i4.004>

Abstract

Introduction: The treatment of distal intra articular femur fractures has been a controversial topic and it has recently evolved towards indirect reduction and minimally invasive techniques. The goal is to strike a balance between the mechanical stability of the fragments and the biological viability. For intraarticular femur fractures, periarticular locking plates have been rapidly adopted as an alternative to intramedullary nails, blade plates, and nonlocking condylar screws. However, there is a paucity of data to assess the results when these implants are used in the presence of intra articular involvement and comminution.

The aim of this study is to assess the functional and radiological outcomes following fixation of intra articular distal femur fractures with locking compression plate (LCP).

Material and methods: The study period, dated from June 2013 to Dec 2015, included a total of 27 cases of distal femur fracture (AO/OTA classification type C2 and C3) treated with locking compression plate. The patients' age ranged from 20 to 77 years and all patients were followed up according to post-operative follow up protocol. The minimum follow up period was 1 year and patients were assessed for functional outcome and radiological signs of fracture healing every month in the outpatient department.

Results: Of the 27 patients treated with distal LCP, 24 Patients (90%) showed radiological union within 20 weeks. 3 patients had delayed union and implant failure. Average time for union was 16.1 weeks. (excluding the cases of implant failure). Average flexion in this study was 113 degree with more than 20 patients having knee range of motion more than 90 degrees. Out of these 20 patients, 10 had a range more than 110 degrees. The functional outcome was measured using Neer's scoring system, with 59% of the study group having excellent results. The complications encountered during the study period involved one superficial skin infection treated by debridement, shortening of 0.5 – 2 cms in three patients which was associated with the extensive comminution at the fracture site. There were two patients who at the end of year of follow up showed varus angulation of 7 degrees. 3 patients had an implant failure treated with bone grafting and re application of LCP. 1 patient developed fat embolism.

The results showed a better functional and radiological outcomes when compared to other published studies done on these intra articular fractures using other implant options namely, distal femoral nail, dynamic condylar screw and less invasive stabilisation system (LISS)

Conclusions: The locking compression plates with option of locked screws has provided the means to increase the rigidity of fixation in intraarticular distal femoral fractures. However this is a technically demanding procedure considering the severity of these injuries. We conclude that this method of fixation is especially suited for fractures where achieving congruency of the articular surface would be difficult with less invasive modalities like retrograde nailing and LISS.

Keywords: Intra articular distal femur, locking plate

1. Introduction

Distal fractures of the femur especially comminuted, intra-articular distal femoral fractures (Orthopaedic Trauma Association [OTA] classification 1 33-C3) remain some of the most challenging fractures facing orthopaedic surgeons. Distal femoral fractures are much less common than hip fractures and account for about 4-7% of all femoral fractures [1, 2]. The incidence of distal femur fractures has increased significantly during recent decades, and the incidence is highest in women older than 70 years and in adolescent boys and men 15 to 24 years old [3].

The options for operative treatment are traditional plating techniques that require compression of the implant to the femoral shaft (blade plate, Dynamic Condylar Screw, non-locking

condylar buttress plate), antegrade nailing fixation, retrograde nailing, sub muscular locked internal fixation and external fixation [4]. Coronal plane fractures and extensive distal comminution generally preclude the use of traditional fixed-angle devices or retrograde nails. Fixation of these fractures with a lateral plate alone has historically been associated with nonunion and/or malunion with varus collapse. Prior to the advent of locked plates, this problem may have been addressed with dual medial and lateral fixation, causing additional surgical insult to the local fracture biology [2, 5, 6]. By extensive soft tissue stripping on both sides of the femur.

The significant forces applied to this area, even during restricted patient activities, require a strong implant; however, fixation is difficult because of the wide canal, thin cortex, and relatively poor bone quality of the distal femur. Most surgical failures are caused by inadequate fixation of fracture fragments. No implant can stabilize every fracture type; however, for best results, the device chosen must provide fixation rigid enough for early motion.

Most commonly used implant for the fixation of distal femur fractures are fixed angle devices, usually in the form of Dynamic Condylar Screw (DCS) system, which is a supracondylar plate combined with a lag screw. This two piece device is more forgiving to soft tissues and allows correction in the sagittal plane after the lag screw is inserted [7, 8].

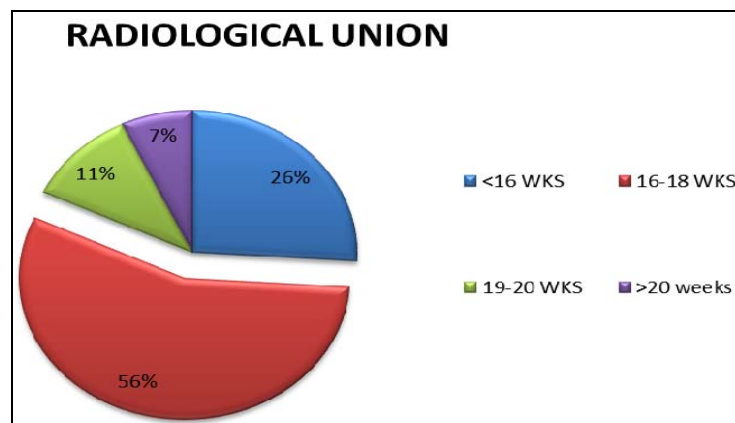
The LCP is a single beam construct where the strength of its fixation is equal to the sum of all screw-bone interfaces rather than a single screw's axial stiffness or pullout resistance as seen in unlocked plates. Its unique biomechanical function is based on splinting rather than compression resulting in flexible stabilization, avoidance of stress shielding and induction of callus formation [9]. Internal fixation with locking plates creates a toggle free, fixed angle construct [10]. The introduction of plates with the option of locked screws has provided the means to increase the rigidity of fixation in the presence of periarticular or juxta-articular fractures with a small epiphyseal segment [10]. The implant offers multiple points of fixed-angle contact between the plate and screws in the distal part of femur, theoretically reducing the tendency for varus collapse that is seen with traditional lateral plates [10].

2. Methodology

Our study was both retrospective and prospective which consisted of 27 supracondylar femur fractures, AO type C2 and C3, fractures treated with LCP in our institute from June 2013 to Dec 2015. All Skeletally mature patients over 18 years of age with distal femur fractures were selected for the study. The sources were collected from the proforma and the medical records. The minimum follow up period was 1 year ranging from 12 months to 18 months and patients were assessed for functional capacity and radiological fracture healing capacity every month in outpatient department. Patients with pathologic fractures, advanced osteoarthritis, Grade IIIC Gustilo and Anderson open fractures and infected knee\distal femur fractures were excluded from the study. Antibiotics were given as per the hospital protocol. Splints were removed and mobilization of the limb started on the 3rd or 4th day postoperatively. Mobilization with Non weight bearing was started from the first post-operative week till 6-8 weeks depending on the fracture pattern and then partial weight bearing after confirmation of beginning of healing process till fracture union. All patients were followed up at 4th 10th 14th 18th week and 6 weeks thereafter till fracture union is noted. Subsequently at 6th month 9th month and 1 year. During follow up patients were assessed clinically, radiologically and functionally by NEERS criteria.

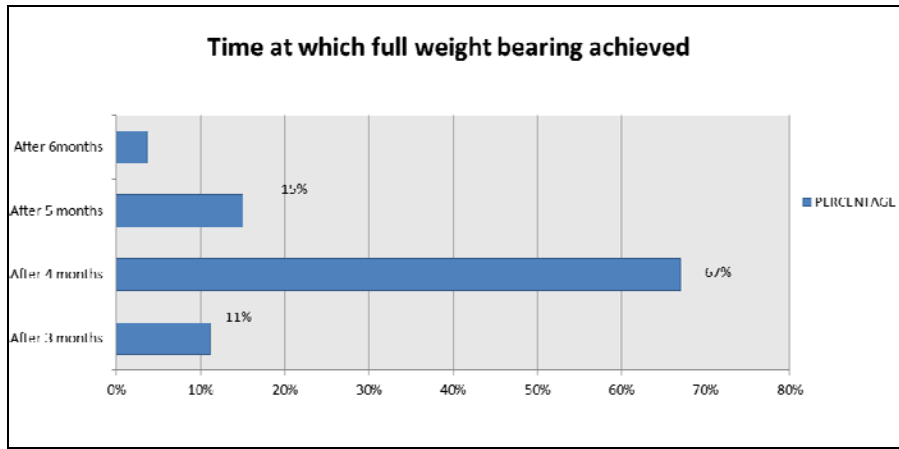
3. Results

Twenty three patients were males and four were females. The patients' age ranged from 20 to 77 years with a mean age of 40.7 years. Fifteen fractures involved the right side and twelve involved the left side. The causes of fractures were motor vehicle accident in twenty four patients and domestic fall in remaining three. According to Muller's classification of distal femur twenty one cases were Muller's type C2; and six were Muller's type C3. Average blood loss was 448 ml. of 27 patients, 24 Patients (90%) showed radiological union within 20 weeks. 2 patients had delayed union and implant failure. Average time for union was 16.1 weeks. (Excluding the cases of implant failure).

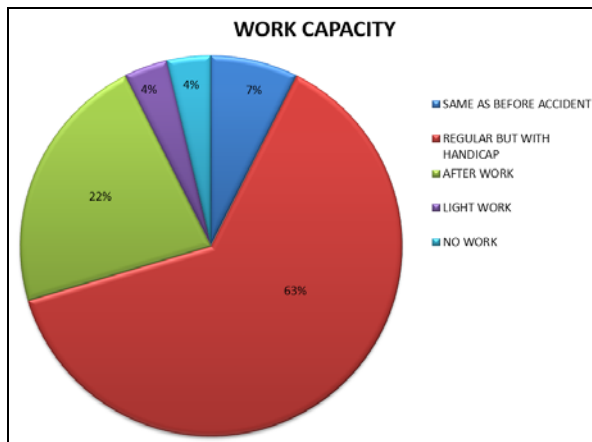
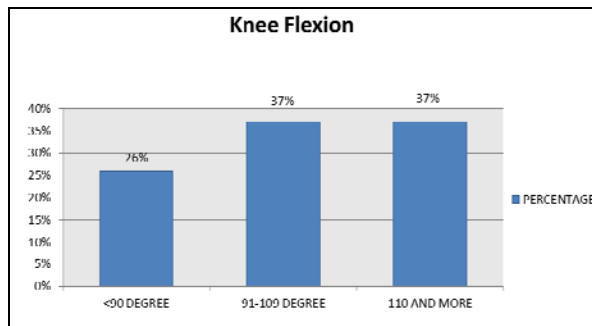


One patient (who was a haemophiliac) had superficial infection, leading to skin necrosis and gaping. He underwent wound debridement for the same, following which the infection subsided. Around 0.5-2 cm shortening was seen in three patients. All the 3 patients had extensive metaphyseal comminution on the pre-operative x ray films. Two patients had a radiological varus malalignment of 7 degrees none of the

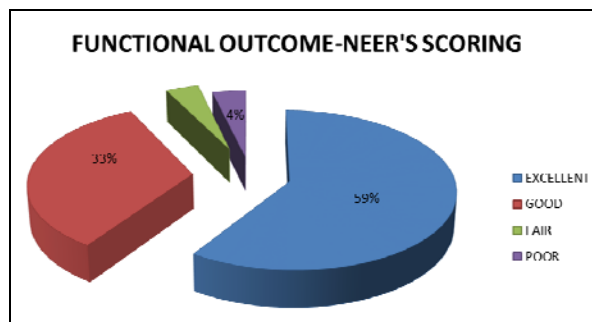
cases had valgus malalignment. One patient had fat embolism on the 2nd post op day. The patient also had ipsilateral subtrochanteric femur fracture which was fixed with a proximal femoral nail in the same sitting. The symptoms persisted for 1 week during which he was kept in the ICU and given supplemental oxygen. He had complete recovery following the same.



Average flexion in this study was 113 degree with more than 20 patients having knee range of motion more than 90 degrees. Out of these 20 patients, 10 had a range more than 110 degrees.



Functional outcome was assessed at the end of one year using Neer's scoring system. It was found to be excellent in 19 (59%), good in 9 (33.33%), fair in 1 (3.7%) and or in 1(3.7%)



The treatment of distal intra-articular femur fractures has been a controversial topic and it has recently evolved towards indirect reduction minimally invasive techniques. The goal is to strike a balance between the mechanical stability of the fragments and the biological viability by observing the principles of the anatomic reduction of the articular surfaces and the restoration of the femur length, articular alignment and rotation. For supracondylar femur fractures, periarticular locking plates have been rapidly adopted as an alternative to intramedullary nails, blade plates, and nonlocking condylar screws.

In our study the average age was 40.7 years and a S.D of 15 years with majority of the patients being males (M=23; F =4). We had almost an equal incidence of right and left lower limb involvement. Out of the 27 cases, 24 were caused due to road traffic accidents and 3 due to domestic falls. There were no sports injuries or industrial accidents. The average age group, sex distribution and mechanism of injury as encountered during our study points towards the higher incidence of these injuries in males in the productive age group most probably due to the higher incidence of motor vehicular trauma in the same. Our results were similar to the studies done by E.J. Yep *et al* [11], 2004 (average age 44) and Kregor *et al* [9], 2001 (average age 49).

Our study included 6 cases of Type C3 and 21 cases of type C2 fractures. Mean Neer's score at the end of 1 year was 86.0 in the former group and 85.59 in the latter. The difference was not found to be statistically significant.

In our study the average surgical duration was 123 mins. We compared the same with the study done by Kregor *et al* [9] where Less Invasive stabilisation system (LISS) was used and had an average surgical time of 209 mins. This can be expected as smaller incisions used in LISS and the frequent use of image intensifier frequently adds to the operative time. Yeap *et al* [11] also had an average surgical time of 119 mins while using LCP, however most of their cases were extra articular distal femur fractures.

The average blood loss during surgery in our study was 448 cc. (No tourniquet was used in any case). The mean estimated blood loss in a study done by Henry *et al* [12] who treated 125 supracondylar fractures with retrograde nailing was 229 cc. In a separate study done by Valles Figueroa *et al* [13] they found that the average blood loss on using a DCS in 31 patients was 784 cc and 333 cc when LISS was used in 21 patients. The blood loss appears to be less when compared to that when using a Dynamic Condylar Screw but more when compared with lesser invasive procedures like retrograde nailing and LISS.

The average ROM in our study was 0-113 degrees at the end of 1 year. The ROM is near to the other studies done by Kregor *et al*^[9] (0-103 degrees) using LISS(n=66), Yeap *et al*^[11] (0-107 degrees) using LCP(n=11), Figueroa *et al*^[13] using DCS (0-111 degrees) in 31 cases and LISS (0-116 degrees) in 21 cases and Henry *et al*^[12] (0-93 degrees) using retrograde nailing (n=111)

The average union time was 16.1weeks. The time for union during our study was more as compared to studies using LISS by Schandelmaier *et al*^[2] (14.3 weeks) and Markmiller *et al*^[14] (13.8 weeks for LISS and 14.6 weeks for distal femoral nail). The increased average duration in achieving union in our study could be expected as unlike other studies mentioned here, all the cases in our study were intra articular fractures. and also in this study we did open reduction of the fractures.

7.4% of our cases (n=2) had an axial malalignment (varus) after fracture fixation. Yeap *et al*^[11] had similar results (9%) with using a LCP in 11 patients. Mark miller *et al*^[14] had a 15% rate of malalignment when LISS was used and 10.5% when retrograde nailing was used.

The percentage of delayed union and implant failure in our study was 7.4%, which is similar to studies done using other implants, namely Henry *et al*^[12] with retrograde nailing (10 %). Schandelmaier *et al*^[2] using LISS (7.4%)

We had no cases of screw pullout in our study. We believe this may be due to the routine use of bicortical screw purchase in all the holes (locking as well as non-locking) as has been suggested by the studies done on LCP failure in distal femur by Vallier *et al* (2006)^[15] and Johnstone *et al* (2010)^[16]

We had 2 cases of implant failure. In both the cases, failure was through the most proximal of the locking holes in the condylar portion of the plate. Both these patients did not have a screw inserted there. We speculate that, routine placement of a screw through that hole could be considered to reduce the mechanical stress in the fixation construct at that level. Our observations are in sync with those of Vallier *et al* (2006)^[15], who in addition to routine placement of screw at this site had also recommended increasing the cross-sectional thickness of

the plate and/or eliminating the screw hole at that level to improve the fatigue strength of the plate and reduce the frequency of implant failure.

We had 1 case (3.7%) of superficial infection in a patient with co-existing haemophilia in our study, which healed following wound debridement. The incidence of infection in our study using LCP was comparable to other studies using lesser invasive modalities like LISS, namely Kregor *et al*^[9] (3%) and Schutz *et al*^[6] (3%)

We had 2 cases of implant failure when a stainless steel implant was used (n=23). None of the 4 cases treated with a titanium plate had similar complications. However in view of the smaller sample size in the group where titanium plate was used, we are statistically unable to prove superiority of one implant over the other.

The Neer’s score in our study was excellent in 59.25% cases, good in 33.33% cases, average and poor in 3.7% cases each. Similarly when Neer’s score was used by Figueroa *et al*^[13] for comparing outcomes in distal femur fractures treated by DCS (n=31) and LISS (n=21), the results were excellent in 61.30%, good in 19.35%, average in 9.67% and poor in 9.67% in the DCS group whereas the scores were excellent in 71.42%, good in 9.52%, average in 14.28% and poor in 4.76% in cases treated with LISS. However the majority of cases in both these groups were type A and and type B. Similarly a study done using Neer’s scoring system by Pogiati *et al*^[17] following the outcomes of type C1(n=19) and C2(n=11) treated with retrograde nailing had excellent results in 46% and poor outcome in 10% fractures at the end of 6 years

Good planning and execution of surgery in these complex fractures results in better functional outcomes on par with other means of fixation even in these intra-articular injuries.as we compared our study with other published results. If we do a proper anatomical restoration and alignment in these fractures functional outcome is better, however some degree of functional limitation persists in most patients even a year after the surgical procedure in our study.

Author	No	Open # %	Age yrs	F/up mon	ROM	Union weeks	Bone Graft %	infection %	Implant Fail %	Malalignment
Schandelmaier ^[2]	54	18.5	N/A	6	104	14.3	-	1.9	7.4	13
Fankhauser <i>et al</i> ^[18]	30	46.7	57	20	4-113	12	-	-	10	-
Kregor <i>et al</i> ^[9]	103	34	52	14	1-109	12	7	3	5	6
Markmiller <i>et al</i> ^[14]	20	N/A	57	12	0-110	13.8	-	-	10	15
Weight <i>et al</i> ^[19]	22	27	44	18	5-114	13			13.6	
Schutz <i>et al</i> ^[6]	66	32	52	12	112	N/A	9	3	4.5	37
Wong <i>et al</i> ^[20]	16		75	23	N/A	30			12.5	
Yeap <i>et al</i> ^[11]	11	36	44	9.7	1-107	18	18.2	9		9
Our Study	27	25.9	40.7	12	0-113	16.1	7.4	3.7	7.4	7.4

4. Conclusion

The severity of these injuries can be assessed from the finding that most patients have a degree of functional handicap even at 1 year follow up despite of documented sound union at fracture site. The locking compression plates with option of locked screws has provided the means to increase the rigidity of fixation in intra articular fractures, however this is a technically demanding procedure. The device provides good angular stability by its triangular reconstruction principle and thus helps in early mobilization, even in comminuted fractures where other modes of fixation often tend to delay the process of mobilization because of lack of stability. Perhaps one of its greatest applications is in osteoporotic fractures where it may provide a solution to the age old problems of screw pull out, late collapse, and malalignment since the stability of the

construct does not entirely depend on the quality of the bone. No implant can stabilize every fracture type; however, for best results, the device chosen must provide fixation rigid enough for early motion we conclude that this method of fixation is especially suited for fractures where achieving congruence of the articular surface would be difficult with less invasive modalities like retrograde nailing and LISS.

5. References

- Arneson TJ, Melton LJ, Lewallen DG. Epidemiology of diaphyseal and distal femoral fractures in Rochester, Minnesota, 1965-1984. Clin orthop.1988; 234:188-94
- Schandelmaier P, Partenheimer A, Koenemann B. Distal femoral fractures and LISS stabilization. Injury. 2001; 32 Suppl 3:SC55-63.

3. Martinet O, Cordey J, Harder Y. The epidemiology of fractures of the distal femur. *Injury*. 2000; 31(Suppl 3):C62-3.
4. Michael Z, Mohit B. Operative treatment of acute distal femur fractures: systematic review of 2 comparative studies and 45 case series (1989-2005). *J Orthop Trauma* 2006; 20:366-71.
5. Kregor PJ, Stannard J, Zlowodzki M. Distal femoral fracture fixation utilizing the Less Invasive Stabilization System (L.I.S.S.): the technique and early results. *Injury*. 2001; 32Suppl 3:SC32-47.
6. Schutz M, Muller M, Regazzoni P. Use of the Less Invasive Stabilization System (LISS) in patients with distal femoral (AO33) fractures: a prospective multicenter study. *Arch Orthop Trauma Surg* 2005; 125(2):102-8.
7. Giles JB, DeLee JC, Heckman JD. Suracondylar and intercondylar fractures of the femur treated with a supracondylar plate and lag screw. *J Bone Joint Surg* 1982; 64-A:864
8. Hall MF. Two-Plane Fixation of acute supracondylar and intercondylar fractures of the femur. *South Med J*. 1978; 71:1474.
9. Kregor PJ, Stannard JA, Zlowodzki M. Treatment of Distal Femur Fractures Using the Less Invasive Stabilization System: Surgical Experience and Early Clinical Results in 103 fractures. *J Orthop Trauma*. 2004; 18(8):509-20.
10. Heather V, Theresa H, John S. Failure of LCP condylar plate fixation in the distal part of the femur. *J Bone Joint Surg*. 2006; 88-A:846-53.
11. Yeap EJ, Deepak AS. Distal Femoral Locking Compression Plate Fixation in Distal Femoral Fractures: Early Results. *Malaysian Orthopaedic Journal*, 2007; 1(1):12-17. ISSN 1985 2533
12. Henry SL. Supracondylar femur fractures treated percutaneously. *Clin Orthop Relat Res*. 2000; (375):51-59
13. Valles-Figueroa JFJ, Rodríguez-Reséndiz F, Gómez-Mont JG. Distal femur fractures. Comparative analysis of two different surgical treatments. *Acta Ortopédica Mexicana* 2010; 24(5):323-329.
14. Markmiller M, Konrad G, Sudkamp N. Femur-LISS and distal femoral nail for fixation of distal femoral fractures: are there differences in outcome and complications? *Clin Orthop Relat Res*. 2004; (426):252-257.
15. Vallier HA, Hennessey TA, Sontich JK, Patterson BM. Failure of LCP condylar plate fixation in the distal part of the femur. A report of six cases. *J Bone Joint Surg Am*. 2006; 88(4):846-853.
16. Johnstone A, Carnegie C, Christie E, Mccullough A. The challenges associated with treating distal femoral fractures with locking plates in the elderly: differing patterns of failure with different locking plates *J Bone Joint Surg Br*. 2010; 92(IV):550
17. Pogiatzis K, Katsenis DL, Kouris A, Schoinochoritis N, Tselfes P. Type C 1 and 2 Fractures of the Distal Femur Treated with a Retrograde Nail: Knee Recovery at Six Years Follow-Up *Osteo trauma care* 2006; 14(1):45-50.
18. Fankhauser F, Gruber G, Schippinger G. Minimal-invasive treatment of distal femoral fractures with the LISS (Less Invasive Stabilization System): a prospective study of 30 fractures with a follow up of 20 months. *Acta Orthop Scand*; 2004; 75(1):56-60.
19. Weight M, Collinge C. Early results of the less invasive stabilization system for mechanically unstable fractures of the distal femur (AO/OTA types A2, A3, C2, and C3). *J Orthop Trauma*. 2004; 18:503-508.
20. Man-Kwan Wong, Frankie Leung, Shew Ping Chow. Treatment of distal femoral fractures in the elderly using a less-invasive plating technique *Int Orthop*. 2005; 29(2):117-120.