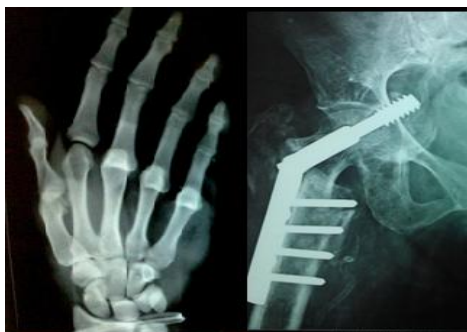

International Journal of Orthopaedics Sciences

ISSN: 2395-1958
IJOS 2016; 2(2): 74-76
© 2016 IJOS
www.orthopaper.com
Received: 09-02-2016
Accepted: 16-03-2016

Dr. Mohammed Ibrahim
Department of Orthopaedics,
Gulbarga Institute of Medical
Sciences Gulbarga, Karnataka,
India

Dr. Meganath Pawar
Department of Orthopaedics,
Gulbarga Institute of Medical
Sciences Gulbarga, Karnataka,
India

Dr. Kausar Nazneen
Department of Orthopaedics,
Gulbarga Institute of Medical
Sciences Gulbarga, Karnataka,
India

Correspondence
Dr. Mohammed Ibrahim
Department of Orthopaedics,
Gulbarga Institute of Medical
Sciences Gulbarga, Karnataka,
India

Tens (titanium elastic nails) in fractures shaft of the femur in children

Dr. Mohammed Ibrahim, Dr. Meganath Pawar and Dr. Kausar Nazneen

Abstract

TENS nailing, was done in 10 patients of femoral fractures with either transverse or short oblique fracture or spiral with some comminution. Only condylocephalic approach was used. Average per-operative blood loss was about 50 ml and average operative time was only 45 minutes. There was no case of nail breakage, infection, delayed malunion or non-union. Range of knee movement achieved in most of the cases was more than 120 degree. The method is simple, quick and atraumatic. **KEYWORDS:** Femur, Diaphysis, Elastic nail.

Keywords: TENS, Fracture shaft, femur

Introduction

Traditional management of pediatric femoral shaft fractures has been by immobilization in spica cast. Indications for surgical management were few and included children with associated injuries like head injury, abdominal injury or compound fracture with extensive soft tissue trauma. As the management of femoral shaft fractures in children evolved, complications such as limb length discrepancy, torsional and angular deformities were noticed with spica cast management even after proper precaution. To add to that were the psychosocial implications of spica cast treatment, with separation of child from his environment and the difficulties in taking care of a child in spica.^{1,2,3} Because of the above complications indication of surgical management of paediatric femoral shaft fractures has been widened to include isolated femoral shaft fracture ^{4,5,6,7}. In this study we report the use of Elastic nails for flexible intramedullary nailing of femoral shaft fractures in children. Stabilizing femoral diaphyseal fractures with an intramedullary implant is now generally accepted. This study evaluates the out-come of multiple Elastic nails in femoral diaphyseal fractures.

Material and Methods

We included children between 3-14 years with fracture shaft femur at least 3cm distal to lesser trochanter and 3 cm proximal to physis. Operative Technique: On a fracture able, traction was applied under fluoroscopic guidance to reduce the fracture. Proper size Elastic nails of 2 to 3.5mm diameter were taken. Nails were bent in an even curve. The tip was further bent 2cm from one end at 40 degree. This facilitates the nail to bounce of the opposite cortex into the canal rather perforate it. After incising the skin, insertion points were made one on medial and another on lateral side of distal femur, 2cm proximal to the distal epiphyseal plate. The nails were introduced right up to fracture site. Than one of the nail was passed across the already reduced fracture site followed by second nail. The nails were directed in such a way that medial nail was introduced into the neck and lateral just below trochanteric apophysis in a fan shaped manner. Two divergent Elastic nails provide adequate fixations and stability in adolescent femur^{8, 17}. To prevent knee pain and problems of nail protrusion the distal end of nail should never project beyond distal epiphyseal plate on IITV and care should be taken to avoid pending the distal end of nails. Knee bending and quadriceps setting exercises were started as soon as the patient could tolerate it, usually within first 24 hrs itself. Non-weight bearing ambulation was started with in first few days, though partial weight bearing was permitted only after radiological evidence of callus formation. Full weight bearing was permitted only on radiological evidence of firm union. Minimum follow up of the patients was 1 years (average 12 months).

Results

Between March 2013 and April 2015, 10 children with 10 femoral shaft fractures were treated with Elastic nails. Ages of children ranged from 3-14 years (mean 7.67 years). There were 8 boys and 2 girls. The M: F ratio in 3-14 years was 8 males and 2 females respectively whereas males far outnumbered females. All patients sustained injury due to fall from height. No cases with bilateral fractures were seen. In all 6 fractures were in middle third, 2 in distal third, and 2 in proximal third. 5 cases had transverse fracture, 2 were in oblique and 2 were spiral in pattern. On Winquist 9 grading system 3 were grade I, two were grade II, one was grade III, and one was grade IV. No segmental fractures were seen. Open fractures were not included. Associated injuries were seen in 4 cases. The interval between injury and surgery varied from 2 days to 5 days. The mean hospital stay was 7 days. The average duration of surgery was 45 min. The mean fluoroscopy time was 66 f/sec. All the cases operation could be performed in a closed manner with small incisions and minimal blood loss. Postoperatively no patient needed any protective splint. Knee bending and quadriceps strengthening exercises were begun as soon as

patient was comfortable. Any attempt to passively bend knee is not desirable as it causes reflex quadriceps spasm. Partial weight bearing on axillary crutches was begun around 4 weeks depending on fracture configuration callus formation and patient tolerance. Full weight bearing could be commenced in about 6-8 weeks-time more in most of the cases. The average time to full weight bearing was 6.6 week (5 to 12 week), full movement was achieved in 9 weeks (6 to 15 week). Complications: one cases of nail protrusion due to long nails occurred. In that cases the nail was removed at three and half month. No deep infection occurred. Fracture proceeded to union without any other sequel. Follow up: The mean follow up was 8.1 month (6 to 12 months) by this time all the patients had full-unrestricted activity. None of the patients had any pain, limp or gait abnormality No angular deformity was observed in any patients. No lengthening or Shortening was seen in patients. No discrepancy was seen in any patients. On clinical examination significant malrotation was not seen in any patient. According to the Flynn criteria 10 [Table - 1] 10 patients had excellent result, (Fig. 1, 2, 3) 4 satisfactory and none poor result.

Table I: Flynn *et al* 10 (2001) criterion for assessment of results

	Excellent	Satisfactory	Poor
Limb length inequality	< 1cm	< 2 cm	> 2 cm
Malalignment	Up to 50	5-100	> 100
Pain	None	None	Present
Complication	None	Minor	Major.

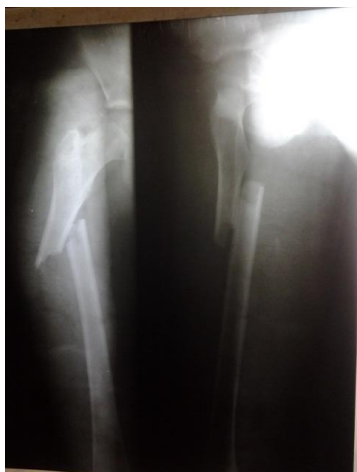

Fig 1: Flynn criteria 10: excellent result (example 1)

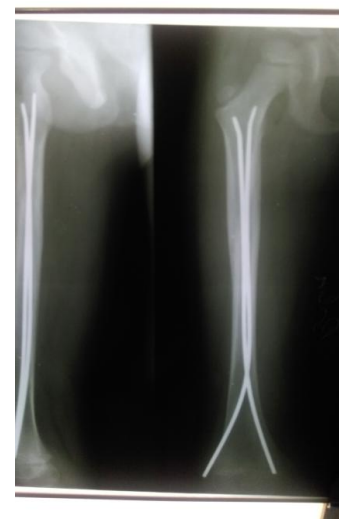


Fig 3: Flynn criteria 10: excellent result (example 3)

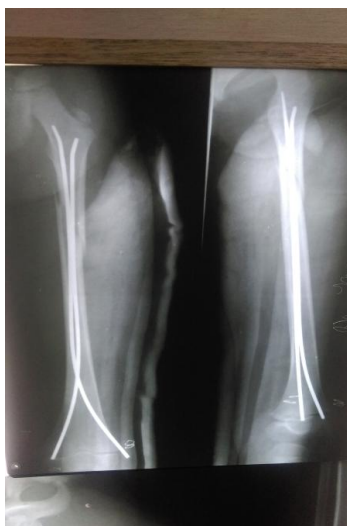

Fig 2: Flynn criteria 10: excellent result (example 2)

Discussion

The treatment of children with femoral shaft fractures in age group 3-14 years is highly controversial. Many orthopedician reserve surgical management for multiply injured patients. This study aimed to treat isolated femoral shaft fractures surgically. The advantages of Elastic intramedullary nailing (FIN) over spica management have convinced us to treat isolated femoral shaft fractures in 3-14year with Elastic intramedullary nailing. Spica treatment has disadvantages such as prolonged hospital stay, shortening, angular and torsional deformity and the psychosocial implication of treatment of femoral shaft fractures. These were avoided in treatment with FIN.7,11 External fixation although is associated with minimal soft tissue dissection but it causes patient apprehension on account of external device, high rate of pin track infection and real danger of refracture after removed of fixator.12-14 Rigid

intramedullary nailing may damage the blood supply to the femoral head resulting in AVN or causing growth arrest at the greater trochanter resulting in coxa valga. They were not advised for children. Flexible nailing requires less operative as well as fluoroscopy time.¹¹ Compression plating is associated with large soft tissue dissection opening of fracture site major operation for removal. Some limb lengthening may be seen in femoral fractures treated by surgery. Ligier *et al* ¹⁵ in their series showed a mean lengthening of 1.2 mm, and residual angulations never exceeding 100. This surgical procedure is technically simple, time saving and can be done in a closed manner.¹¹ It allows early mobilization, rapid external callus formation and rapid restoration of continuity of bones even as allowing ease in patient care.^{7,15,16} Two divergent ender nails provide adequate fixation and stability in adolescent femur fracture⁸. The major advantages of FIN is in rehabilitation and healing with abundant callus, attributed to non-rigid fixation.¹⁷ This results in rapid fracture union and early return to full weight bearing while reducing hospital stay and treatment cost.

References

1. Greisberg J, Bliss MJ, Ebersson CP, Solga P, D'Amato C *et al*. Social and economic benefits of flexible intramedullary nails in treatment of pediatric femoral shaft fractures. *Orthopedics*. 2002; 25(10):1067-70.
2. Hughes BF, Sponseller PD, Thompson JD. Pediatric femur fractures effect of spica cast treatment of family and community. *J Pediatr Orthop*. 1995; 15:455-460.
3. Reeves RB, Ballwered RI, Hughes JL. Internal fixation versus traction and casting of adolescent femoral shaft fractures. *J Pediatr Orthop*. 1990; 10:592-595.
4. Heinrich SD, Dravric D, Darr K *et al*. Stabilization of pediatric diaphyseal femur fracture with flexible intramedullary nails (a technique paper). *J Orthop Trauma*. 1992; 15:455-460.
5. Karaoglu S, Baktir A Tuncel M, Karakas ES, Sakir TM. Closed Ender nailing of adolescent femoral shaft fractures. *Injury*. 1994; 25(8):501-6.
6. Mann DC, Weddengron J, Davenport K. Closed Ender nailing of femoral shaft fractures in adolescents. *J Pediatr Orthop*. 1986; 6:651-665.
7. Mazda K, Khairouni A, Pennecot GF *et al*. Closed flexible intramedullary nailing of the femoral shaft fractures in children. *J Pediatr Orthop*. 1997; 6:198-202.
8. Lee S, Mahar AT, Newton PO. Ender nail fixation of pediatric femur fractures a biomechanical analysis. *J Pediatr Orthop*. 2001; 21(4):442-5.
9. Winkquist RA, Hansen ST Jr. Comminuted fractures of the femoral shaft treated by intramedullary nailing. *Orthop Clin North Am*. 1980; 11:633-48.
10. Gregory P, Sullivan JA, Hernodon WA. Adolescent femoral shaft fractures: rigid versus flexible nails. *Orthopedics*. 1995; 18:645-649.
11. Aronson J, Tursky RN. External fixation of femur fractures in children. *J Bone Joint Surg (Am)*. 1987; 69:1435-1439.
12. Bar-On E, Sagiv S, Porat S. External fixation or flexible intramedullary nailing of femoral shaft fractures in children. A prospective, randomized study. *J Bone Joint Surg (Br)*. 1997; 79:975- 978.
13. Gregory P, Pevny T, Teaque D. Early complications with external fixation of paediatric femoral shaft fractures. *J Orthop Trauma*. 1996; 10:191-198.
14. Ligier JN, Metaizeau JP, Prevot J *et al*. Elastic stable intramedullary nailing of femoral shaft fractures in adolescents. *J Bone Joint Surg (Br)*. 1988; 70:74-77.
15. McGraw JJ, Gregory SK. Ender nails: an alternative for intramedullary fixation of femoral shaft fractures in children and adolescents. *South Med J*. 1997; 90(7):694-6.
16. Yamaji T, Anodo K, Nakamura T, Washimi O, Terada N, Yamada H. Femoral shaft fracture callus formation after intramedullary nailing a comparison of interlocking and Ender nailing. *J Orthop Sci*. 2002; 7(4):472-6.
17. Flynn Joh M, Heresko Trinity *et al*. Titanium elastic nailing for paediatric femur fractures-a multi-centre study of early results with analysis of complications. *Journal of paediatrics orthopaedics*. 2001, 21(1):4-6.