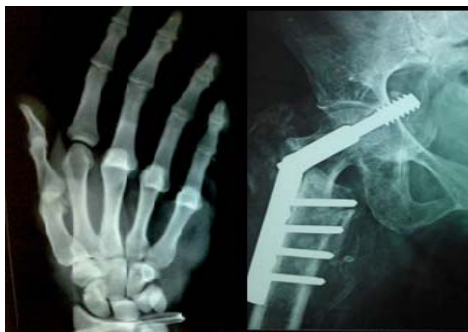



International Journal of Orthopaedics Sciences

ISSN: 2395-1958
IJOS 2016; 2(2): 28-30
© 2016 IJOS
www.orthopaper.com
Received: 03-02-2016
Accepted: 25-03-2016

Dr Abdul Gafoor PM
Department of Orthopaedics,
Baby Memorial Hospital,
Calicut, Kerala.

Dr Gangadharan P
Department of Orthopaedics,
Baby Memorial Hospital,
Calicut, Kerala.

Dr Mahesh Brungi
Department of Orthopaedics,
Baby Memorial Hospital,
Calicut, Kerala.

Dr Ajith Thomas Abraham
Department of Orthopaedics,
Baby Memorial Hospital,
Calicut, Kerala.

Charcot's osteoarthropathy of the shoulder

**Dr. Abdul Gafoor PM, Dr. Gangadharan P, Dr. Mahesh Brungi,
Dr. Ajith Thomas Abraham**

Abstract

Charcot's joint or neuropathic osteoarthropathy of the shoulder joint is an uncommon disease characterized by its destruction due to loss of sensory perception of the joint. Appropriate clinical assessment, diagnostic workup and treatment are essential in the management of Charcot joint. Patient education on activity modification must be included in the management as such knowledge may slow or prevent the impairment associated with a Charcot joint. Here we are reporting a case of neuropathic osteoarthropathy of the shoulder that occurred secondary to syringomyelia. The clinical features, pathophysiology, differential diagnosis, diagnostic workup and management options are discussed.

Keywords: Charcot joint, Neuropathic arthropathy, Syringomyelia, Shoulder

Introduction

Charcot osteoarthropathy is a chronic, destructive condition of the joint due to loss of proprioception, pain and temperature perception [1, 2]. Diabetes mellitus, syringomyelia and syphilis are the most common etiologies of this disease [3]. Other occasional associations are leprosy, peripheral nerve injury, myelomeningocele, spinal cord injury, amyloidosis, familial congenital insensitivity to pain and dysautonomia [4]. Shoulder joint involvement in Charcot arthropathy is uncommon and has been reported in 6% of patients with neuropathic arthropathy [5]. Charcot arthropathy of the shoulder has been reported in less than 70 patients in the literature [6]. Neuropathic arthropathy should be considered in cases of unexplained joint swelling which is disproportionate to the pain, with a limited range of active motion and an exaggerated range of passive movements of the affected joint. We are presenting a case of Charcot arthropathy of the shoulder secondary to syringomyelia with classical clinical and radiological findings.

Case report

A 62 year old female presented with painless swelling of her right shoulder with restricted active movements. Her condition began as reduced sensation in her right upper limb when she was approximately 35 years old. No medical treatment was taken other than some indigenous treatment in the form of some oil for local application and her condition gradually worsened. There was no history of any significant illness in the childhood or trauma in the past.

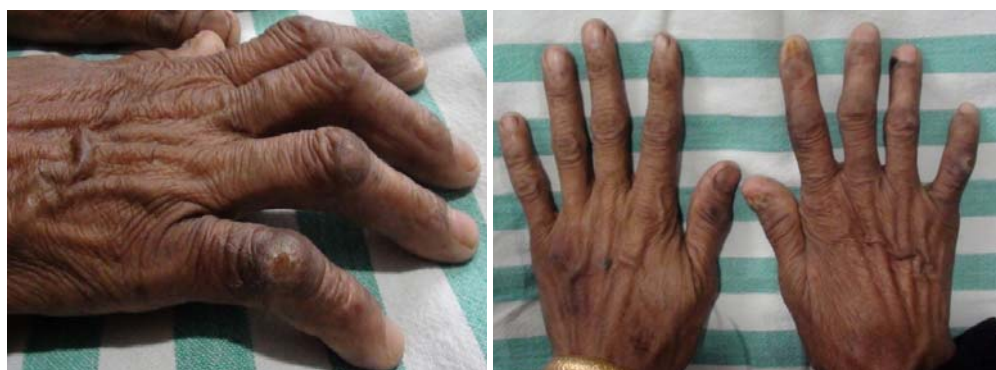

Fig 1: Right hand showing healed trophic ulcers, clawing and wasting of Interosseus

Correspondence
Dr Abdul Gafoor PM
Department Of Orthopaedics,
Baby Memorial Hospital,
Calicut, Kerala.

Physical examination revealed diffuse swelling about the right shoulder. On palpation there was no joint tenderness or local rise of temperature. There was increased girth and exaggerated passive movements possible at the right shoulder joint in all directions compared to opposite side. There was generalized muscle wasting in the right upper limb. She had 3/5 shoulder abductor strength and 4/5 shoulder flexor and extensor strength. Her triceps and biceps strength was 4/5, while motor

strength in left upper limb and bilateral distal extremities was 5/5. There was reduced sensation of the entire right upper extremity and healed trophic ulcers were seen on the fingers and the dorsal and ulnar border of the forearm and hand (Fig 1). There was wasting of the thenar, hypothenar and Interossei muscles. The triceps, biceps and brachioradialis reflex were absent.

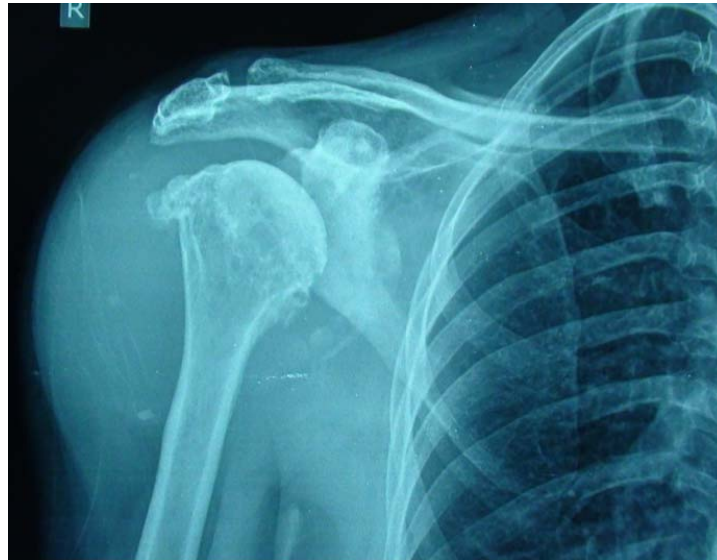

Fig 2: X-ray right shoulder; increased soft tissue shadow with degenerative changes in humeral head and glenoid with reduced joint space and diffuse osteophytes.

Patient was worked up with routine blood investigations, X-ray of the shoulder and magnetic resonance imaging (MRI) of the cervical and thoracic spine. All the hematological investigations were within normal limits. X-ray of right shoulder showed increased soft tissue shadow with degenerative changes in the humeral head and glenoid with reduced joint space and diffuse osteophytes (Fig 2). MRI (magnetic resonance imaging) of cervical and dorsal spine showed a large syrinx from the fourth cervical spine to the third dorsal spine (Fig 3). She was managed with limb elevation, shoulder abduction brace and nonsteroidal anti-inflammatory and was advised regarding activity modification. At present, the patient is doing well with conservative mode of therapy and is performing her daily activities and selfcare.

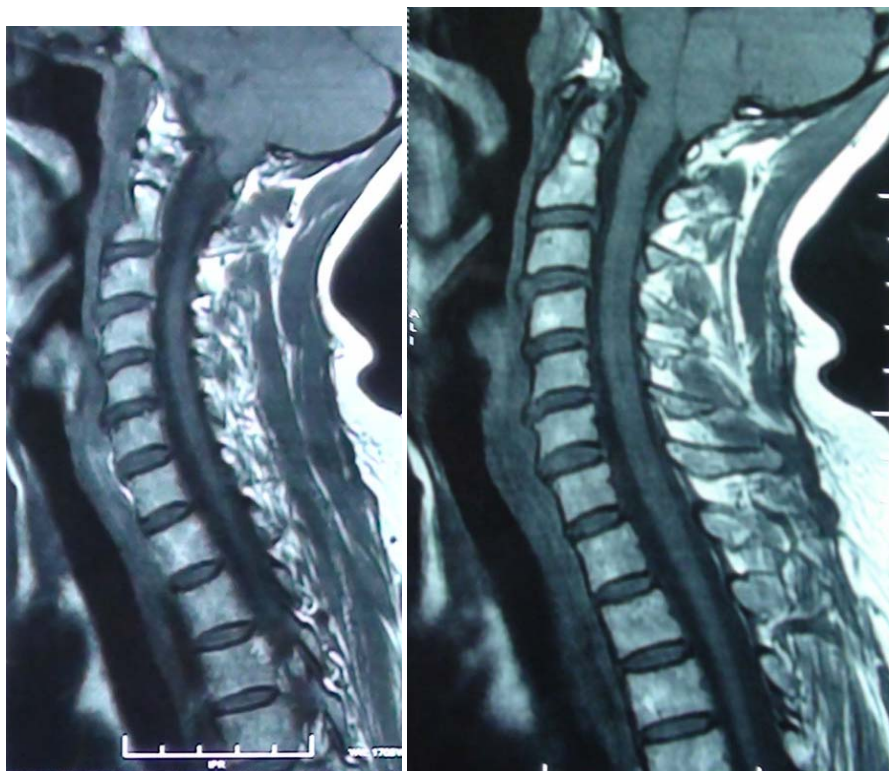


Fig 3: MRI (magnetic resonance imaging) of cervical and dorsal spine showing syrinx from the fourth cervical spine to the third dorsal spine

Discussion

The diagnosis of neuropathic arthropathy is often delayed. There are two theories explaining the pathogenesis of neuropathic osteoarthropathy. These are the neurovascular and the neurotraumatic theories. According to the neurovascular Theory, described by Allman *et al.*, active bone resorption by osteoclasts occurs secondary to sympathetic dysfunction and a neurally mediated persistent hyperemia. If fractures and other forms of trauma are involved, this theory suggests that they occur secondarily^[3]. The neurotraumatic theory proposed by Johnson in 1967, states that repetitive trauma in an insensate joint leads to the formation of a neuropathic joint^[1]. Neuropathic arthropathy of the shoulder usually presents in a striking fashion, producing extensive and rapid destruction of the proximal aspect of the humerus and the glenoid. The three stages of progression of this condition which can be done clinic radiologically was described by Eichenholtz as the stages of (1) development, (2) coalescence and (3) reconstruction and reconstitution⁷. The differential diagnoses to be considered are septic arthritis, tuberculous and microbial infection, primary and metastatic malignant tumor of the bone or soft tissue, synovial chondromatosis, idiopathic osteolysis, nephropathy, Gorham disease and Winchester syndrome^[4].

Syringomyelia is a disorder characterized by a fluid containing cavity (syrinx) in the medullary canal of the spinal cord. The most common sites are the lower cervical and upper thoracic segments, and the cavity may propagate proximally. The etiology for syrinx can be congenital, trauma, degenerative, infection, tumor or vascular related^[2, 8, 9]. MRI is considered the gold standard investigation for its visualization^[9].

Syringomyelia is a potential cause of Charcot osteoarthropathy of the shoulder. It may present as instability or a frank dislocation of the shoulder. A neuropathic joint associated with syringomyelia may develop early or late in the course of disease. Neuropathic osteoarthropathy of the shoulder usually progresses slowly, but rapid progression can occur over months or even weeks^[10]. Diabetic patients are usually affected with the joints of the foot and ankle, larger joints such as the knee is usually involved in patients with syphilis^[4]. Shoulder and the elbow joints are affected in cases of syringomyelia, and the hand and wrist involvement has been reported less frequently^[5].

Joint effusion, soft-tissue swelling, joint space narrowing with subchondral sclerosis, and osteophyte formation are the early radiographic features of a neuropathic joint and hence differentiating a primary osteoarthrosis from a neuropathic arthropathy is difficult radiologically in the early stages.

The management for neuropathic arthropathy is conservative. Preventing further trauma to the affected joint with proper splinting is the key to treatment. Splinting and aspiration of large effusions will reduce further ligamentous laxity^[1, 2]. Studies have reported unsatisfactory results with surgical interventions such as arthrodesis, resurfacing operations, and hemiarthroplasty for the treatment of neuropathic shoulder arthropathy^[7, 11].

In our case, conservative management of the affected shoulder joint provided an acceptable level of function with tolerable pain. The goal of management is to avoid repetitive trauma to the joint so as to prevent its further damage, which can be best done with activity modification and the use of braces.

Conclusion

Charcot's shoulder is an uncommon disease with less than 70 cases reported in the literature. But proper knowledge of the condition and thorough clinical evaluation in the form of

proper history, physical examination including the neurological system, appropriate radiological tests and pathological evaluation when needed will help in the diagnosis. Once the diagnosis of a neuropathic joint has been made, its etiology should be found out with appropriate blood investigations, joint aspiration and radiological evaluation including MRI of the spine. In order not to delay or miss the diagnosis, the orthopedic surgeon should be aware of this rare disorder and its characteristic clinical and radiological signs.

Conflict of interest

The authors report no conflict of interests. No benefits or funds were received in support of this study.

References

1. Johnson JT. Neuropathic fractures and joint injuries: Pathogenesis and rationale of prevention and treatment. *J Bone Joint Surg Am.* 1967; 49:1-30.
2. Jones J, Wolf S. Neuropathic shoulder arthropathy (Charcot joint) associated with syringomyelia. *Neurology* 1998; 50:825-7.
3. Allman RM, Brower AC, Kotlyarov EB. Neuropathic bone and joint disease. *Radiol Clin North Am* 1988; 26:1373-81.
4. Shapiro G, Bostrom M. Heterotopic ossification and Charcot neuroarthropathy, in *Chapman's Orthopaedic Surgery*, M.W. Chapman, Ed., Lippincott Williams & Wilkins, Philadelphia, Pa, USA, 2001, 3245-3262.
5. Hatzis N, Kaar TK, Wirth MA, Toro F, Rockwood Jr CA. Neuropathic arthropathy of the shoulder, *Journal of Bone and Joint Surgery.* 1998; 80(9):1314-1319.
6. Biyani A, el Masry WS. Posttraumatic syringomyelia: A review of the literature. *Paraplegia* 1994; 32:723-73.
7. Eichenholtz SN. Charcot joints. In: Thomas CC, editor. *Springfield*, 11, 66.
8. Klekamp J. The pathophysiology of syringomyelia-historical overview and current concept. *Acta Neurochir (Wien)* 2002; 144:649-64.
9. Meyer GA, Stein J, Poppel MH. Rapid osseous changes in syringomyelia. *Radiology* 1957; 69:415-8.
10. Rawat B, Bell RS. Case report: rapidly progressive neuropathic arthropathy in syringohydromyelia: radiographic and magnetic resonance imaging findings, *Clinical Radiology* 1994; 49(7):504-507.
11. Crowther MAA, Bell SN. Neuropathic shoulder in syringomyelia treated with resurfacing arthroplasty of humeral head and soft-tissue lining of glenoid: a case report, *Journal of Shoulder and Elbow Surgery.* 2007; 16(6):e38-e40.