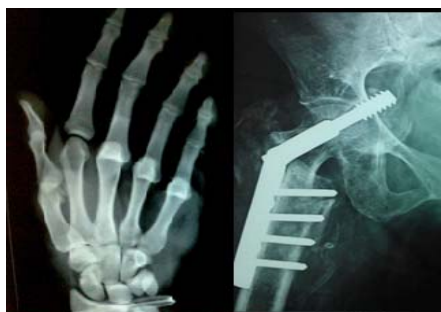



International Journal of Orthopaedics Sciences

ISSN: 2395-1958
IJOS 2016; 2(1): 18-21
© 2016 IJOS
www.orthopaper.com
Received: 11-11-2015
Accepted: 14-12-2015

K Mohan Iyer
Senior Consultant Orthopaedic
Surgeon, Bangalore, India.

Modified posterior approach to the hip joint

K Mohan Iyer

Abstract

This modification was developed in 1981 by Cadaveric Tests prior to clinical application in patients, and this was primarily devised anatomically to decrease dislocations of the Hip Joint. Here the bone over the greater trochanter was osteotomised at its posterior overhanging part to provide for access to the Hip Joint, which was resutured using 2 stainless steel wires. In order to reconstitute the hip joint.

Keywords: Dislocation, Trochanteric Osteotomy

1. Introduction

A series of cadaveric tests were conducted on cadavers to determine the superiority of this Modification over the conventional Southern, Posterior Approach as described by Austin Moore in 1957.

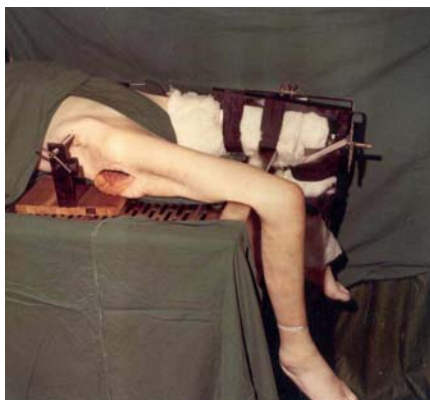

Fig 1: Device used to test stability of the hip joint showing pelvis fixed and protectors to measure the angle of flexion/extension, adduction/abduction and internal/external rotations (Courtesy: Photograph reproduced with the kind permission of Injury/Elsevier)

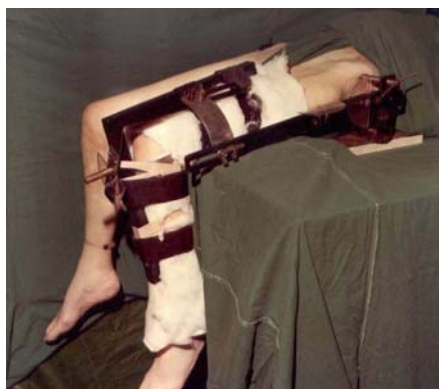

Fig 2: Device used to test stability of the hip joint showing pelvis fixed and protectors to measure the angle of flexion/extension, adduction/abduction and internal/external rotations (Courtesy: Photograph reproduced with the kind permission of Injury/Elsevier)

Correspondence
K Mohan Iyer
Senior Consultant Orthopaedic
Surgeon, Bangalore, India.

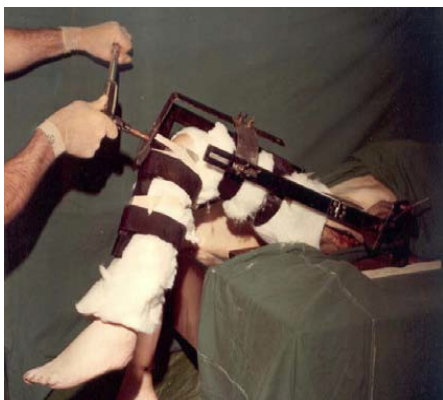

Fig 3: Internal rotation torque being applied when the hip joint was standardized to a fixed angle of flexion and adduction (Courtesy: Photograph reproduced with the kind permission of Injury/Elsevier)

The stability of the Hip Joint was tested as seen above by applying torque with the Hip Joint standardized to fixed angle of flexion and adduction, to mainly see whether the trochanteric fixation disrupted or the Hip Joint dislocated.in all

the 3 cadavers tested, the Hip Joint never disrupted indicating greater stability and hence this devised Modified Posterior Approach was used in patients.

The patient is placed on the sound side. The skin incision extends from just distal and lateral to the posterior superior iliac spine towards the lateral edge of the greater trochanter, with a curve in the direction of the fibres of gluteus maximus, and extends down the shaft of the femur for about 10 cm. The gluteal fascia and the ilio-tibial tract are exposed; the deep fascia incised vertically in the lower part of the incision and the incision is curved upwards through the middle of the fibres of gluteus maximus.

The greater trochanter is osteotomised (Fig.4) through so that the detached part includes the insertion of the following structures. From below upwards these are quadratus femoris, obturator internus with the inferior and superior gemelli, piriformis and the posterior third of the fibres of the gluteus medius. The osteotomy extends from the junction of the posterior third and anterior two-thirds of the lateral border of the greater trochanter obliquely downwards and posteriorly to the shaft of the femur just distal to the quadrate tubercle.

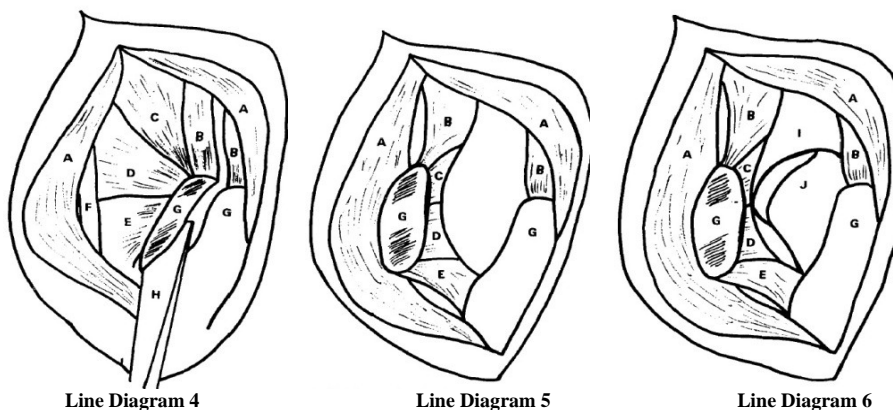


Fig 4: Line Diagram showing the osteotomy of the posterior overhanging part of the greater trochanter:(Courtesy: Line Diagram reproduced with the kind permission of Injury/Elsevier); A, Gluteus maximus; B, Gluteus medius; C, piriformis; D, triradiate tendon; E, quadratus femoris; F, sciatic nerve; G, greater trochanter, H, osteotome
Fig 5: Line Diagram showing the osteotomy completed and the flap retracted. (Courtesy: Line Diagram reproduced with the kind permission of Injury/Elsevier); A, Gluteus maximus; B, gluteus medius; C, piriformis; D, triradiate tendon; E, quadratus femoris; G, greater trochanter
Fig 6: Line Diagram to show that the Osteotomy is completed and the flap retracted, after incising the capsule to expose the Hip Joint,

(Courtesy: reproduced with the kind permission of Injury/Elsevier)

Line diagram showing the following structures: A, gluteus maximus, B, gluteus medius; C, piriformis; D, triradiate tendon; E, quadratus femoris; G, greater trochanter; I, acetabulum; J, femoral head
 The posterior triangular flap containing the overhanging posterosuperior part of the greater trochanter at its apex is then dissected free and turned down to expose the capsule of the hip joint (Fig.5). The capsule is then incised to expose the joint(Fig.No.6 & 7)After completing the work on the Hip Joint, the Greater Trochanter is reconstituted by wiring(Fig.No8) with 2 Stainless steel wires, gauge 18 and thereafter the Hip Joint is closed routinely(Fig 9)

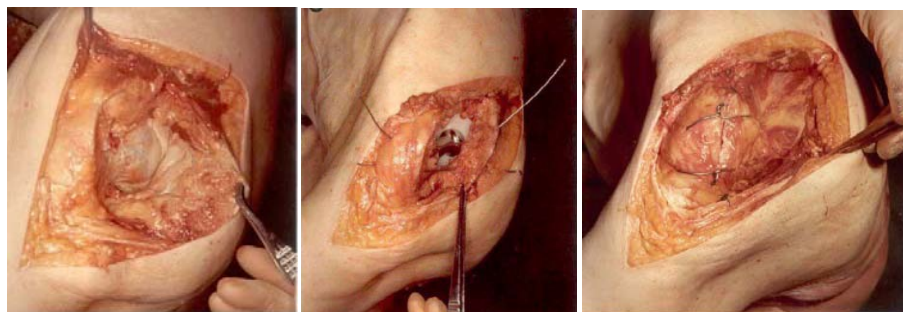


Fig 7: Hip Joint opened; Fig.No.8: Wiring of the trachanteric fragment; Fig.No.9: Closure of the Hip Joint (Figs 7,8 &9: Courtesy: reproduced with the kind permission of Injury/Elsevier)

Check X-rays are routinely done after the operation (Fig.No.10)

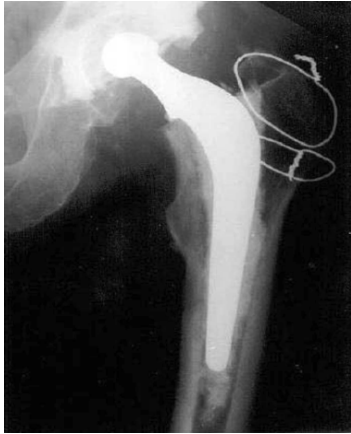

Fig 10: Radiograph of Total Hip Prosthesis. (Courtesy: reproduced with the kind permission of Injury/Elsevier)

The Modified Posterior Approach follows the anatomical intermuscular plan and permits full exposure of both the proximal femur and the acetabulum. (Refs.No.1,2,3 &4) Iyer, Shatwell and Elloy reported on early results in 44 patients who had a hemiarthroplasty done with no dislocation in this series. (Ref.No.5)

Compared to the literature, preserving the piriformis tendon seems to be superior to repairing it as is done in the Southern Approach in terms of dislocation of the Endoprosthesis or THR. (Refs No. 6 & 7)

Mark Coventry did concur with the concept of this approach in imparting more stability posteriorly postoperatively, as compared to all other posterior approaches to the hip joint described since 1874, which either divide the short external rotators or pass between them which thereby increase the risk of postoperative dislocation of the hip. (Ref.No. 8)

After I described this Approach, it was quite encouraging that my respected teacher (Mr.F.H.Beddow) in Liverpool, UK did a series of 220 Primary Total Hip Replacements by my technique and noted only 2 dislocations throughout his series. (Ref.No.9)

Beddow and Tulloch reported on their experience using this approach in 220 cases of primary total hip replacement in which there were only 2 cases of dislocation. James Shaw mentioned the usefulness of this approach (Ref.No.10) in complex primary cases and revision hip surgery stressing on the excellent exposure of the acetabulum and femoral shaft, while eliminating many of the problems associated with other techniques. He described his own experience by reattaching the trochanteric fragment with 2 lag screws. He did stress this approach gives an excellent exposure of both the acetabulum and femur without dissection through scarred anterior or posterior soft tissue planes or forceful retraction on adjacent tissues and that the potential for damage to the sciatic or femoral nerves or femoral vessels is considerably less. He also noted the obvious advantages to postoperative function as the muscle insertions of the short lateral rotators are undisturbed, thereby restoring hip stability and leaving an intact and considerably uncompromised envelope of soft tissues on the prosthetic joint.

Terry Canale (Campbell's Operative Orthopaedics, 9th Edition, 1992) does make a reference to this approach in their chapters on Surgical Approaches and Complications after Total Hip Arthroplasty with respect to dislocations. (Refr.No:11)

Callaghan, Rosenberg and Rubash (The Adult Hip, 1998) [12] mention the advantages of preserving the original soft tissue attachments of the posterior aspect of the hip joint, as obtained with this approach. They also stress on the excellent exposure of both the acetabulum and femoral shaft achieved with this approach in being applicable to both revision arthroplasty and complex primary arthroplasty. (Refr.No:12)

Thomas Stahelin et al (2002) [13] have stated that the failure rate of reinserted short lateral rotators was extremely high at 70% with majority of failures occurring within the first postoperative day. They also concluded that bone to bone reattachment as done in this approach is more secure, as proved by the cadaveric study. (Refr.No:13)

Deepa Iyer (2006) [14] was fascinated by this Orthopaedic Dilemma in the elderly that she studied this fracture in detail and noted its importance for the junior doctors in training, thereby decreasing morbidity by early diagnosis and treatment. (Refr.No:14)

Robert H. Cofield (2010) [15] of Mayo Clinic in Rochester, Minnesota, USA has been using this approach for the last 25 years with no regrets. He is extremely happy using this approach since I presented it during the Scientific Congress of the Asean Orthopaedic Association in Singapore in 1984. (Refr.No:15)

Mayo Clinic conducted a study of 68 consecutive cases by the Modified Posterior Approach to the Hip Joint. There were no cases of late instability. Posterior approach to the hip joint through a posterior trochanteric osteotomy is associated with high union rates and a low rate of late instability after hip replacement. (Refr.No:16)

I am also in regular touch with Daniel J Berry of the Mayo Clinic, Minnesota, USA who states that he currently uses the posterior approach to the hip for most primary hip arthroplasties, while for revision arthroplasties, he frequently uses the extensile approaches including extended greater trochanteric osteotomy (Ref.17)

They concluded one disadvantage of the posterior trochanteric osteotomy is the potential for injury to the superior gluteal nerve if the gluteus medius muscle split is extended proximally more than 5 cm from the tip of the trochanter.

In the Modified Posterior Approach to the Hip Joint, bleeding is minimal, because the plane of cleavage through the gluteus maximus is through its middle thus leaving intact the branches of the superior gluteal artery in the proximal half and branches of the inferior gluteal artery in the distal half, and hence there is no need to worry about the amount of blood lost. Bleeding is further reduced as the leash of vessels which lies at the inferior border of the short lateral rotators is neither cut nor handled.

The most important advantage is that the sciatic nerve is not isolated at any step in this approach, as corresponding to the level of the greater trochanter, it lies well medially. Above all, it is firmly held between the piriformis tendon and the triradiate tendon, when the greater trochanter is turned posteriorly, thereby preventing any movement of the nerve.

With this modified posterior approach to the Hip Joint, the gluteus medius is neither cut at its origin nor insertion, thereby leaving the abductor mechanism intact.

In this Modified Posterior Approach, Union of the trochanteric fragment should normally occur, as it is through cancellous bone and in close proximity to the anastomosis in the trochanteric fossa.

The concept of trochanteric osteotomy was mainly used in difficult exposures and soft tissue tensioning. Contemporary THA accentuates a streamlined approach to surgery and recovery while maximizing long-term success.

The standard osteotomy may be oblique or posterior. The standard TO was originally popularized for use in hip arthroplasty by Charnley (Refr. No: 18).

Complications of trochanteric osteotomy can be divided into two broad categories: those related to osteotomy healing and those related to the mode of fixation. Nonunion or a fibrous union of the trochanter is not necessarily a complication with clinical significance. [If the trochanter does not heal by bony bridging, however, associated issues of pain, hardware breakage, or abductor dysfunction may manifest as impaired gait, Trendelenburg lurch, subluxation, or dislocation of the hip replacement. Even when union of the trochanter occurs, the patient may still have problems. Trochanteric pain and bursitis may be related to a prominent trochanter or to irritating hardware. Fraying and breakage of hardware can lead not only to pain, but also to wear and the need for early revision.

Though Surgeons may adopt any approach to the hip joint in which they are familiar or trained, this modification may be helpful when the greater trochanter is intact in cases when treating a dislocated hip joint, when the blame for the dislocation may be avoided on the posterior approach to the hip joint.

2. References

1. Iyer KM. Technical note on Modified Posterior Approach to the Hip Joint. *Journal of Orthopaedic Case Reports*. 2015; 5(1):69-72.
2. Iyer KM. Guest Editorial for the *Journal of Medical Thesis*. 2015; 3(1):3-3.
3. *Modified Posterior Approach to the Hip Joint*. Notion Press (Chennai, India), 2015.
4. A New Posterior Approach to the Hip Joint – K. Mohan Iyer, *Injury*, 1981; 13:76-80.
5. Experience with Thompson's prosthesis using the New Posterior Approach – K. Mohan Iyer, M.A. Shatwell and M.A. Elloy, *Injury*, 1982; 14:243-244.
6. Incidence Of Piriformis Tendon Preservation On The Dislocation Rate Of Total Hip Replacement Following The Posterior Approach, by Charbel D. Moussallem, Fadi A. HOYEK and Jean-Claude F. LAHOUD in the *Lebanese Medical Journal*. 2012; 60(1):19.
7. HIP JOINT (Under Publication by Pan Stanford Publishing)
8. Mark B. Coventry, the Year Book of Orthopaedics, 1982, 371-373.
9. Rheumatoid Arthritis Surgical Society-Clinical Experience with the Iyer modification of the Posterior Approach to the Hip: F.H. Beddow and C.Tulloch, *J. Bone Joint Surg (BR)* 1990; 73B(II):164-165.
10. Experience with modified Posterior Approach to the Hip Joint. A Technical note: Shaw J.A: *J Arthroplasty*. 1991; 6(1):11-18.
11. *Campbell's Operative Orthopaedics*, S. Terry Canale Ninth Edition, 1992; 1(140):387-466.
12. Callaghan, Rosenberg, Rubash. *The Adult Hip* (Lippincott-Raven), 1998; 1:700-701, 718.
13. Failure of Reinserted Short External Rotator Muscles after Total Hip Arthroplasty-Thomas Stahelin, P. Vienne and O. Hershe *The Journal of Arthroplasty*. 2002; 17(5):604-607.
14. Deepa Iyer. The Orthopaedic Enigma: A Simplified Classification. *The Internet Journal of Orthopaedic Surgery*. 2006, 3(2).
15. Cofield Robert H. Personal Communication, 2010.
16. Primary hip arthroplasty through a limited posterior trochanteric osteotomy-Jaoquin Sanchez- Sotelo, John Gipple, Daniel Berry, Charles Rowland, Robert Cofield *Acta Orthop Belg.*, 2005; 71:548-554.
17. Daniel Berry J. Personal Communication, 2015.
18. Charnley J. The long-term results of low-friction arthroplasty of the hip performed as a primary intervention. *J Bone Joint Surg Br*. 1972; 54:61.