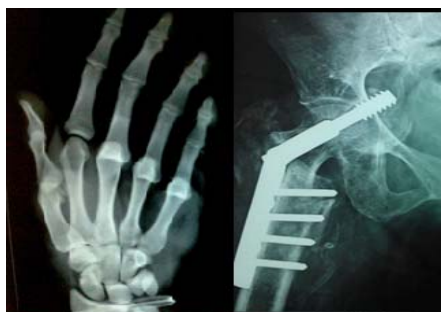



## International Journal of Orthopaedics Sciences

ISSN: 2395-1958  
IJOS 2016; 2(1): 10-14  
© 2016 IJOS  
www.orthopaper.com  
Received: 09-11-2015  
Accepted: 12-12-2015

**Dr. Faisal Younis Shah**  
Junior Resident, Government  
Medical College, Srinagar,  
MBBS 318 Mustafabad, Gousia  
Colony, Bemina, Srinagar,  
Jammu and Kashmir, India,  
190018

**Dr. Faizan Younus Shah**  
Junior Resident, Government  
Medical College, Srinagar,  
MBBS 318 Mustafabad, Gousia  
Colony, Bemina, Srinagar,  
Jammu and Kashmir, India,  
190018

**Dr. Shahid Bhat**  
Junior Resident, Government  
Medical College, Srinagar,  
MBBS Tattoo ground,  
Batamaloo, Srinagar, Jammu  
and Kashmir, India, 190018

### Correspondence

**Dr. Faisal Younis Shah**  
Junior Resident, Government  
Medical College, Srinagar,  
MBBS 318 Mustafabad, Gousia  
Colony, Bemina, Srinagar,  
Jammu and Kashmir, India,  
190018

## Hemophilic pseudotumors: Natural history and a case report of pseudotumor with femur fracture and swan-neck deformity

**Dr. Faisal Younis Shah, Dr. Faizan Younus Shah, Dr. Shahid Bhat**

### Abstract

**Introduction:** A haemophilic pseudotumor is an encapsulated, chronic, slowly expanding hematoma, usually involving the musculoskeletal system. Pseudotumors cause pressure erosion of adjacent bone and other pressure effects. We present a case report of neglected pseudotumors and everything that can go wrong, complicating management so much that we were left with amputation as the only option. We present review of literature and natural history of hemophilic pseudotumors, which will explore all the relevant data on the clinical presentation, diagnosis and especially management of this condition. We also present association of haemophilia with dynamic swan neck deformity of both hands, which is first of its kind report.

**Case presentation:** We present case report of a 70 year old Male patient with two massive pseudotumor and a femur fractures. The patients case was complicated by presence of severe joint contractures, hepatitis C and other problems.

**Conclusion:** Hemophilia is a devastating disease; it is even more devastating if a poor man has it. No rule of thumb and no standard treatment protocol exists for management of pseudotumors. Therapy for haemophilic pseudotumor should be selected on a case-by-case basis along with the full involvement of a hemotologist. In severe and neglected cases like ours, often amputation remains the only option, and in developing countries sometimes even this option is not available to the patient.

**Keywords:** Hemophilic Pseudotumors, Pseudotumor, Femur Fracture, Swan-Neck Deformity

### Introduction

Hemophilia A is an X-linked clotting disorder caused by the deficiency of factor VIII. Hemophilia manifests as a wide spectrum of symptoms ranging from excessive bleeding after trauma to spontaneous hematomas and hemarthrosis and arthropathies. Musculoskeletal involvement includes, Muscle Hematomas, Spontaneous recurrent intra-articular hemorrhages. Intra-articular blood results in severe, acute pain, and flexion contractures. If untreated, they will eventually become fixed contractures. Contractures may lead to joint subluxations and dislocations. Hemophilic arthropathy is the hallmark of haemophilia. About 90% of people with severe hemophilia experience chronic degenerative changes (hemophilic arthropathy) by the second or third decade of life. Musculoskeletal complications also include Ankylosis and Pseudotumors<sup>[1]</sup>.

Circulating levels of factor VIII are closely related to the severity and frequency of the bleeding. Hemophilia is classified as severe when the factor-VIII level is <1%, moderate when it is between 1% and 5%, and mild when it is between 5% and 25%. Spontaneous and severe bleeding into joints and muscles is a feature of severe haemophilia<sup>[2]</sup>.

A haemophilic pseudotumor is one of the late and rare complications of hemophilia having been observed in only 1% - 2% of patients with severe disease<sup>[3]</sup>.

The haemophilic pseudotumor was first described by Starker in 1918 who described the entity in the femur of a 14 year old boy.

It is an encapsulated, chronic, slowly expanding hematoma, with blood products in various stages of evolution<sup>[3]</sup>.

The majority of all reported haemophilic pseudotumors involve the musculoskeletal system. Pseudotumors usually results from repetitive bleeding in soft tissues (often intramuscular) but occasionally also occur in bone or in a subperiosteal location. Inadequate resorption of extravasated blood results in an encapsulated area of clotted blood and necrosed tissue.

Pseudotumors that occur in muscles expand over time to cause severe pressure erosion of adjacent bone and other mass effects [4].

The bones most commonly affected are the ones most susceptible to trauma i.e. femur, pelvis, tibia and small bones of the hand in decreasing order of frequency [5].

Before factor VIII was available, prognosis of pseudotumors was poor, with a mortality up to 50% [6]. With introduction of factor VIII, pseudotumors have also become rarer, but in developing countries like India, where factor VIII isn't freely available and patients cannot afford it, pseudotumors are still encountered.

**Clinical Presentation** [3, 4]

*Patients usually present with*

- Painless palpable masses or with
- Painful crises due to episodic acute bleeding into the tumor.
- With soft-tissue progression of a pseudotumor, there may be profound loss of function of the involved extremity.

*Most of the morbidity from pseudotumors is due to their compressive effect which can lead to*

- Bone destruction, muscle necrosis.
- Pseudotumor can perforate through the skin or into adjacent organs, and can lead to abscess and fistula formation,
- Compressing nerves leading to numbness, weakness, and neuralgia.
- Pathologic fractures can occur due to bone destruction and resorption of bone and
- Erosion into an artery can occur.
- In rare cases, rupture of a pseudotumor can cause life threatening exsanguinations.

*Till a pseudotumor develops, patient have usually also developed other orthopedic complications of hemophilia like joint contractures, arthritis and ankylosis, making management even more complicated.*

*Also, a pseudotumor distorts natural anatomy thus increasing the likelihood of injury during surgery.*

**Imaging:** [7]

On Xrays, hemosiderin deposits within the cyst may result in a dense appearance, mimicking other benign or malignant tumors or infectious processes.

CT scans help to differentiate pseudotumor from other masses. CT also shows the size and extent of the tumor, presence of daughter cysts and compression of the adjacent tissues in planning surgery.

MRI and Ultrasonography can also be used.

Biopsy or Aspiration of a pseudotumor is absolutely contraindicated.

**Case Presentation**

Our patient is a 70 year old male who was admitted on 4th May 2015 in our hospital. The patient is a shopkeeper by occupation. He is happily married with nine issues. He has no known allergies. There is no known significant family history. The patient has been smoking 10 cigarettes per day since his teens. The patient has no other addictions.

The patient gives a history of recurrent episodes of joint swellings and pains since his childhood. The pain and swelling used to be insidious in onset and usually lasted for 20-25 days and then spontaneously resolve. Frequency of these episodes was extremely variable. But with each episode, there was increasing joint stiffness and joint deformity.

The patient is hypertensive on Amlodipine 5mg and Atenolol 50mg OD. The patient also suffers from benign hypertrophy of prostate for which the patient is taking Flavoxate 200mg BD, Tamsulosin 0.4mg OD and Dutasteride 0.5mg OD. The patient suffers from chronic kidney disease of unknown duration for which he is not on any treatment. In 2011, patient was operated for Pterygium in Right Eye.

In 1982 (age around 37 years at that time), haemophilia A was diagnosed. After which the patient was managed with FFP which was given to him whenever he had an acute episode.

4 years back with the help of NGOs the patient was put on Factor VIII, the patient received the drug whenever he used to get joint pains or stiffness. The patient reports significant improvement in painful episodes since the introduction of factor VIII.

On 22nd Feb 2013 the patient had an episode of hemorrhagic stroke in putamen region with Right Hemiplegia and aphasia for which he was admitted for 7 days. Though the neurological status of patient has improved since then and the patient is talking, but since the episode the patient has been non-Ambulatory.

In April 2013, patient was diagnosed with Retroperitoneal hematoma, and was managed conservatively.

1 year back the patient was diagnosed with hepatitis C, but the patient doesn't give a history of jaundice and he is not taking any treatment for hepatitis C.

There is no other medical history.

The patient complains of swelling in Right knee for 4 years. The swelling has gradually increased in size. There is no history of pain in this swelling, no history of any sinuses or discharge. There is also no history of fever. There is no history of similar swelling of any other joint. However the patient has developed a similar mass on anterior aspect of L) thigh during the same period.

On 26th April 2015, the patient developed pain in Right Knee, over the next few days the swelling in Right knee increased to double its size. There is no history of trauma preceding this episode.

**On Examination**

General examination revealed no abnormalities.

In whatever neurological examination was possible at ankles and toes, patient had grade 5 power, and normal sensations.

Local examination revealed, restricted range of motion and fixed deformities in shoulders, elbows, wrists, and first metacarpophalangeal joints. But the problem was more on right side than on left side.

**Table 1:** Range of motion in joints of upper limb.

Upper limb Joint	Range of Motion	R)	L)
SHOULDER	Flexion	100°	150°
	Extension	30°	30°
	Abduction	70°	80°
	Inter. Rotation	90°	90°
	Exter. Rotation	0°	0°
ELBOW	Flexion	45° -120°	20° -140°
	Supination	0°	60°
	Pronation	90°	90°
WRIST	Flexion	50	90°
	Extension	20°	45°
	Rad/Ulnar Deviation	20° /30°	20° /30°
THUMB: MP Jt	Flexion	50° -70°	0° -70°
	IP Jt	Flexion	0° -90°

FINGERS showed bilateral Dynamic Swan Neck Deformity, right side more than left side. The deformity was correctable and the finger joints were supple.

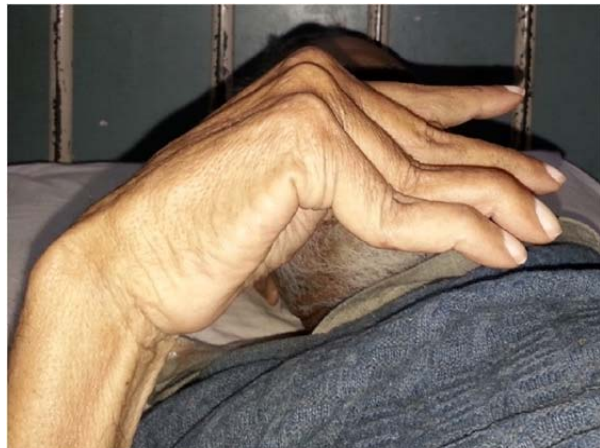

Fig 1: Swan neck deformity.

In the lower limbs there was severe bilateral wasting. Only Left hip and knee could be assessed because of fracture in right limb. Examination revealed severe loss of range of motion. Both ankles also showed stiffness.

Table 2: Range of motion in joints of lower limb.

Lower limb Joint	Range of Motion	R)	L)
HIP	Flexion	-	30° -40°
	Extension	-	0°
	Abduction	-	0°
	Adduction	-	0°
KNEE	Flexion	-	50° -60°
	Extension	-	0°
ANKLE	Plantar Flexion	40° -60°	40° -60°
	Dorsi Flexion	0°	0°

R) Knee: 30x28x15cm, Hyperpigmented, doughy firm, very Tender, Non-Pulsatile swelling with normal surface Temperature and no Sinus, Scars or Discharge were seen.

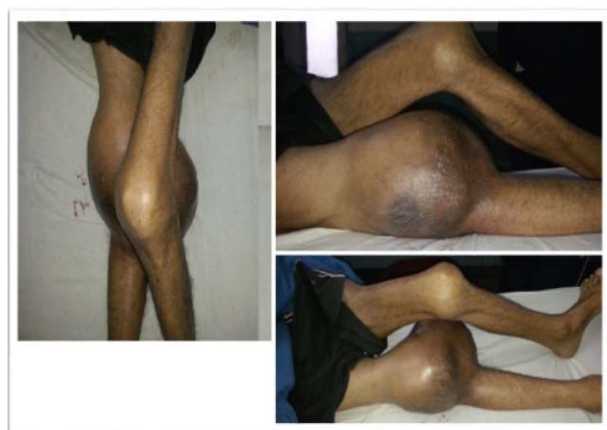

Fig 2: Pseudotumor of right knee.

L) Thigh: Swelling on anterior aspect, 15x7x5cm, Bluish, Itchy, Firm, Non-Tender, Non-Pulsatile swelling with normal surface temperature and no Sinus, Scars or Discharge.

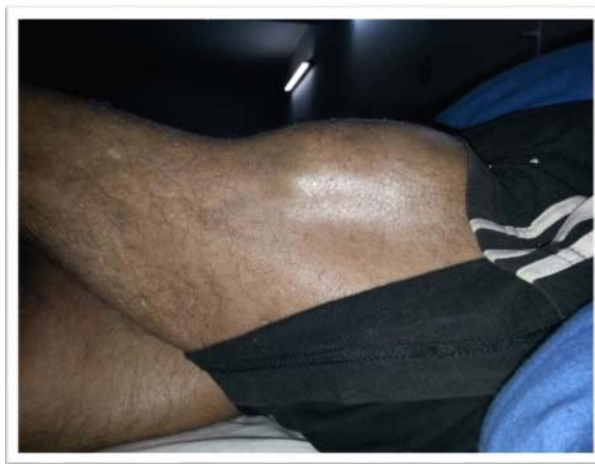

Fig 3: Pseudotumor of left thigh.

X Rays

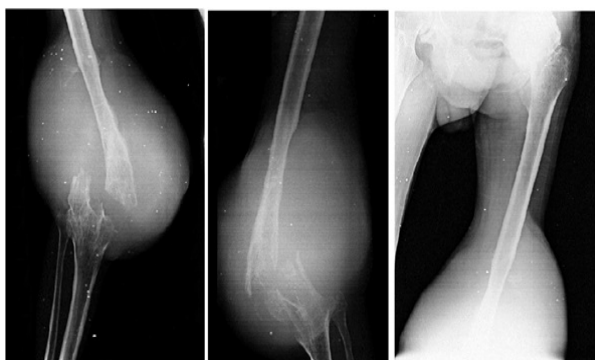


Fig 4: Xrays R) knee AP view, Xrays R) knee lat view, Xrays R) hip + femur AP view

X Rays show a dense soft tissue swelling around knee. The femur and tibia are osteopenic. There is extramedullary scalloping and thinning of distal femur cortex. Multiple lytic lesions can be seen in distal femur and proximal tibia. The distal femur and proximal tibia are deformed. There is gross destruction of the bone, knee shows severe arthropathy and ankylosis and xray shows a pathological fracture in supracondylar region of femur with intercondylar extension.

Discussion

After looking at this patient clinically and radiographically, our differential diagnoses were Chondrosarcoma, Ewing’s sarcoma, Aneurismal bone cyst, osteomyelitis, primary osteosarcomas, tuberculosis abscesses, giant cell tumors, and plasmacytomas.

But with Hemophilia A or B and a history of recurrent bleeding episodes, haemophilic pseudotumor ought to be the top differential.

This case presented a lot of challenges and reaching an ideal plan of treatment wasn’t easy.

- The patient was old and frail.
- He was Hepatitis C positive.
- He had old pseudotumor with bony involvement and complications of pseudotumor making conservative management not desirable.
- Even if conservative management were an option he was in a place and a situation with a shortage of factor VIII.
- If surgery was attempted even more factor VIII would be needed.

- He had haemophilia and many other co-morbidities making anaesthesia difficult.
- Joint contractures make anaesthesia as well as surgery difficult.
- His bones were osteopenic and deformed, knee joint was ankylosed making surgical fixation and possibility of union difficult, while the possibility of post-operative infection and other complications remained high.
- He wasn't ambulatory before the fracture, he had joint contractures and muscular weakness, so even surgery would not be very helpful.
- Radiotherapy if used will impair fracture healing.

All these factors ruled out limb saving surgery as an option. The patient was non-ambulatory even before the fracture. At that time his main problem was toilet functions, his tumor interfered with his toilet functions. So it was decided to amputate the limb.

The patient has swan neck deformity of both hands. Even after an exhaustive search we could not find in literature swan neck deformity as a musculoskeletal complication of haemophilia. The patient has swan neck deformity in fingers of both hands since 3 years, the patient developed the deformity before the stroke. Swan neck deformity can result from various causes, including palmar plate laxity at the proximal interphalangeal joint, spastic conditions such as cerebral palsy, cervical cord damage and stroke in children, rheumatoid arthritis, Ehler Danlos Syndrome, malunion of middle phalanx fractures, and mallet deformity with coexistent palmar plate laxity.

The patients clinical evaluation did not deliver any clues for the presence of rheumatoid arthritis or Ehler Danlos syndrome. The RF and Anti-CCP were also negative. History of this deformity is of only 3 years, so congenital and childhood neurological problems can be ruled out. Trauma can be ruled out because of lack of history and involvement of all the fingers.

We could not find in literature any association between swan neck deformity and haemophilia or adult stroke, and also the deformity had started before the stroke. So in this article we present swan neck deformity as a complication of Hemophilia. Given the rarity of haemophilic pseudotumors, there are no specific management strategies or consensus among the surgeons. It seems to be best to individualize therapy according to patient's condition and needs; and further decision should involve an interdisciplinary approach.

Conservative approach has been suggested as the preferred management of pseudotumors caused by recent hemorrhage. A conservative approach includes factor replacement and immobilization of the affected area.

Caviglia *et al.*<sup>[8]</sup> reported that they begin by giving factor-VIII replacement for six weeks in adults and twelve weeks in children. Regression by >50% was regarded as improvement and a positive response to conservative treatment. Regression by <50% at 12 weeks in children and by <25% at 6 weeks in adults, was considered as an indication for surgery.

Surgery has been suggested as the preferable treatment for pseudotumors that have been present for years and recent pseudotumors involving femur or pelvis in order to prevent erosion of bone, and other complications.

Bone involvement and unresponsiveness to conservative treatment are indications for surgical management<sup>[3]</sup>.

Gilbert distinguished between two types of pseudotumors:

A proximal type situated in the pelvis or femur and a distal type localized in the hand or foot. The former occurs in adults and is associated with a poor prognosis, and the latter occurs in

children and has a better prognosis. The second type usually respond better to nonoperative treatment, whereas the first type need surgical treatment, surgery has been recommended early in the management of the proximal pseudotumors femur in order to prevent erosion of bone, and other complications<sup>[9]</sup>.

Other Indications for surgery include:

- Clinical or radiographic evidence of progressive enlargement of lesion.
- Hemodynamic deterioration or
- Occurrence of a complication.

Surgery involves resection of pseudotumor.

Patients with pathological fractures according to Wolff *et al.* should be treated promptly with 25 units/kg/day of factor. Fractures of the upper limb should be maintained at this dose for 7 days; lower extremity fractures should be treated with factor for 14 days. Orthopaedic management should be the same as used for non-haemophiliacs<sup>[10]</sup>.

Patients with advanced disease and complications however might benefit with a conservative approach, on the other hand, in similar cases sometimes amputation might be the only option.

Buchowski *et al.* advised radical resection and reconstruction with a custom prosthesis as a valuable alternative to amputation in massive pseudotumors<sup>[11]</sup>.

Surgery of pseudotumors is complicated by their size, distortion of normal anatomy, involvement of adjacent neurovascular structures, associated arthropathies and contractures and the presence of daughter cysts which must be completely removed to prevent recurrence.

The main concern is the risk of uncontrollable hemorrhage.

Radiotherapy: Radiotherapy is a viable alternative where surgery is not feasible and conservative management is not effective. Radiotherapy has been shown to be a good alternative in the management of recurrent pseudotumors of the long bones.

## Conclusion

Hemophilia is a devastating disease; it is even more devastating if a poor man has it.

No rule of thumb and no standard treatment protocol exists for management of pseudotumors.

Therapy for haemophilic pseudotumor should be selected on a case-by-case basis along with the full involvement of a hemotologist. In severe and neglected cases like ours, often amputation remains the only option, and in developing countries sometimes even this option is not available to the patient.

Our case presents an association of haemophilia with dynamic swan neck deformity of hands. And in literature we couldn't find any relationship between swan neck deformity and haemophilia.

It is always best to prevent these complications rather than trying to salvage what is left later. But today 80% of countries lack the economic resources to provide for the factor VIII needs of their hemophilic patients. The need of the hour in countries like India are special inter-disciplinary clinics designed specifically to meet the needs of hemophilics, most importantly to manage the patient early so that they may not need such surgeries. And surgeons specially trained to manage hemophilic problems, and a healthy supply of factor VIII.

## References

1. Rodriguez-Merchan EC. Musculoskeletal complications of hemophilia. HSS J. 2010; 6:37-42.

2. Brower CTA. Hemophilia A, Gene Reviews, 1993.
3. Magallon M, Monteagudo J, Altisent C, Ibanez A, Rodriguez-Perez A, Riba J *et al.* Hemophilic pseudotumour: multicenter experience over a 25-year period. *Am J Hematol.* 1994; 45:103-8.
4. Jaovisidha S, Ryu KN, Hodler J, Schweitzer ME, Sartoris DJ, Resnick D. Hemophilic pseudotumor: spectrum of MR findings. *Skeletal Radiol* 1997; 26:468-474.
5. Park JS, Ryu KN. Hemophilic Pseudotumor Involving the Musculoskeletal System: Spectrum of Radiologic Findings, *American Journal of Roentgenology.* 2004; 183(1):55-61.
6. Rodriguez-Merchan EC. The haemophilic pseudotumour. *Haemophilia.* 2002; 8:12.
7. Hermann G, Yeh HC, Gilbert MS. Computed Tomography and Ultrasonography of the Hemophilic Pseudotumor and Their Use in Surgical Planning, *Skeletal Radiology,* 1986; 15(2):123-128.
8. Jaovisidha S, Ryu KN, Hodler J, Schweitzer ME, Sartoris DJ, Resnick D. Hemophilic Pseudotumor: Spectrum of MR Findings, *Skeletal Radiology,* 1997; 26(8):468-474.
9. Ahlberg AK. On the natural history of hemophilic pseudotumor. *J Bone Joint Surg Am.* 1975; 57:1133-6.
10. Wolff LJ, Lovrien EW. Management of fractures in hemophilia. *Pediatrics.* 1982; 70(3):431-6.
11. Buchowski JM1, Cascio BM, Streiff MB, Frassica FJ. Resection and reconstruction of a massive femoral hemophilic pseudotumor. *Clin Orthop Relat Res.* 2005; (430):237-42.