

E-ISSN: 2395-1958
P-ISSN: 2706-6630
IJOS 2020; 6(3): 346-349

www.orthopaper.com
Received: 12-05-2020
Accepted: 16-06-2020

Dr. Harendra Singh
Resident, Department of Orthopaedics, GMC Bhopal, Madhya Pradesh, India

Dr. Mohd. Zuber
Associate Professor, GMC Bhopal, Madhya Pradesh, India

Corresponding Author:
Dr. Harendra Singh
Resident, Department of Orthopaedics, GMC Bhopal, Madhya Pradesh, India

Olecranon fractures: Tension band wiring and complications

Dr. Harendra Singh and Dr. Mohd. Zuber

DOI: https://doi.org/10.22271/ortho.2020.v6.i3f.2221

Abstract
The tension band wiring (TBW) technique is a common treatment for the fixation of olecranon fractures. Fixing olecranon fractures by Tension-band wire technique leads to high rate of complications and re operation rate because of prominent metalwork mainly to the backing-out of the Kirschner wires. A prospective study was conducted in 70 patients with displaced olecranon fractures operated with the tension-band wiring and 65% patients were re-operated. Other complications were also reported in some of patients like stiffness and non-union. Results of our study and complications as per literature support the conclusion that TBW is challenging surgery to achieve good functional outcome.

Keywords: Olecranon fractures, complications, TBW

Introduction
Elbow is hinge type of joint with elbow flexion, extension, supination and pronation movements. Trauma to elbow leading in fracture around elbow cause decrease in range of movements around the joint.
Olecranon fractures are a diverse group of injuries, ranging from simple nondisplaced fractures to complex fracture-dislocations of the elbow joint [1]. Olecranon fractures has bimodal distribution. Olecranon fractures account around 10% of upper limb fractures in adult [3]. There are multiple classification for olecranon fracture but we are using mayo classification [4]. in our studies.
Tension band wiring (TBW) which was introduced by Weber and Vasey [8] remains the most widespread method for fracture osteosynthesis [8-10]. However, a number of complications such as infection, non-union, malunion and ulnar nerve palsy could compromise the effect of operative treatment in up to 10% of cases [11-13]. Moreover, the subcutaneous placement of K-wires and their potential migration may be responsible for local pain, secondary displacement and wound healing problems [14].
In this prospective study we will determine clinical and radiological outcome of TBW and complications post operatively.

Anatomy and Function
Anatomical boundary of olecranon start from tip of ulna till coronoid process preventing anterior dislocation of humerus. Fixing fractures of the olecranon we must remember that it is the site of insertion of the triceps muscle whose action would tend to displace a fracture, the trochlear notch of the olecranon forms a cavity in which the trochlea-part of distal humerus sits [14] thus all olecranon fractures are intraarticular injuries. The posterior process of the olecranon prevents posterior translation of the humerus and thus displacement will cause elbow instability.

Mechanism of Injury
Olecranon fractures has bimodal distribution. In young patients it is due to high energy trauma like Road traffic accidents while in elderly due to low energy falls. Mechanism of fracture is either by direct blow *usually* result in comminuted fractures or indirect blow like fall on outstretched upper extremity and *usually* results in transverse or oblique fractures [2].

Diagnosis

Patient with an olecranon fracture presents with elbow pain and swelling. Patient will be unable to extend the elbow against gravity. Thorough physical examination of the entire extremity, including look, feel, and complete neurovascular examination. If there is substantial displacement there will be a palpable defect. As the bone is subcutaneous it is necessary to look closely for skin breach. Standard AP and lateral radiographs of the elbow will be sufficient to diagnose the fracture. A true lateral radiograph of the elbow to evaluate, degree of displacement and comminution, the extent of the fracture and the degree of articular surface involvement. Closely examine the radiographs for coronoid process fracture, dislocation of the elbow, and radial head injury. Radiographs are sufficient for isolated olecranon fractures, rarely CT scan needed for comminuted fractures too.

Classification

Many classification been given for fracture olecranon but due to lack of inter observer reliability of classification systems which have been discussed in the literature [15]. Since we are using *The Mayo* Clinic classification in our study. It specifies three fracture types based on displacement and ulno-humeral joint stability. [Pic 1]

Type I - Nondisplaced (12%)

Type II - Displaced but stable (82%) and

Type III - Associated instability of the elbow (6%).

Tension-band wire (TBW) fixation is commonly employed for simple isolated stable displaced fractures of the olecranon (type IIA according to the Mayo classification) [5-7].

Other classifications are

A) *Arbeitsgemeinschaft für Osteosynthesefragen* (AO)/ Association for the Study of Internal Fixation (ASIF) classification, which is used by the Orthopaedic Trauma Association, divided these fractures into three broad categories, as follows.

- Type A - Extra-articular fractures
- Type B - Intra-articular fractures
- Type C - Intra-articular fractures of both the radial head and the olecranon.

B) *Schatzker* developed a classification with six types, as follows (types A, B, and C are intra-articular fractures)

- Type A - Simple transverse fracture
- Type B - Transverse impacted fracture
- Type C - Oblique fracture
- Type D - Comminuted fracture
- Type E - More distal fracture, which actually is extra articular
- Type F - Fracture dislocation.

C) *Colton* developed a classification with four fracture types, as follows

- Type I - Avulsion
- Type II - Oblique
- Type III - Associated dislocation of the elbow
- Type IV – Multi segmented

Methodology

Goals of treatment includes fracture reduction, stabilization of fracture, preventing blood supply and early post op mobilization to avoid stiffness. As it is a intra articular fracture nonoperative treatment seldomly advised, but may be considered for patients with a nondisplaced fracture that does not displace at 90 degree elbow flexion with intact extensor mechanism or for partial avulsions of the triceps insertion with an intact extensor mechanism. Treatment involves immobilization of the elbow in a back slab and then long arm cast in approximately 90 degree flexion for 3 weeks, followed by progressive active elbow ROM and strengthening [7]. Articular incongruity and disruption of the extensor mechanism are prime indications for fixation. Tension-band wiring [8, 16] provides stable fixation with a high union rate for simple noncomminuted transverse olecranon fractures [17, 18]. Principle of a tension-band construct is that it converts the tensile distraction force of the triceps into a compressive force at the articular surface [6].

Anesthesia - The operation was performed under general anesthesia or brachial block. Position and Tourniquet - Mid arm tourniquet was applied with patient in lateral position. Site of the surgery was thoroughly painted with iodine and spirit and draped. Exposure - Exposure of the olecranon was done by Campbell's posterolateral approach. A vertical incision was taken over the posterior aspect of the elbow about 2.5 cm proximal to olecranon, curving distally along the lateral aspect of olecranon reaching the subcutaneous border of the ulna and extending distally for about 7.5 cm distal to olecranon. Fascia was incised along the line of skin incision and fracture site was exposed. Fracture hematoma was cleared off and the fracture site was gently curettage. Accurate anatomical hairline reduction was achieved and held with either reduction clamp or long towel clip. 2 K-wires is introduced parallel from the tip of the olecranon i.e., the proximal fragment across the fracture site to the distal fragment. Periosteum was stripped from the shaft of ulna distal to fracture site and a transverse hole was drilled approximately 3 to 5cms distal to fracture site. A No.18 stainless steel malleable wire was passed through this transverse hole and crossed over the posterior surface of olecranon in a figure-of-eight manner and then passed around the protruding Kirschner wires and tightened using AO tensioner and then secured with a twist. Bend the proximal ends of the K wires 180^0 and tap the cut ends back into the proximal fragment. Accuracy of reduction was checked and stability was tested by moving the joint. Wound closed in layers and sterile dressing and compression bandage given [8, 18, 19].

Results

70 patients including 44 male and 26 female patients with average of 38.3 years were evaluated. Out of 70 cases selected for TBW 41(58.5%) were due to RTA, 23(32.9%) were due to fall and 6(8.6%) due to assault. 10(14.3%) case had oblique fracture of olecranon while rest had transverse fracture. 6 cases had associated injury of bone other than olecranon fracture, 3(4.3%) had shaft humerus fracture and 3(4.3%) had radius fracture. 10(14.3%) patient had the co-morbidity.

All patients were treated by TBW for olecranon fracture, while plating in 3 patients of fracture radius and humerus plating in other 3 patients were done.

In 12 patients (17.1%) a migration of the implants were observed. Out of 12, 8 needed revised surgery. 10 patient required intervention for delayed healing and 12 for infection. 2 patient underwent a neurolysis of the ulnar nerve. Other patients needed revisions because of severe pain, inappropriate implant positioning. So the ratio of implant migration was 17.1%, the ratio of delayed healing 14.2%, the ratio of infection 17.1%. In 40 patients (57.1%) metal removal was performed after an average of 12 months.

Table 1: Mayo Elbow Performance Score

Mean Score at 1 month	34.44
Mean Score at 3 month	48
Mean Score at 6 months	59.33
Mean Score at 12 months	70.67

Discussion

Olecranon fractures are simple intra articular fractures. Their clinical picture is obvious, orthogonal radiographs are sufficient to make the diagnosis and anatomy of fracture. It almost always involves an intra articular fracture with the exception of avulsion fracture tip of olecranon with a disruption of the extension mechanism of the elbow. Through the force of the triceps muscle, displacement of the proximal fracture fragment is the rule [20]. A commonly countered problem is intramedullary positioning of the distal part of the wires or wires crossing each other instead of being drilled parallel. Which will lead to secondary displacement of fracture fragments with intraarticular steps or gaps. When K-wires cross each other at the level of the fracture, the construct does not offer the ideal structure to convert flexion into fracture compression. Due to lower stability, secondary displacement may occur or fracture healing may be disturbed [12]. As ulna is subcutaneous bone this makes it easily accessible to the fracture site also means that the implants will be subcutaneous. It is clear that the subcutaneous site of the implants was responsible for subjective complaints and stiff elbow in many patients. Half of patient had pain at rest, functional deficit also which was improved on implant removal. It proves metal removal after fracture healing improves functional deficit and pain. In this case series, it was performed in 45 of the patients after an average of 12 months. After 1 year.

In our study, only the classification system of the Mayo-clinic had a predictive value for elbow function, elbow instability is part of the classification. In the Mayo classification, unstable lesions belong to Type III. The additional fracture of the proximal radius is an indirect sign of instability, and is combined with more complex fracture patterns of the olecranon.

With his study we can conclude that fracture pattern of an olecranon is not decisive for elbow function after open reduction and internal fixation.

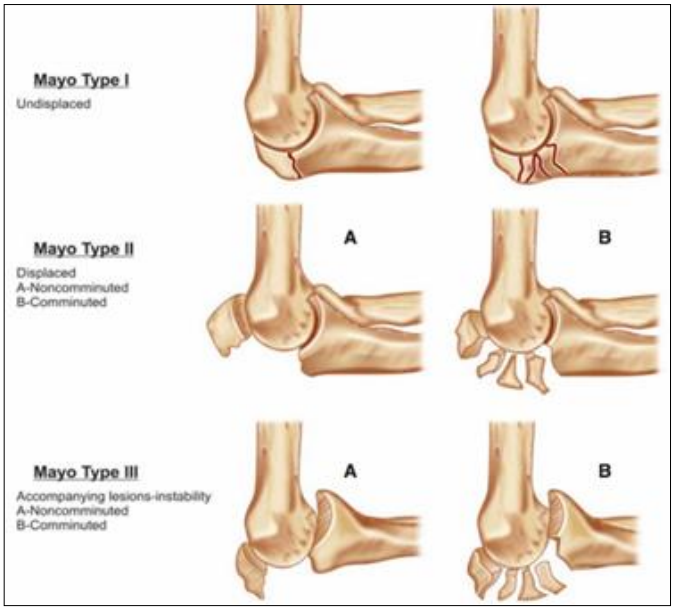

Pic 1: Mayo Classification

Pic 2: 44 Y/M with Mayo type IIB olecranon fracture AP and lateral X rays and TBW(c) which resulted in 30 degree extension deficit 12 month post operatively

Variable	Definition	No. of points
Pain (max. 45 points)	None	45
	Mild	30
	Moderate	15
	Severe	0
Range of motion (max. 20 points)	Arc >100°	20
	Arc 50–100°	15
	Arc <50°	5
Stability (max. 10 points)	Stable	10
	Moderately unstable	5
	Grossly unstable	0
Function (max. 25 points)	Able to comb hair	5
	Able to feed oneself	5
	Able to perform personal hygiene tasks	5
	Able to put on shirt	5
	Able to put on shoes	5

Pic 3: Mayo elbow performance index

Conclusion

As the olecranon bone is subcutaneous and so is the implant used. As complexity of fracture increases stability of fixation with TBW decreases. There is a obvious relationship between fracture pattern and suboptimal osteosynthesis and development of arthrosis. But there is no correlation found between suboptimal osteosynthesis and implant loosening. Olecranon fractures, if they are associated with ipsilateral upper extremity fractures like in our study then functional outcome is below average than the fractures with no other lesion. Proximal radius fractures are prime reason for elbow instability. Mayo elbow performance index can be used as predictive tool for functional outcome of olecranon fractures.

References

1. Rouleau DM, Sandman E, van Riet R, Galatz LM. Management of fractures of the proximal ulna. J Am Acad Orthop Surg. 2013; 21(3):149-60.
2. Bucholz RW, Heckman JD, Court-Brown CM, Tornetta P, Koval KJ. Rockwood and Green's Fractures in Adults: Rockwood, Green, and Wilkins' Fractures, 2 Volume Set. Sixth Edition. Lippincott Williams & Wilkins, 2005.
3. Anderson ML, Larson AN, Merten SM, Steinmann SP. Congruent elbow plate fixation of olecranon fractures. J Orthop Trauma. 2007; 21(6):386-93.
4. Laura Wiegand MD, Joseph Bernstein MD, Jaimo Ahn MD, PhD. Fractures in Brief: Olecranon Fracture. Clin Orthop Relat Res. 2012; 470:3637–3641. DOI 10.1007/s11999-012-2393.
5. Chalidis BE, Sachinis NC, Samoladas EP, Dimitriou CG, Pournaras JD. Is tension band wiring technique the “gold standard for the treatment of olecranon fractures? A long term functional outcome study. J Orthop Surg Res. 2008; 3:9.
6. Morrey BF. Current concepts in the treatment of fractures of the radial head, the olecranon, and the coronoid. Instr Course Lect. 1995; 44:175-85.
7. Ring D. Elbow fractures and dislocations. In: Bucholz RW, Court-Brown CM, Heckman JD, Tornetta P, III, editors. Rockwood and Green’s fractures in adults. 7th ed

Philadelphia: Lippincott Williams & Wilkins, 2010, 905-44.
8. Weber BG, Vasey H. [Osteosynthesis in Olecranon Fractures.] Z Unfallmed Berufskr. 1963; 56:90–96.
9. Karlsson MK, Hasserius R, Karlsson C, Besjakov J, Josefsson PO. Fractures of the olecranon: a 15- to 25-year follow up of 73 patients. Clin Orthop Relat Res, 2002, 205–212. doi: 10.1097/00003086-200210000-00030.]
10. Rommens PM, Kuchle R, Schneider RU, Reuter M. Olecranon fractures in adults: factors influencing outcome. Injury. 2004; 35:1149–1157. doi: 10.1016/j.injury.2003.12.002.
11. Villanueva P, Osorio F, Commessatti M, Sanchez-Sotelo J. Tension-band wiring for olecranon fractures: analysis of risk factors for failure. J Shoulder Elbow Surg. 2006; 15:351–356. doi: 10.1016/j.jse.2005.08.002.
12. Jensen CM, Olsen BB. Drawbacks of traction-absorbing wiring (TAW) in displaced fractures of the olecranon. Injury. 1986; 17:174–175. doi: 10.1016/0020-1383(86)90326-8.
13. Macko D, Szabo RM. Complications of tension-band wiring of olecranon fractures. J Bone Joint Surg Am. 1985; 67:1396–1401.
14. Romero JM, Miran A, Jensen CH. Complications and re-operation rate after tension-band wiring of olecranon fractures. J Orthop Sci. 2000; 5:318–320. doi: 10.1007/s007760070036.
15. Audige L, Bhandari M, Kellam J. How reliable are reliability studies of fracture classifications? A systematic review of their methodologies. Acta Orthop Scand. 2004; 75:184–194.
16. Newman SD, Mauffrey C, Krikler S. Olecranon fractures. Injury. 2009; 40:575–581.
17. Finsen V, Lingaas PS, Storro S. AO tension-band osteosynthesis of displaced olecranon fractures. Orthopedics. 2000; 23:1069–1072.
18. Wolfgang G, Burke F, Bush D, Parenti J, Perry J, LaFollette B *et al*. Surgical treatment of displaced olecranon fractures by tension band wiring technique. Clin Orthop Relat Res. 1987; 224:192–204.
19. Joiman SD, Mauffrey C, Krikler S. Olecranon fractures. Injury. 2009; 40(6):575-81.
20. Mommsen U, Holzrichter D. Traumatologie des Schultergu ¨rtels und obere Extremita ¨t. In: Schumpelick V, Bleese NM, Mommsen U, editors. Chirurgie, 4th ed. Stuttgart: Ferdinand Enke Verlag, 1999, 1203-28.
21. Joshi RP. The Hastings experience of the Attenborough springs and Rush nail for fixation of olecranon fractures. Injury. 1997; 28:455-8.
22. Larsen E, Jensen CM. Tension-band wiring of olecranon fractures with non-sliding pins. Report of 20 cases. Acta Orthop Scand. 1991; 62:360-2.