

E-ISSN: 2395-1958
P-ISSN: 2706-6630
IJOS 2020; 6(3): 149-152

www.orthopaper.com
Received: 09-05-2020
Accepted: 14-06-2020

Dr. Lokesh Kumar Yogi
Department of Orthopaedics, GMCH Aurangabad, Maharashtra, India

Dr. Gagandeep Mahi
Department of Orthopaedics, GMCH Aurangabad, Maharashtra, India

Dr. Milind Atmaram Lokhande
Department of Orthopaedics, GMCH Aurangabad, Maharashtra, India

Corresponding Author:
Dr. Milind Atmaram Lokhande
Department of Orthopaedics, GMCH Aurangabad, Maharashtra, India

Evaluation of short term complications following use of retrograde intramedullary femoral interlocking nail for fractures of distal femur

Dr. Lokesh Kumar Yogi, Dr. Gagandeep Mahi and Dr. Milind Atmaram Lokhande

DOI: https://doi.org/10.22271/ortho.2020.v6.i3c.2194

Abstract
Background: Supracondylar fractures of femur constitute 6-7% of all femoral fractures. In elderly patients, they are invariably low-energy fractures predisposed by osteoporosis. Aim of this article is to assess the complications of retrograde intramedullary femoral interlocking nail (RIFIN).
Materials and methods: The study was conducted at a tertiary health care centre, cases were selected from November 2017 to December 2018. This prospective study was performed on 37 patients with supracondylar femoral fractures (AO type A and C).
Results: Complications in our study included knee stiffness in 8 patients, anterior knee pain in 6 patients, shortening (1-2cm) in 3 patients, 3 patients had implant failure due to early weight bearing ambulation (one patient had distal screw back-out, one patient distal screw breakage and one patient had nail breakage), 2 patients had non-union (in which one patient had infected non-union), one patient had peri-implant fracture and one patient had protruding nail.
Conclusion: RIFIN is mostly limited for use in extra-articular distal femoral fractures. Although it has a high incidence of complications, it requires a greater amount of attention to the operative technique and patient selection in order to prevent these complications.

Keywords: RIFIN, Distal femur fractures, Complications.

Introduction

Distal fracture of the femur comprise roughly 6-7% of all femoral fractures [1]. The incidence of distal femur fractures is around 37/100,000 patients per year [2]. Distal fractures of the shaft of the femur are usually caused by high energy trauma in the adult and low energy trauma in elderly [3].

Based on the common principles of the AO classification,

- Type A fractures include extra-articular fractures
- Type B fractures are partial articular fractures
- Type C fractures include complete articular fractures

The fracture types are further subdivided describing the degree of comminution and other characteristics. Further subdivision of type B fractures includes B1 (sagittal, lateral condyle), B2 (sagittal, medial condyle) and B3 (frontal, Hoffa type). Fracture type C is divided in C1 (articular simple, metaphyseal simple), C2 (articular simple, metaphyseal multifragmentary) and C3 (multifragmentary) [4].

Although their treatment evolved during the last years, distal femoral fractures still remain challenging injuries for orthopaedic surgeons, due to their high complication rate and negative impact of those complications upon the function of the lower limb. Initially, retrograde femoral nailing was developed and used forsupracondylar femur fractures [5]. Surgical indication of the application of this technique has been extended further to femoral shaft fractures, as well as intra-articular fractures, fractures involving the ipsilateral patella, and tibia or femoral neck [6]. RIFIN shows good results over plating in extra-articular distal femoral fracture but still the osteoporotic fractures were enigma. Although there was limitation of

RIFIN in the condylar fractures in coronal plane (Hoffas', B3) and some of highly comminuted intra-articular fractures (C3) could not be fixed with RIFIN [7-9]. Potential disadvantages to retrograde nailing include knee sepsis, patellofemoral pain, and synovial metallosis from the protruding nail or screw breakage [10].

Methods

The study was conducted at a tertiary health care centre, GMCH, Aurangabad. The cases were selected from a time period of November 2017 to December 2018. This prospective study was performed on 37 patients with supracondylar femoral fractures. There were 22 males and 15 females with a mean age 56 (6.7) years (range 28-78 years). Inclusion criteria were skeletally mature patients with fractures AO 33A1 to A3 and 33C1 to 33C2. Patients with 33B and 33C3 (complex intra articular) were excluded from study. Minimum follow up was 9 months and maximum follow-up was up to 14 months. All patients were given appropriate emergency management and adequate splinting of fractures was done. A complete evaluation of patient including standard trauma radiology and haematological work up was done and patients were operated as soon as patient's condition permitted.

Surgical technique

Pre-operative evaluation was done on radiographs to ascertain the length of supracondylar nail, maximum possible diameter and the lengths of interlocking bolts. The fractured leg was positioned with knee flexion of 60 degrees to facilitate nail insertion. Following infrapatellar skin incision, direct transpatellar access to the knee joint was performed. The entry point for the nail is in the axis of the medullary canal and in the intercondylar notch, just anterior and lateral to the femoral attachment of the posterior cruciate ligament, determined on image intensifier. Fracture reduction done withpull-traction at 30° angle over a radiolucent triangle. Reaming is done with a cannulated reamer passed over a guide wire (1mm above size of final nail). All the nails were locked on both the ends by bolts. Post-operatively, static quadriceps and active or assisted bedside knee mobilisation was started from the 2nd post-operative day. Postoperative weight bearing depended upon the stability of fixation and fracture pattern and was individualized for each patient. Toe touch weight bearing was started in majority of patients after 1st week of surgery. Partial weight bearing was allowed after 4 weeks, followed by complete weight bearing from 8-10th week.

Results

All patients were followed up for an average of 12 months. Clinical and radiographic evaluation demonstrated osseous healing within 16 weeks following RIFIN. Complications in our study included knee stiffness in 8 patients, anterior knee pain in 6 patients, shortening (1-2cm) in 3 patients, 3 patients had implant failure due to early weight bearing ambulation (one patient had distal screw back-out, one patient had distal screw breakage and one patient had nail breakage), 2 patients had non union (in which one patient had infected non-union), one patient had peri-implant fracture and one patient had a protruding nail (Fig.1). There were no cases of heterotropic ossification and intraoperative femoral shaft fracture in our study.

Table 1: Type of fractures based on Muller's (AO) classification system

Subtype	No. of patients (37)	Percentage (%)
A1	16	43.24
A2	9	24.32
A3	6	16.21
C1	4	10.81
C2	2	5.4

Table 2: Complication of RIFIN in our study

Complication	No. of patients (37)	Percentage (%)
Knee stiffness	8	21.62
Anterior knee pain	6	16.21
Shortening	3	8.1
Implant failure	3	8.1
Non-union	2	5.4
Peri-implant fracture	1	2.7
Protruding nail	1	2.7

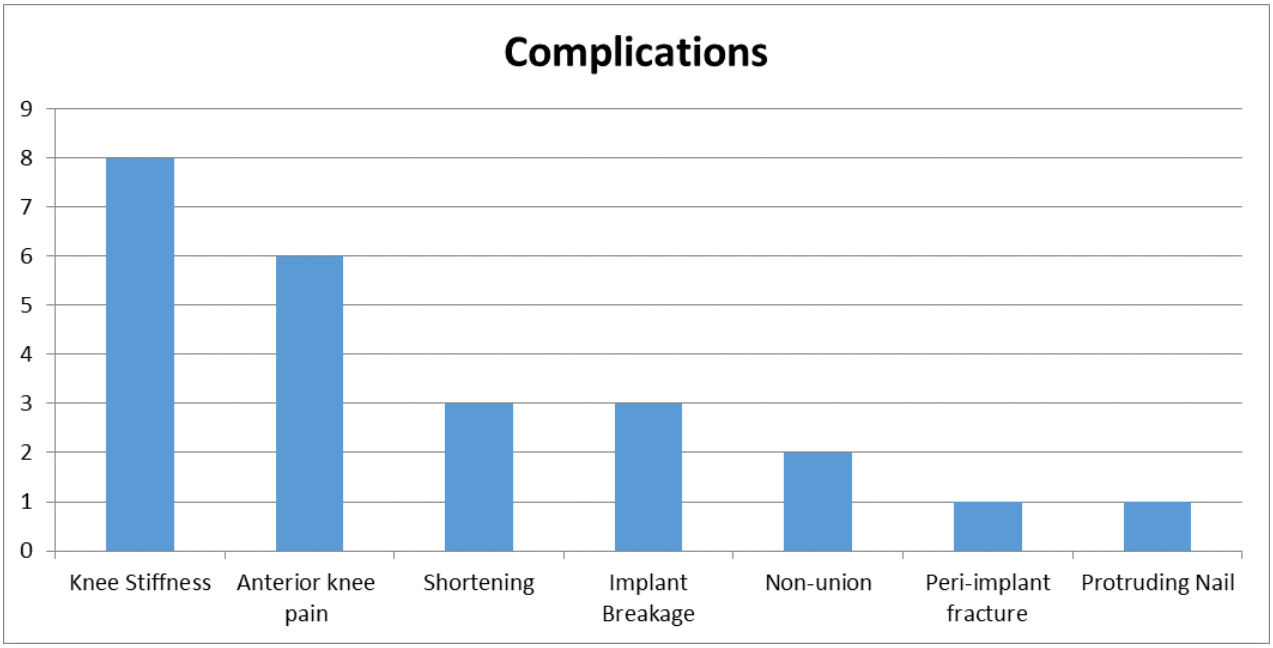

Fig 1: A bar graph representing various complications occurring in patients treated with RIFIN with their frequency

Fig 2: A case of peri-implant fracture of proximal femur with uniting supracondylar femur fracture.

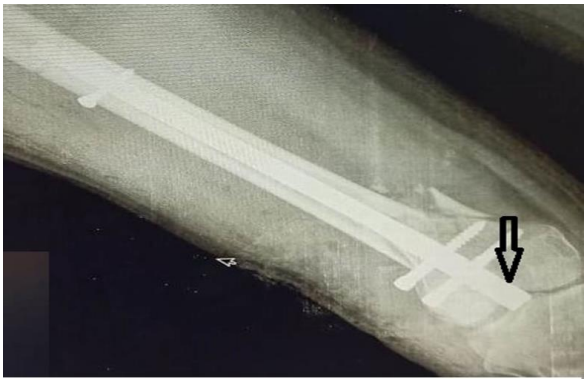

Fig 3: Intra-articular protrusion of nail

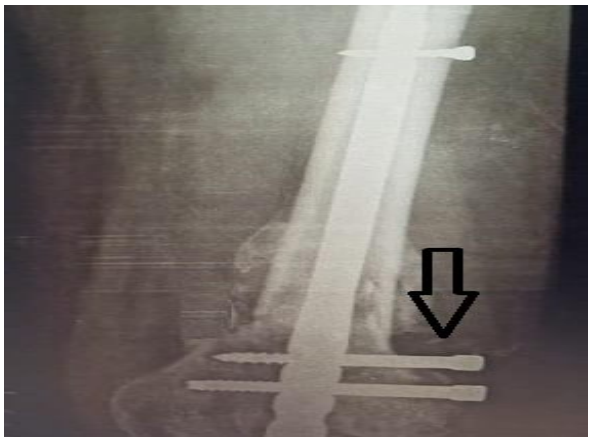

Fig 4: Implant Failure (Screwbackout)

Fig 5: Infected Non-union post implant removal

Discussion

The indications for retrograde nailing are classically extra-articular fractures or simple intra-articular fractures with little or no displacement [11]. Protection of soft tissue envelope due to the minimally invasive approach and closed reduction techniques is better with use of RIFIN [12].

Aim of this study was to assess the complications following retrograde nail in supracondylar femur fractures. In our series, predominant indications for osteosynthesis using the retrograde nail included distal femur fractures AO type A1, A2, A3, C1 and C2.The advent of nailing has reduced the blood loss during surgery and operative time needed for the surgery. Early post-operative mobilisation is possible as compared to distal femur plates. Stability is limited if small diameter and short nails are inserted [13].

Complications of the nailing technique may be due to a lack of alignment control, knee stiffness, implant breakage, intra-articular insertion, intra-articular distribution of reaming debris, heterotropic ossification, retrocurvation, non-union, shortening and perforation of joint cartilage [14]. The main complications following RIFIN in our study included knee stiffness in 8 patients which was managed with closely monitored physiotherapy with continuous passive motion (CPM) machine, anterior knee pain was noted in 6 patients and they were treated with analgesics, shortening (1-2cm) was noted in 3 patients, 3 patients had implant failure due to early weight bearing ambulation (one patient had distal screw back-out, one patient distal screw breakage and one patient had nail breakage), 2 patients had non-union (in which one patient had infected non-union), one patient had post-operative peri-implant fracture after a trivial fall and one patient had protruding nail.

Many studies suggest that knee stiffness occurs commonly, with some loss of flexion in up to 48% and a range of motion <90 degree in up to 15%.[15] Other problems include anterior knee pain in 22%, locking screws missing the nail up to 12%, locking screw breakage in up to 8%, implant failure up to 6%, loss of reduction in 7%, nail protrusion into knee in 2% andfemoral shaft fracture during reaming 2%. [15, 16, 17, 18, 19]

Retrograde femoral nailing is an effective method of femoral shaft fracture fixation in polytrauma patients. The healing rate of femoral shaft fractures fixed with a retrograde nail is the same regardless of location of fracture, age, sex, or comminution. Prevention of tip of nail lying into the knee and early physical therapy are important to prevent arthrofibrosis of knee [20].

Number of intra-operative complications can be minimised by right alignment of fracture fragments, diligent selection of correct entry point under adequate fluoroscopic guidance and proper selection of nail diameter and length.

Conclusion

As per general consensus, retrograde intramedullary nail fixation is an effective method for treating fractures of distal femur and does not interfere significantly with the knee function postoperatively with negligible complications. In our study however, 6 out 37 patients had significant complications which subsequently needed revision surgery. A larger number of patients are required in the study group with comparison to other modalities of treatment to validate whether there are more complications occurring merely with the use of RIFIN or they can be avoided by improving intraoperative techniques, nail length/size or patient selection.

Acknowledgements

We would like to extend our token of appreciation towards our Professor and Head of the Department Dr. Chandrakant R. Thorat sir who has relentlessly worked for the betterment of our department and thank him for his everlasting support in all our endeavours.

References

1. Arneson TJ, Melton LJ III, Lewallen DG, O'Fallon WM. Epidemiology of diaphyseal and distal femoral fractures in Rochester, Minnesota, Clin Orthop. 1965–1984; 234:188-194.
2. Christian Hierholzer, Christian von Rüden, Tobias Pötzel, Alexander Woltmann, Volker Bühren. Outcome analysis of retrograde nailing and less invasive stabilization system in distal femoral fractures: A retrospective analysis. Indian J Orthop. 2011; 45(3):243-250.
3. Florian Fankhauser *et al*. Minimal-invasive treatment of distal femoral fractures with the LISS (Less Invasive Stabilization System) A prospective study of 30 fractures with a follow up of 20 months. Acta Orthop Scand. 2004; 75(1):56-60.
4. Neer CS, Grantham SA, Shelton ML. Supracondylar fracture of the adult femur. A study of one hundred and ten cases. J Bone Joint Surg Am. 1967; 49:591-613.
5. Green SA. Distal intramedullary fixation of supracondylar fractures of the femur. Tech Orthop. 1988; 3:71-6.
6. Lei Tan, MD *et al*. Patellar tendon ossification after retrograde intramedullary nailing for distal femoral shaft fracture (A case report and review of the literature). Tan *et al*. Medicine. 2017; 96:47.
7. Lucas SE, Seligson D Henery SL. Intramedullary supracondylar nailing of femoral fractures A preliminary report of GHS supracondylar nail. Clin Orthop. 1993; 296:200-6.
8. Janjing HM, Stockman B, Van Damme G, Rommens P. Retrograde intramedullary nailing prospective experience in patients older than 65 years. J Orthop Trauma. 1998; 12:330-3.
9. Leung KS, Shen WY, So WS, Mui LT, Grosse A. Intramedullary nailing for supracondylar or intercondylar fractures of distal part of femur. JBJS. 1991; 73:332-40.
10. Handolin L, Pajarinen J, Lindahl J, Hirvensalo E. Retrograde intramedullary nailing in distal femoral fractures-result in a series of 46 consecutive operations. Injury. 2004; 35:517-522.
11. Ehlinger M, Ducrot G, Adam P, Bonnomet F. Distal femur fractures. Surgical techniques and a review of the literature. Orthopaedics & Traumatology: Surgery & Research. 2013; 99:353-360.
12. Zlowodzki M, Bhandari M, Marek DJ, Cole PA, Kregor PJ. Operative treatment of acute distal femur fractures: systematic review of 2 comparative studies and 45 case series (1989 to 2005) J Orthop Trauma. 2006; 20:366-71.
13. Zlowodzki M, Williamson S, Cole PA, Zardiackas LD, Kregor PJ. Biomechanical evaluation of the less invasive stabilization system, angled blade plate, and retrograde intramedullary nail for the internal fixation of distal femur fractures. J Orthop Trauma. 2004; 18:494-502.
14. Carmack DB, Moed BR, Kingston C, Zmurko M, Watson JT, Richardson M. Identification of optimal intercondylar starting point for retrograde femoral nailing: An anatomical study. J Trauma. 2003; 55(4):692-695.
15. Iannacone WM, Bennett FS, Delong WG, *et al*. Initial experience with the treatment of supracondylar femoral fractures using the supracondylar intramedullary nail: a preliminary report. J Orthop Trauma. 1994; 8:322-7.
16. Janzing HM, Stockman B, Van Damme G, *et al*. The retrograde intramedullary supracondylar nail: an alternative in the treatment of distal femoral fractures in the elderly? Arch Orthop Trauma Surg. 1998; 118:92-5.
17. Forster MC, Komarsamy B, Davison JN. Distal femoral fractures: A review of fixation methods. Injury, Int. J. Care Injured. 2006; 37:97-108.
18. Raju KP, Madhuchandra P, Pawankumar KM, Shrinidhi IS. Functional outcome of type and type c supracondylar fractures of femur treated by retrograde intramedullary nailing technique.International Journal of Orthopaedics Sciences. 2017; 3(4):769-775.
19. Sagar Shah, Pingal Desai, Varatharaj Mounasamy. Retrograde Nailing of Femoral Fractures: A Retrospective Study. Eur J Orthop Surg Traumatol. 2015; 25(6):1093-7.
20. Shah S, Desai P, Mounasamy V. Retrograde nailing of femoral fractures: a retrospective study. Eur J OrthopSurgTraumatol. 2015; 25(6):1093-1097. doi:10.1007/s00590-015-1658-6.