

E-ISSN: 2395-1958
P-ISSN: 2706-6630
IJOS 2020; 6(3): 06-09
© 2020 IJOS
www.orthopaper.com
Received: 05-05-2020
Accepted: 06-06-2020

Dr. S Hari Kumar
Associate Professor,
Department of Orthopedics,
MNR Medical College and
Hospital, Sangareddy,
Telangana, India

Management of proximal tibial fractures by posteromedial locking compression plate

Dr. S Hari Kumar

DOI: <https://doi.org/10.22271/ortho.2020.v6.i3a.2167>

Abstract

Management of tibial plateau fractures aims to restore normal knee functionality by near normal anatomical restoration of the articulating surfaces, thereby maintaining the mechanical axis and restoring ligamentous stability. Plate fixation is important when a medial plateau is involved in proximal tibial fractures. The present study was designed to assess the management of medial condylar fractures of proximal tibia treated by posteromedial locking compression plate. A total of 30 cases with Schatzker type IV-VI fractures to the proximal tibia, who followed up for clinic radiological evaluation, between age group 20-60 years were recruited. Clinical examination and radiological investigations were performed to review the fractures. The fractures to the medial condyle of tibia were treated by posteromedial approach. Post-operative care has been initiated with physical therapy in the form of quadriceps exercises. The postoperative follow up was continued at the end of one month, three months and six months and outcomes were recorded by using Lysholm knee score. According to Schatzker type of fractures 46.6% had type IV, 33.3% had type V and 20% had type VI fractures. Majority cases had fractures due to road traffic accidents (70%). Postoperative fracture outcome showed excellent outcome in 78% cases, good results in 16%, fair results in 6% and none of the case had a poor outcome. In postoperative complications, 80% cases were recovered without complications, 10% cases had superficial infection, 7% cases had knee pain, and 3% cases had knee stiffness. The posteromedial approach of tibial fracture management is safe with minimal complications. Fixation of posteromedial tibia permits quick reformation of the patient with outstanding functional outcome with minimal incidence of complication.

Keywords: Proximal tibial fractures, posteromedial locking compression plate, Lysholm knee score

Introduction

Management of tibial plateau fractures is a challenging task to orthopedic surgeon due to its controversial treatment modalities [1]. Proximal tibial fractures account 1.2% of all fractures and 8% of fractures in old age people [2, 3]. Fractures to the lateral tibial condyle are more common than the medial tibial condyle [4]. New surgical techniques and surgical methods were available in the management of these fractures. Management of tibial plateau fractures involves financial burden, prolonged of hospital stay. Plate fixation is important when medial plateau is involved in proximal tibial fractures [5, 7]. Various treatment modalities like open reduction and internal fixation with plate osteosynthesis, percutaneous screw fixation or external fixation with pin or wire fixators, closed manipulation and casting [8, 9]. The goal of treatment is the restoration of joint congruity, normal limb alignment, ligamentous stability, knee stability and a functional range of knee motion [10]. The present study was designed to assess the management of medial condylar fractures of proximal tibia treated by posteromedial locking compression plate.

Materials and Methods

The present study was conducted in the department of orthopedics, MNR Medical College and Hospital, Sangareddy from January 2018 to January 2020. A total of 30 cases with Schatzker type IV-VI fractures to the proximal tibia, who followed up for clinic radiological evaluation, between age group 20-60 years were recruited. Cases with a duration of fractures <2 weeks, with closed injuries and fractures to the medial and posterior column, were included. Cases with fractures to the lateral column, with >2 weeks old fractures were excluded.

Corresponding Author:
Dr. S Hari Kumar
Associate Professor,
Department of Orthopedics,
MNR Medical College and
Hospital, Sangareddy,
Telangana, India

Informed consent was obtained from all the cases and study protocol was approved by institutional ethics committee. Clinical examination was conducted to identify associated soft tissue injuries, neurovascular complications and compartment syndrome. Radiological investigations including AP view and Lateral view X-ray were taken which was supplemented with CT scan and MRI were reviewed to note the type of the fracture, the location and extent of articular depression, and fracture extension into the diaphysis.

Surgical procedure

Preoperatively, the tibial plateau fractures were classified according to Schatzker's classification. The fractures to the medial condyle of tibia were treated by posteromedial approach, Galla and Lobenhoffer approach. In a posteromedial approach, incision was made along the posteromedial border of the proximal tibia, between gastrocnemius and pes anserinus. Initially plates were placed on the fracture site, 3.5 cortical screw placed in the neck of the plate in the elongated combi hole. In continue, 3.5 self-tapping locking screws were placed in the shaft of plate. 1.5 K-wire was placed in the holes of head portion of the plate anther locking screws have been inserted.

Post-operative care has been initiated with physical therapy in the form of quadriceps exercises. Advised to walk with the support and advised not to bear weights till the clinical union of fractures. The postoperative follow up was continued at the end of one month, three months and six months and the outcome was recorded by using Lysholm knee score.

Results

Table 1: Details and distribution of study variables.

Parameter	Total number of cases (n=30)	
	Number	Percentage
Age (In years)		
20-30	08	26.6%
31-40	08	26.6%
41-50	10	33.3%
51-60	04	13.3%
Gender		
Male	21	70%
Female	9	30%
Schatzker type of fractures		
Schatzker type IV	14	46.6%
Schatzker type V	10	33.3%
Schatzker type VI	06	20%
Mode of injury		
Fall from height	03	10%
Road traffic accidents	21	70%
Accidental fall	05	16.6%
Others (Assault)	01	3.33%
Duration between injury and treatment (In days)		
Less than 3	23	76.6%
3-6	03	10%
7-14	04	13.3%

Table 2: Details about amount of blood loss.

Amount of blood loss	Total cases (n=30)	
	Number	Percentage
<50ml	06	20%
50-100ml	13	43.3%
>100ml	11	36.6%

Table 3: Evaluation of fracture outcome by Lysholm Knee score.

Parameters	Lysholm Knee score		
	Excellent	Good	Fair
According to age			
20-30	07	01	-
31-40	06	02	-
41-50	06	03	01
51-60	02	01	01
According to sex			
Male	15	04	02
Female	06	02	01
Schatzker type of fractures			
Schatzker type IV	13	01	-
Schatzker type V	07	03	-
Schatzker type VI	03	01	02

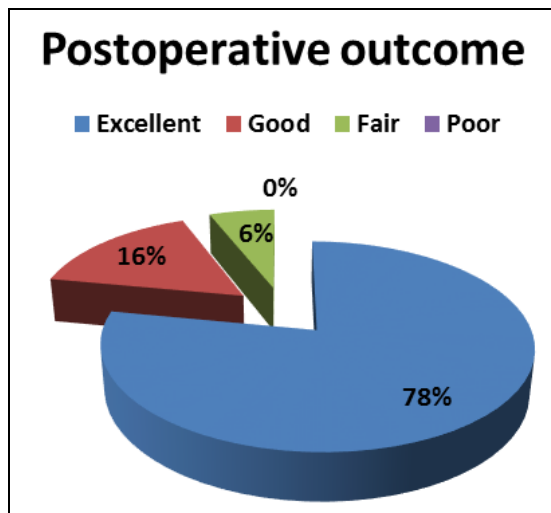


Fig 1: Details of postoperative outcome of fractures.

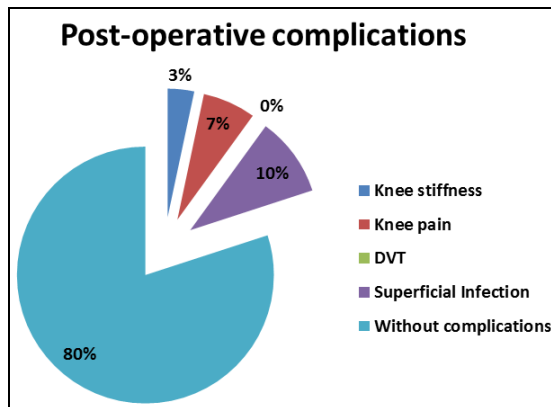


Fig 1: Postoperative associated complication with fractures.

Discussion

Tibial condylar fractures are the common intra-articular fractures occurred from direct axial compressive forces [11]. Low and high energy tibial plateau fractures show various bone and soft tissue injuries that may lead to permanent disabilities and their treatment is often challenged by severe fracture comminution [12]. This study was designed to assess the functional outcome of medial condylar fractures of proximal tibia treated by posteromedial locking compression plate. A total of 30 cases with Schatzker type IV-VI fractures to the proximal tibia, who followed up for clinic radiological evaluation, between age group 20-60 years were recruited. Majority cases were between 3rd to 4th decade (53.2%), followed by 33.3% in 41-50 years. Among the cases 70% cases were males and 30% cases were females. In a study by

Mahesh Kumar Dindivanam *et al.* the mean age of study participants was 32.27 years ^[11]. A study by Manikandan N *et al.* stated that the incidence of fractures was more in between 40-60 years of age with males more affected than females ^[13]. A study by Pradyumna Sharma *et al.* observed maximum incidence of fractures between age group 30-39 years (50%) ^[15].

According to Schatzker type of fractures 46.6% cases had Schatzker type IV fractures, 33.3% cases had Schatzker type V fractures and 20% cases had Schatzker type VI fractures. In a study by Mahesh Kumar Dindivanam *et al.* found that 53.3% fractures were Schatzker type V and 46.7% fractures were Schatzker type VI ^[11]. A study by Gavhale SV *et al.* included one case with Schatzker type I, 8 cases with Schatzker type II, 3 cases with Schatzker type IV, 6 cases with Schatzker type V and 12 cases with Schatzker type VI ^[12]. A study by Thiruvengita Prasad G *et al.* included 20 Schatzker type V fractures and 20 Schatzker type VI fractures ^[14]. A study by Pradyumna Sharma *et al.* found that 64.28% cases had Schatzker type V fractures and 35.72% Schatzker type VI fractures ^[15].

In view of the mode of injury, majority cases had fractures due to road traffic accidents (70%), followed by accidental fall (16.6%), fall from height (10%) and due to other causes (assault) (3.33%). In a study by Mahesh Kumar Dindivanam *et al.* stated that the road traffic accidents was a common mode of injury in 77%, followed by domestic fall in 23% study participants ^[11]. A study by Thiruvengita Prasad G *et al.* stated that the mode of injury in all the cases was vehicular accidents ^[14]. A study by Pradyumna Sharma *et al.* stated that the road traffic accidents was a common mode of injury in 71.42% followed by fall from height and wall collapse ^[15]. A study by Gavhale SV *et al.* stated that in majority cases, the mode of injury was due to road traffic accidents (83.33%) followed by domestic fall (2 cases) and fall from height (3 cases) ^[12]. The duration between injury and treatment was less

than 3 days in 76.6% cases, 3-6 days in 10% cases and 7-14 days in 13.3% cases. During the intraoperative period, 50-100ml of blood loss occurred in 43.3% cases, more than 100ml in 36.6% cases and in 20% cases less than 50ml blood loss was noticed.

The fracture outcome was assessed by the Lysholm Knee score. In related to the age, majority cases showed excellent outcome followed by good results in 3rd and 4th decades. Fair results were noticed in 1 case each in 5th and 6th decades. Majority cases showed excellent, good results in males than females. Schatzker type IV and Schatzker type V fractures showed a better outcome than Schatzker type VI fractures. In this study, the postoperative outcome showed excellent outcome in 78% cases, good results in 16%, fair results in 6% and none of the case had a poor outcome. A study by Mahesh Kumar Dindivanam *et al.* assessed the postoperative outcome by using the modified Rasmussen Clinical and Radiological Assessment criteria, showed 56.7% cases had excellent, 26.7% cases had good, 10% had fair and 6.7% had poor outcome ^[11]. A study by Gavhale SV *et al.* assessed functional outcome by Rasmussen's knee scoring system showed excellent results in 56.67% cases, good results in 30% and fair results in 13.33% cases ^[12]. A study by Manikandan N *et al.* assessed postoperative clinico-radiological outcomes by modified Rasmussen assessment criteria. Scores were graded as Excellent (55%), Good (40%), Fair (5%), Poor (0%) ^[13]. In a study by Thiruvengita Prasad G *et al.* assessed functional outcome by Oxford Knee Score criteria, among the cases 16 cases had a score between 40-48, other 16 cases had a score between 30-39 and 8 cases had a score between 20-29. In postoperative outcome, 16 cases had no pain, 14 had very mild pain and 10 cases had mild pain ^[14]. A study by Hong-Wei Chen *et al.* assessed postoperative outcome by Rasmussen functional scoring system, showed that 28 cases had excellent results, 8 cases had good results and 3 cases had fair results and none of the cases had poor results ^[16].

Table 4: Duration of postoperative recovery among study participants

Author	Year	Number of cases	Duration of union	Postoperative outcome			
				Excellent	Good	Fair	Poor
Mahesh kumar D	2019	30	17 weeks	56.7%	26.7%	10%	6.7%
Manikandan N	2019	20	10 weeks	55%	40%	5%	-
Surendra singh Yadav	2018	38	15.2 weeks	19 cases	3 cases	2 cases	2 cases
Pradyumna sharma	2016	28	16.5 weeks	28.9%	57.2%	-	14.2%
Hong-Wei Chen	2015	39	12 weeks	28 cases	8 cases	3 cases	-
Gavhale VS	2014	30	-	56.67%	30%	13.33%	-
Thiruvengita Prasad G	2013	46	8-22 weeks	16 cases	14 cases	10 cases	-
Present study	2020	30	12.8 weeks	78%	16%	6%	-

In postoperative complications, 80% of cases were recovered without complications, 10% of cases had a superficial infection, 7% of cases had knee pain, and 3% of cases had knee stiffness. Pradyumna Sharma *et al.* in their study noted that 3 cases developed wound infection, 3 cases developed knee stiffness, one case had malunion and shortening of limb length around 1.8cm was seen in one case ^[15].

Conclusion

Tibial condylar fractures are complex fractures; it is even tough to manage with skilful hands. Anatomical restoration of the articulating surfaces is easy with locking plates, which helps in early mobilization with the early approach to physical therapy. The posteromedial approach of tibial fracture management is safe with minimal complications. Fixation of posteromedial tibia permits the quick reformation of the

patient with the outstanding functional outcome with minimal incidence of complications.

References

1. Ehlinger M, Rahme M, Moor BK, Di Marco A, Brinkert D, Adam P *et al.* Reliability of locked plating in tibial plateau fractures with a medical component. *Orthopedics and traumatology: Surgery and Research.* 2012; 98:173-179.
2. Madhor A Karunakar, Micheal J Bose. Rockwood and Greens "Fracture in adults". 5th edition, 2001.
3. Barei D, O'Mara T, Taitsman L, Dunbar R, Nork S. Frequency and Fracture Morphology of the Posteromedial Fragment in Bicondylar Tibial Plateau Fracture Patterns. *J Orthop Trauma.* 2008; 22(3):176-82.
4. Tracy Watson, Donald A. Wiss in Fractures of proximal

- tibia: chapter 44, Rockwood and Green's Fractures in Adults, edition, Lippincott Williams and Wilkins. 1799-1839, 2.
5. Wei Zhang, Cong-Feng Luo, Sven Putnis, Hui Sun, Zhi-Min Zeng, Bing-Fang Zeng. Biomechanical Analysis of Four Different Fixations for the Posterolateral Shearing Tibial Plateau Fracture. *Knee*. 2012; 19(2):94-8.
 6. Jason A Lowe, Nirmal Tejwani, Brad J Yoo, Philip R Wolinsky. Surgical Techniques for Complex Proximal Tibial Fractures. *Instr Course Lect*. 2012; 61:39-51.
 7. Rui Jiang, Cong-Feng Luo, Ming-Chun Wang, Tie-Yi Yang, Bing-Fang Zeng. A Comparative Study of Less Invasive Stabilization System (LISS) Fixation and Two-Incision Double Plating for the Treatment of Bicondylar Tibial Plateau Fractures. *Knee*. 2008; 15(2):139-43.
 8. Barei DP, Nork SE, Mills WJ, Coles CP, Henley MB, Benirschke SK *et al*. Functional outcomes of severe bicondylar tibial plateau fractures treated with dual incisions and medial and lateral plates. *J Bone Joint Surg Am*. 2006; 88:1713-21.
 9. Berber R, Lewis CP, Copas D, Forward DP. Posteromedial approach for complex tibial plateau injuries with a posteromedial or posterolateral shear fragment. *Injury*. 2014; 45(4):757-65.
 10. Wagner M. General principles for the clinical use of the LCP. *Injury*. 2003; 34(2):31-42.
 11. Mahesh Kumar Dindivanam, Prakashappa TH, Avinash P and Vamsinath P. Functional outcome of surgical management in schatzker type V, VI tibial plateau fractures with locking compression plate. *International Journal of Orthopaedics Sciences*. 2019; 5(2):556-559.
 12. Gavhale SV, Gawhale SK, Gavai PV, Dash KK, Yeragi BSA. Prospective Study of Functional Outcome of Tibial Condylar Fractures Treated with Locking Compression Plates. *Journal Medical Thesis*. 2014; 2(2):23-27.
 13. Manikandan N, Saravanakumar KP. A study on functional and radiological outcome of complex tibial plateau fractures by posteromedial plating. *Int J Res Orthop*. 2019; 5:223-6.
 14. Thiruvengita Prasad G, T Suresh Kumar, R Krishna Kumar, Ganapathy K Murthy, Nandkumar Sundaram. Functional outcome of Schatzker type V and VI tibial plateau fractures treated with dual plates. *Indian J Orthop*. 2013; 47(2):188-194.
 15. Pradyumna Sharma, Venkatachalam K, Pugazhendhi G, Madhukar. A Prospective Study of the Functional Outcome of Locking Compression Plating for Closed Schatzker Type V and Type Vi Tibial Plateau Fractures. *Sch. Acad. J Biosci*. 2016; 4(10A):849-862.
 16. Hong-Wei Chen, Chang-Qing Chen, Xian-Hong Yi. Posterior tibial plateau fracture: a new treatment-oriented classification and surgical management. *Int J Clin Exp Med*. 2015; 8(1):472-479.