

E-ISSN: 2395-1958
P-ISSN: 2706-6630
IJOS 2020; 6(1): 63-68
© 2020 IJOS
www.orthopaper.com
Received: 14-11-2019
Accepted: 18-12-2019

Dr. Raghavendra B
Junior Resident, Department of
Orthopaedics Mamata Medical
College, Khammam, Telangana,
India

Dr. Sahithya
Assistant Professor, Department
of Orthopaedics, Mamata
Medical College, Khammam,
Telangana, India

To study surgical management of proximal tibia fractures by locking compression plate

Dr. Raghavendra B and Dr. Sahithya

DOI: <https://doi.org/10.22271/ortho.2020.v6.i1b.1840>

Abstract

Proximal Tibial fractures have been studied and reported extensively and exhaustively but still controversy exists over its management, whether surgical or conservative. Excellent results have been published in both groups. On one hand, we have got a group of surgeons who says that most of the Proximal Tibial fractures can be managed by conservative treatment and on the other hand, other group says conservative treatment means therapeutic nihilism and except for undisplaced fracture every Proximal Tibial fracture should be operated upon to achieve anatomical reduction and rigid internal fixation. Even undisplaced Proximal Tibial fractures should be operated, so that early mobilization of knee it is possible⁴.

The objectives of treatment of Proximal Tibial fracture, is precise reconstruction of the articular surfaces, stable fragment fixation allowing early mobilization and repair of all concomitant ligamentous and other soft Tissue lesions.

Keywords: Proximal tibia, locking compression plate, schatzker

Introduction

Objectives

1. To outline the various principles of management of Proximal Tibial fractures treated with an aim of achieving a stable, well aligned, mobile joint with minimum articular irregularities.
2. To put forward fresh clinical material to evaluate the results of surgical methods.
3. To evaluate the effectiveness of the surgical modalities of the treatment and to overcome their complications and re-operations.
4. To faster early knee motion and improve quadriceps and hamstring power.
5. To decrease morbidity in the patient and to enable the patient to regain pre injury activity (activities of daily living without assistance) and ROM.

Methods

The number and diversity of treatments that have been used in the management of Proximal Tibial fractures is a tribute to the ingenuity of surgeon who was stimulated by dissatisfaction with earlier methods. In general, the best treatment is the simplest and least risky that gives promise of accurate articular surface reduction, restoration of leg alignment and knee stability while permitting early rehabilitation.

According to Schatzker, enough experience has accumulated to formulate the following principles of treatment.

1. Proximal Tibial fractures immobilized for more than 4 weeks usually leads to some degree of joint stiffness.
2. Internal fixation of plateau fractures combined with immobilization of the knee leads to even greater degrees of joint stiffness.
3. Regardless of the method or technique of treatment, the knee joint must be mobilized early.
4. As long as joint mobility is preserved, secondary reconstructive procedures are possible.
5. Impacted articular fragment cannot be dislodged by traction or manipulation alone as there is no soft tissue attachment to lever them upward.

Corresponding Author:
Dr. Sahithya
Assistant Professor, Department
of Orthopaedics, Mamata
Medical College, Khammam,
Telangana, India

6. Depressed articular surface defects do not fill in with hyaline cartilage and remains as permanent defects, therefore result in unstable joint unless it is surgically corrected.
7. Articular fractures that result in joint instability require open reduction and internal fixation.
8. Absolute joint congruency can be restored only by open reduction.
9. Anatomic reduction and stable fixation is necessary for cartilage regeneration
10. Open reduction and internal fixation if indicated but inadvisable, then skeletal traction and early motion are advisable.

Modalities of treatment of proximal tibial fractures

I. Conservative [5].

1. Closed reduction and POP cast application.
2. Skeletal traction and mobilization⁶
3. Functional Brace²⁸

II. Surgical

1. Percutaneous cancellous screw fixation²⁹.
2. ORIF with cancellous screws and Bone grafting.
3. ORIF with Buttress plate and screws.
4. ORIF with Buttress plate and screws and Bone grafting.
5. External fixator/ Hybrid external fixator/ Ilizarov ring fixator.
6. Arthroscopic assisted internal fixation².
7. MIPPO (Minimal Invasive Percutaneous Plate Osteosynthesis)

Locking compression plate (LCP)

A further refinement of internal fixator systems, with screw heads locking firmly into the plate hole, has now been devised. This is a new plate hole configuration which brings to this most valuable innovation the advantages of conventional plating for example. Placement of a lag screw across the plate for certain fracture configurations. This is achieved through a new design, the "combination" plate hole which can accommodate either a conventional screw or the new "locking head screw (LHS)" which has a conical threaded head.

Locking compression plates are indicated for certain high energy fractures, those with severe comminution and in osteoporotic fractures. Laterally based locking plate offers an alternative to an additional medial plate or external fixator for support of the medial column in bicondylar fractures. Interfragmentary compression cannot be achieved by locked plates; supplementary use of Interfragmentary screws may be required to prevent loss of reduction and to ensure adequate compression of the fragment.

Screws

1. Cortical screws: 4.5 mm diameter of various lengths
2. Cancellous screws: 16mm, 32mm partially threaded and fully threaded
3. Locking screws

Cortical screws have a thick core with narrow thread and are used for purchase in cortical bone. Cancellous screws have a thin core with wide and deep threads and used for purchase in epiphyseal and metaphyseal areas of bone. Full threaded screws acts as fastening device for the plate. Partially threaded screws are used as lag screws to achieve compression of fractured articular surface.

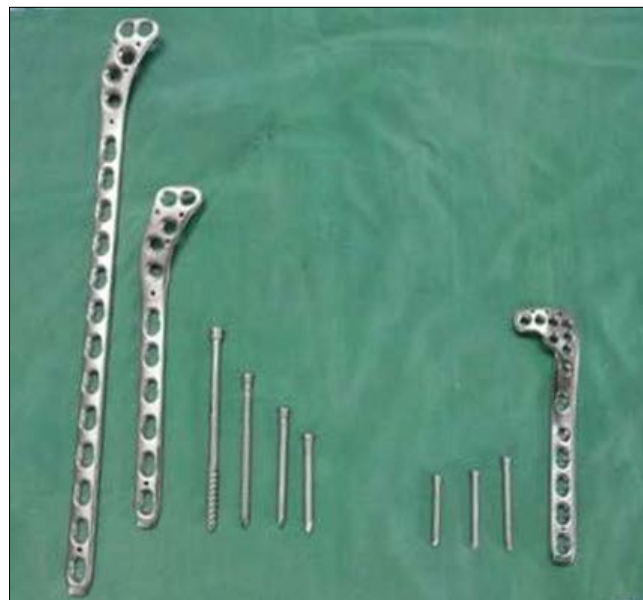

Fig 1: Locking compression plate for proximal tibia

Inclusion Criteria

- a. All patients with Proximal Tibial fracture in the age group of 18-60 years.
- b. Fractures with >3mm depression/displacement.
- c. Radiological diagnosis of fractures with classification based on Schatzker's classification.

Exclusion Criteria

- a. Age: Less than 18 years
- b. Patients who are medically unfit for the surgery.
- c. Compound Proximal Tibial fracture. d pathological fractures

Operative procedure

Surgery is performed with the patient supine on a radiolucent operating table under general or spinal anaesthesia. The entire injured limb is prepared and draped along with the ipsilateral iliac crest. It is preferable to use a sterile tourniquet and C-arm image intensifier. The table should provide the capability to flex the knee to 90°. Alternatively, a large sterile bolster that permits knee flexion to 90° can be used. Knee flexion allows the iliotibial band to slip posteriorly off the lateral condyle of the femur that facilitates both exposure and better visualization of the joint.

Surgical approaches

The use of these exposures allows as much exposure of the articular surface and tibial shaft as is required and to reduce a fracture and apply plates and screws to the tibial condyle and shaft. Such surgical wounds tend to heal rapidly and predictably. Because many knees with plateau fractures will eventually develop traumatic arthritis, whenever possible skin incisions that are not likely to interfere with later knee replacement should be planned.

Approach to lateral Proximal Tibial

- a. Lateral curvilinear approach
- b. Lateral Parapatellar approach

Approach to the medial Proximal Tibial

- a. Medial curvilinear approach.
- b. Median Parapatellar approach

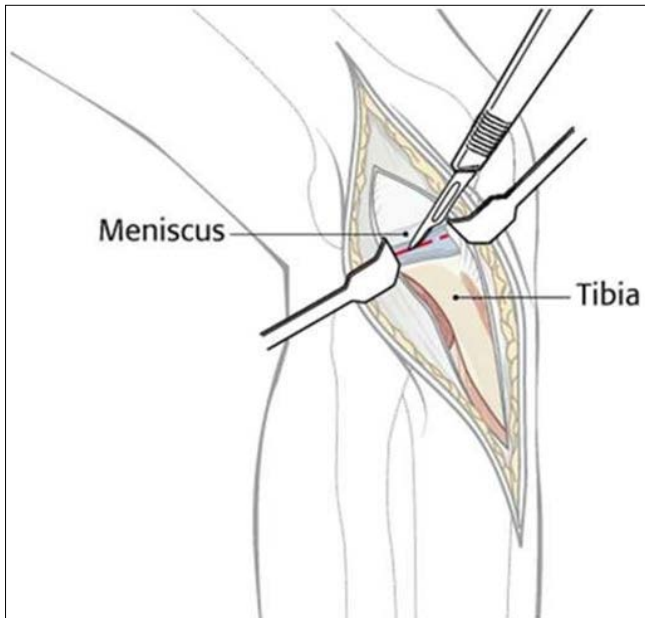


Fig 2: Antero Lateral Approach

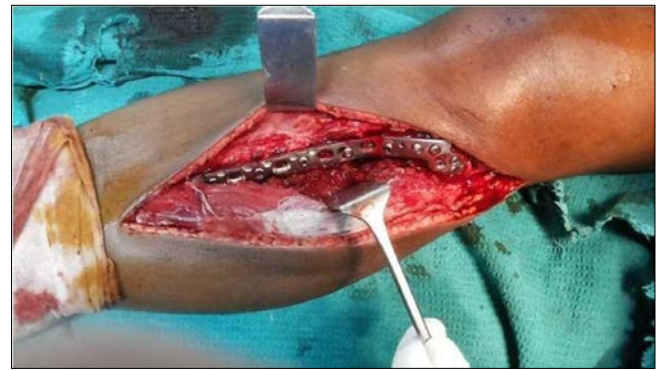

Fig 5: LCP in position

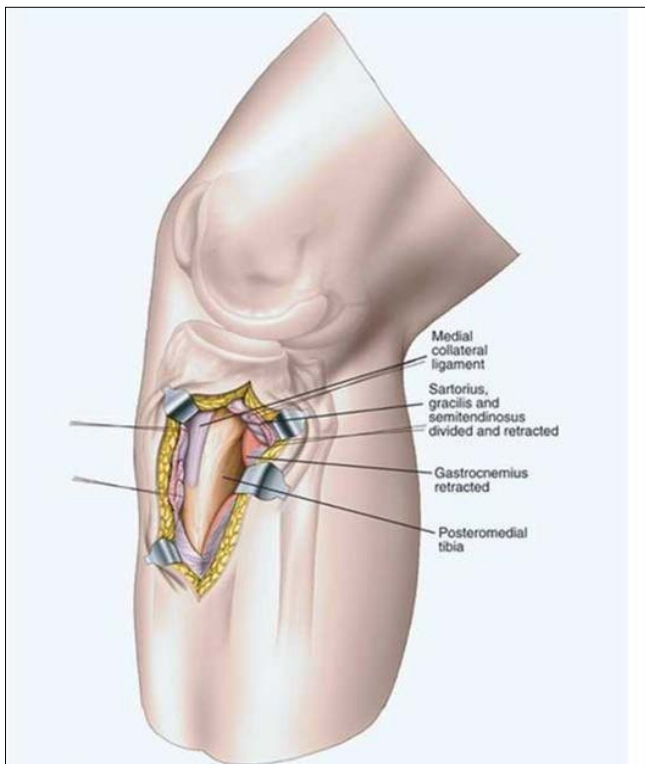


Fig 3: Postero Medial Approach

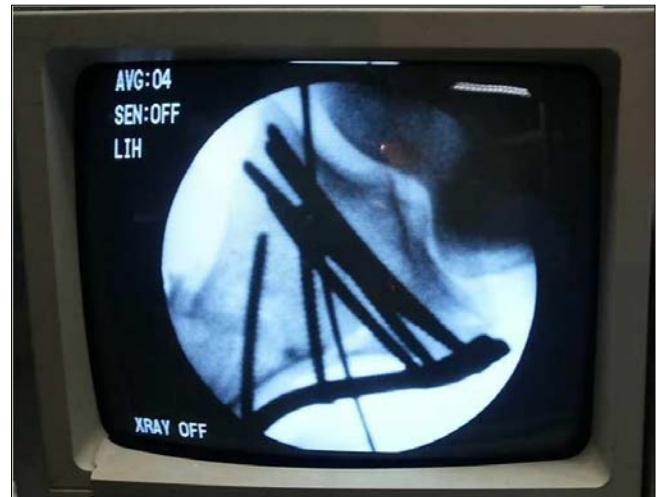

Fig 6: Radiographic image

Intra-Operative Images

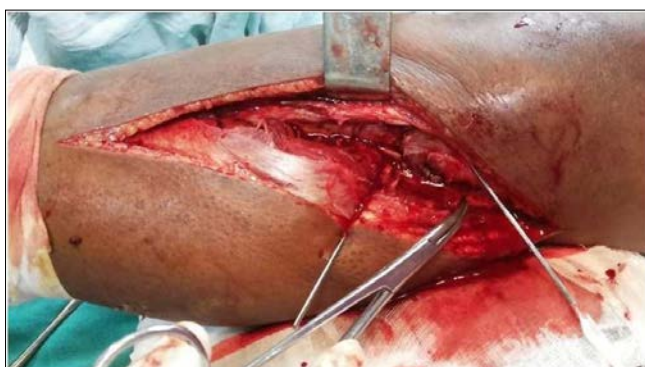

Fig 4: Intraoperative image

Post-operative care

The hallmark of the treatment is early range of motion and delayed weight bearing. If stable fixation is done continuous passive mobilization carried out. In schatzker type I, II and III no weight bearing for four to eight weeks, partial weight bearing for next four to six weeks and full weight bearing at three months. In high energy plateau fracture continuous passive mobilization is set only to 20 to 30 degree flexion and protected with hinged knee braces, weight bearing delayed for eight to twelve weeks.

Post-operative instructions

1. Vital signs monitoring
2. Postoperative analgesia
3. To watch out for bleeding
4. Postoperative antibiotics depending on culture and sensitivity and condition
5. Foot end elevation (as the surgeries are performed under spinal anaesthesia).
6. Postoperative X-ray preferably the next day.
7. Dvt prophylaxis
8. Maintenance of fluid and electrolyte balance

Follow Up

The first follow up was done at 2 weeks, during which the surgical scar was inspected and range of movements noted. The second follow up done at 6 weeks during which an X-ray was taken to look for signs of fracture union and loss of reduction if any. The third follow up was done at 3 months during which one more X-ray was done and a clinical evaluation of union done.

Based on the clinical and radiological signs of union patients

were allowed partial weight bearing and gradually progressed to full weight bearing. The patients were then followed up at 6 months, 1 year and 2 years respectively during which time functional evaluation was done using the Rasmussen evaluation method. The posttraumatic osteoarthritis was assessed on the most recent radiographs taken with the patients standing.

Complications of treatment

The complications occur by virtue of fracture and also after the treatment. Most of the complications are preventable. Preventive care begins with thorough examination of the injured limb. Important aspects to detect are the peripheral neurovascular injuries that may accompany with the upper tibial fractures, prompt treatment of these injuries usually takes precedence over definite fracture treatment and often prevent catastrophic complications.

A) Early Complications

1. Bleeding.
2. Thrombophlebitis and Embolism.
3. Wound infection /Dehiscence - Superficial or Deep
4. Sepsis
5. Compartment syndrome
6. Pain
7. Swelling
8. Knee stiffness
9. Nerve Injury (Lateral politeal. N)
10. Vascular Injury (Anterior tibial A)
11. Loss of fracture reduction
12. Limb length discrepancy
13. Deep vein thrombosis

B) Late Complications

1. Wound Infection
2. Knee stiffness
3. Malunion
4. Knee instability – varus/valgus/anterior/posterior
5. Extensor lag
6. Angular deformities
7. Persisting pain/swelling
8. Redepression
9. Refracture
10. Delayed union
11. Non-union

Criteria for evaluation of results of points

1. Pain

1. No pain - 6
2. Occasional pain - 5
3. Stabbing pain in certain position, Moderate pain-4
4. Severe pain, constant pain around knee joint after activity - 2
5. Night pain, at rest – 0

2. Walking capacity

1. Normal walking capacity in relation to age -6
2. Walking capacity out doors for atleast one hour-4
3. Walking capacity out doors > 15 minutes - 2
4. Walking capacity - walking indoors only - 1
5. Wheel chair bound / Bed ridden - 0

3. Extension of Leg (Extensor lag)

1. Normal extension - 6
2. Lack of extension (0-10°) - 4

3. Lack of extension (> 10°) - 2

4. Range of Motion

1. At least 135° - 6
2. At least 120° - 5
3. At least 90° - 4
4. At least 60° - 2
5. At least 30° - 1 6) - 0° - 0

5. Stability

1. Normal in extension & 20° flexion - 6
2. Abnormal in 20° flexion - 5
3. Unstable in Extension (> 10°) - 4
4. Unstable in extension (> 10°) – 2

Analysis of results

Excellent results	Total minimum of 27 points
Good results	Total minimum of 20 points
Fair results	Total minimum of 10 points
Poor results	Total minimum of 06 points

Out of 24 cases treated with surgical procedure, 6cases gave excellent result, 13 cases came out with good result, fair in 2 cases and 3 cases of poor result, mainly due to the severity of the injury and infections

Clinical Results	No. of cases	Percentage
Clinical results		
Excellent	6	25%
Good	13	54.16%
Fair	2	8.34%
Poor	3	12.50%

CASE-1

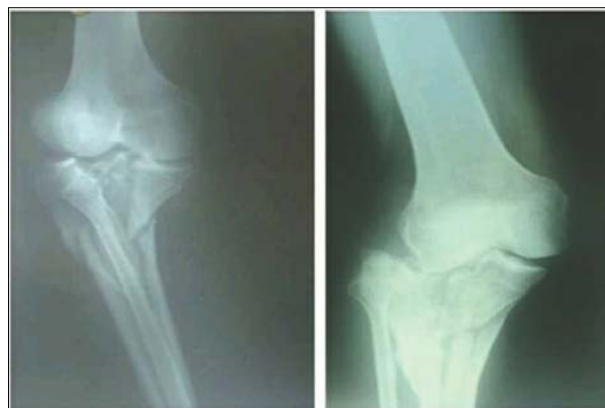

Fig 7: Pre-Operative

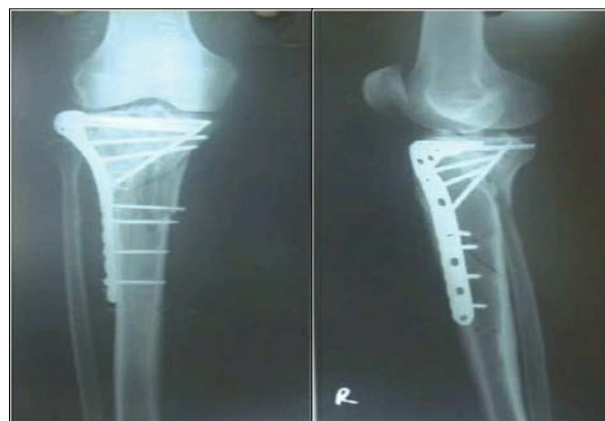

Fig 8: Immediate Post-Op

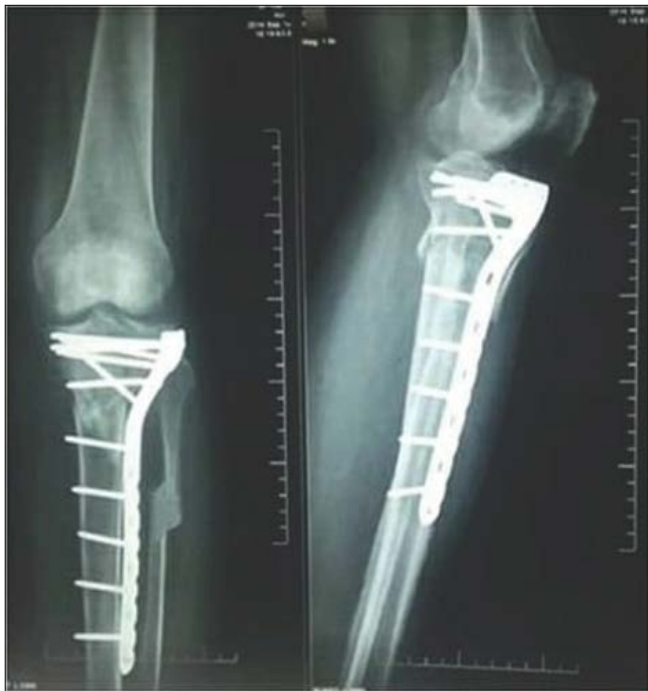

Fig 9: 6 months follow up

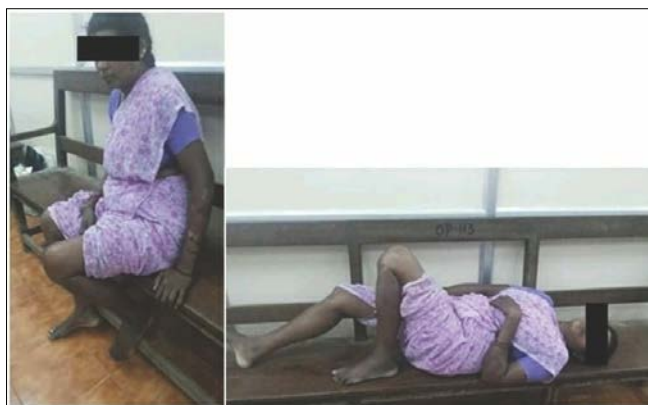

Fig 10: Clinical pictures in post op review

Discussion

Proximal tibial fractures, one of the commonest intra articular fractures, incidence of this fractures are increasing regularly due to RTA and at the same time surgical treatment options for the same are also being modified continuously. Any fracture around the weight bearing joint like knee joint is of paramount importance as would result in significant morbidity and quality of life.

Problems encountered in proximal tibial fracture

1. Instability
2. Secondary osteoarthritis
3. wound dehiscence
4. Extensor lag
5. Infection

However the aim is to obtain a stable joint permitting early range of motion for cartilage nourishment and preservation. Goals of treatment of proximal tibial articular fractures include restoration of articular congruity, axial alignment, joint stability and functional motion. If normal axial alignment is not maintained is leads to premature osteoarthritis due to change of weight bearing axis. In normal stance 75 to 90% of load is borne on medial portion of knee. When injury to the articular cartilage is penetrating, it disrupts

the function of the proteoglycan, which affects the mechanism for support of compressive load. As long as the collagen network is intact, the chondrocytes can regenerate the proteoglycan matrix. But when the collagen network is disrupted, the defect is filled with a fibro cartilaginous tissue, which does not have the type or content of normal proteoglycan.

The result is that more than half of such defects undergo degenerative changes by 6-12 months after injury.

Hence the treatment of proximal tibial fractures has become a challenge for the orthopaedic surgeons.

To overcome this difficulties and to early restoration of strength of bone and function of knee joint with minimal injury to soft tissue the innovators developed new technology called locking compression plate system.

As per biomechanics the screws of locking compression plate virtually act as pegs resisting axial, rotational and bending forces. Because of more stability of implant and intact periosteum producing early callus and primary fracture union producing visible callus allows early mobilization of joints around the fracture.

Advantages of LCP

1. Improved blood circulation by minimising the damage to periosteum due to contact between plate and bone
2. Allows for a small bone bridge beneath the plate at the most critical area which is otherwise weak due to stress concentration
3. More even distribution of the stiffness of the plate than in conventional plate At the end of our study, following conclusions could be drawn from the surgical management of proximal tibial fracture with locking compression plate
 - Proximal tibial fracture are increasing with the increase in Road traffic accidents.
 - These fracture need optimum treatment as most of them involved the productive men.
 - Preoperative soft tissue status and their repair at right time. Significantly changes the outcome.
 - In high velocity injuries belonging to Schatzker' type IV, V, VI results varied and depended on the reconstruction of the articular surface and collapse of the fracture during post operative period
 - Incidence of minimal to moderate post traumatic osteoarthritis was higher in patients with high velocity injuries, indicating the importance of accurate articular surface reconstruction by surgical methods.

The anchorage of the locking head screw was found to be excellent even in osteoporotic bone.

Drilling the holes for the locking head screw should always be through a screw-in drill sleeve.

- While bridging a fracture, care must be taken to select a strong plate and leave atleast 2-3 plate hole, without inserting screws over the fracture. This prevent the stress concentration and achieves an elastic fixation which is very essential for secondary fracture union.
- Even in osteoporotic bone, bone graft is not essential for defect in metaphyseal region as LCP internal fixator system act as single implant and prevent collapse of fracture intraoperatively and postoperatively subsequently bone deficient will heal by callus formation.
- When LCP used as combined principle of fixation we can reconstruct tibial plateau with compression and prevent it from collapse by bridging principle.

Conclusion

Thus we conclude that the locking compression plate system acts as an good biological fixation including difficult fracture situations.

Pevny MD, Andrew I *et al.* Arthroscopic Management of tibial plateau fractures, *Techniques in knee surgery.* 2007; 6(1):9-16.

References

1. Marsh JL. Fractures of the proximal tibia and fibula, chapter 53 in Rockwood and Green's fractures in adults, Bucholz RW and Heckman JD Ed. 7th ed. Vol 2: Philadelphia, Lippincott Williams and Wilkins, 2010, 1781-1839.
2. Matthew IR. Fractures of lower extremity tibial plateau In; Campbell's operative orthopaedics, 12th ed: Canada; Elsevier Mosby publishers. 2013; 3:2668-81.
3. Lambotte A. The operative treatment of fractures: report of fractures committee, Br. Med J. 1912; 2:1530.
4. Roberts JM. Fractures of the condyles of tibia, An anatomical and clinical end result study of 100cases. J Bone & Joint Surg. 1968; 50(Am):1505.
5. Wilson JN. Injuries of the knee in Watson-Jones fractures and Joint injuries. 6th Edn. Vo.1-2. New Delhi. B.I Churchill Livingstone, 2002, 1077-79.
6. Apley AG. Fractures of lateral tibial condyle treated by skeletal traction and early mobilization. J Bone & Joint Surg. 1956; 383:699.
7. Rasmussen DS. Tibial condylar fractures, Impairment of knee joint stability as an indication of surgical treatment JBJS. 1973; 55(A):1331.
8. Moore TM, Maniey JP. Roentgenographic measurement of tibial plateau depression due to fracture. J Bone Joint Surg. 1974; 56-(A):155-160.
9. Schatzkar J, Mc Broom R, Bruce D. The tibial plateau fractures - Toronto experience. Clin Orthop. 1979; 138:94-104.
10. Drennan DB, Locher FG, Maylahn DJ. Fractures of the tibial plateau: Treatment by closed reduction and spica cast; JBJS. 1979; 61:989-995.
11. Bowes DN, Hohi M. Tibial condyle fracture: Evaluation of treatment and out come; Clin Orthop. 1982; 171:105-108.
12. Blokker CP, Rorabeck CH, Bourne PB. Tibia plateau fractures - An analysis of the results of treatment in 60 patients; Clin orthop. 1984; 182:193.
13. Dias JJ, Strung AM, Finaly DB. Computerized Axial Tomiography for tibial plateau fractures. J Bone joint surg. 1987; 69(b):84-88.
14. Duvelius PJ, Conolly JF. Closed reduction of the tibial plateau fracture: A comparison of functional and roengenographic end results; Clin Orthop. 1988; 230:116-125.
15. Delamarter R, Hohl M. The cast brace and tibialplateau fractures, clin orthop. 1987; 242:26.
16. Jensen DB, Rude C, Duus B, Nielsen AB. Tibial plateau fractures - A comparison of conservative and surgical treatment. J Bone & Joint Surg. 1990; 32(Br):49-52.
17. Honkonen SE. Indications for surgical treatment of condyle fractures; Clin Orthop. 1994; 302:199-205.
18. Tscherne H, Lobenhoffer P. Tibial plateau fractures, management and excepted result: Clin orthop. 1993; 292:87-100.
19. Marsh JL, Smith ST, Do TT. External fixation and limited internal fixation for complex tibial plateau fractures. J Bone & Joint Surg May. 1995; 77(Am):661-673, 90.
20. Lindsay N, Harris MD, Mark L, Purnell MD, Tomas