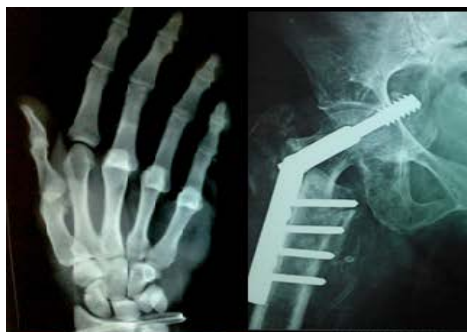



International Journal of Orthopaedics Sciences

E-ISSN: 2395-1958
P-ISSN: 2706-6630
IJOS 2020; 6(1): 05-10
© 2020 IJOS
www.orthopaper.com
Received: 04-11-2019
Accepted: 08-12-2019

Dr. Mohammed Tauheed MS
Associate Professor, Department
of Orthopaedics, The Oxford
Medical College, Hospital &
Research Centre Yadavanahalli,
Attibele, Behind La Classic
Hotel, Bangalore, Karnataka,
India

Dr. Mohammed Shahid
Junior Resident, Department of
Orthopaedics, Yenepoya Medical
College University Road,
Yenepoya University Campus,
Deralakatte, Karnataka, India

Dr. Channabasava Patil
Department of Orthopaedics,
The Oxford Medical College,
Hospital & Research Centre
Yadavanahalli, Attibele, Behind
La Classic Hotel, Bangalore
Karnataka, India

Corresponding Author:
Dr. Mohammed Tauheed MS
Associate Professor, Department
of Orthopaedics, The Oxford
Medical College, Hospital &
Research Centre Yadavanahalli,
Attibele, Behind La Classic
Hotel, Bangalore, Karnataka,
India

To evaluate the accuracy of the femoral tunnel length measurements for acl reconstruction using the endobutton indicator selection device from outside the knee joint and the Transportal endobutton depth probe

Dr. Mohammed Tauheed MS, Dr. Mohammed Shahid and Dr. Channabasava Patil

DOI: <https://doi.org/10.22271/ortho.2020.v6.i1a.1823>

Abstract

Purpose: To evaluate the accuracy of femoral length measurements for ACL reconstruction using the endobutton indicator selection device from outside the knee joint and the transportal endobutton depth gauge.

Methods: 50 cases of primary ACL injuries, both single bundle and double bundle reconstructions were evaluated for their intra operative femoral tunnel lengths by using the Endobutton indicator selection device from outside the knee joint and the transportal Endobutton depth gauge and were compared with the post-operative CT femoral tunnel lengths obtained using the Osiri X imaging software.

Results: The mean femoral tunnel lengths measured intraoperatively using the Endobutton selection device (35.68±3.99mm for anteromedial tunnel [AM],) significantly longer than the measurements obtained using the Endobutton depth probe. However, there was no statistically significant difference in the posterolateral tunnel [PL] measurements [37.17±3.83mm for Endobutton selection device and 37.22±3.74 for Endobutton depth probe]. Also the measurements obtained using Endobutton depth probe were closer to the CT measurements and better correlation with the longer CT tunnel wall measurements.

Conclusion: Measurements by both the Endobutton depth probe and the Endobutton selection device are longer than the actual femoral tunnel length for ACL reconstruction. Even though the difference between the mean measurements obtained by the two devices is statistically significant but the actual difference is so minimal that it barely has any effect in the decision making for the selection of the fixed loop device the graft length in ACL reconstruction. Thereby we suggest that the Endobutton Indicator Device is an easy to use and more convenient alternative to the Endobutton depth probe for measuring the femoral tunnel length in ACL reconstruction.

Keywords: Femoral tunnel length, endobuttton indicator selection device, endobutton depth probe, fixed loop cortical suspension device

Introduction

Fixed loop cortical suspension devices are currently the most frequently used for fixation of the ACL graft, however this method of fixation is not free from complications including tunnel enlargement due to graft tunnel motion, the so-called 'bungee cord' effect [5, 12, 14, 17]. To achieve maximal contact of the graft with the bone tunnel the length of the loop should be kept to a minimum, this requires accurate measurement of the femoral tunnel length as longer length measured intra operatively may result in shorter graft length as we tend to use a longer suspension device [11].

Although the minimum tunnel length necessary for adequate femoral fixation is somewhat controversial [15, 20, 19], it has been suggested that tunnels shorter than 25 mm may not allow an adequate contact surface area at the bone-tendon junction for healing [3, 4, 7].

With more and more emphasis on anatomical ACL reconstruction and drilling of the femoral tunnel through the transportal technique it is found that the femoral tunnel length achieved is shorter than the transtibial drilling [3, 4, 16]. it is also suggested that the with lesser the axial plane angle of drilling longer femoral tunnel lengths can be achieved [8, 10, 7].

with more anterior tunnel positioning tunnel length also increases [9]. Tunnel lengths tend to be longer with increasing patient height, mass, and larger lateral femoral condyle dimensions and hyper flexion of the knee [18, 1]. Recent studies show that the outside-in technique for creating the ACL femoral tunnel results in longer tunnel lengths than the AM portal technique [13, 11].

To the best of our knowledge, there is no study which compares the measurements by the two techniques using two different measuring devices (The Endobutton selection Indicator device from outside the knee joint and the Endobutton depth gauge transport tally). Therefore in our study we have compared the measurements obtained using the two devices and with the post op CT measurements as a standard.

Materials and Methods

From January 2014 to July 2014, we enrolled 50 patients with diagnosis of primary ACL injury. Of the 50 patients, 4 values were missing for the pre-op transportal measurements and were excluded, effectively there were 46 cases with measurements by both the techniques for AM tunnel, with 5 cases being single bundle reconstructions, and these were included under AM tunnel measurements. 35 PL tunnel measurements were recorded using both the techniques.

Results were analysed separately for AM bundle and PL bundle measurements using the Endobutton Indicator Selection Device (Smith & Nephew) and Endobutton depth probe (Smith & Nephew). All patients were informed that they were going to participate in a study.

Surgical technique

The portal formation and arthroscopic examinations were conducted in the usual manner. Either the hamstrings or allograft were prepared for the AM and PL bundle. The femoral footprints of both the AM and PL bundles were carefully defined in reference to soft tissue remnants and bony anatomy [6]. A flexible guide wire and reaming system (Smith & Nephew) are used with the "footprint technique" [2]. Using a curved cannulated guide oriented superolaterally over the femoral footprint for ACL, a 2.7 mm passing pin is drilled into femur until black line marked on pin is flush with bone on lateral wall of femoral condyle in notch and it emerges superolaterally over the distal thigh skin.

A stab incision is made over the skin at the point of the emerging pin and Endobutton Indicator Selection device is glided over the guide pin from outside the knee until it touches bone of the lateral condyle (Fig. 1a) and the measurements are recorded in a small window present over the device (Fig. 1b).

Next an Endobutton reamer is used to create the tunnel for Endobutton and the passing pin is removed, again the femoral tunnel length is measured, this time through the medial portal using an Endobutton depth gauge (Smith & Nephew endoscopy) with 2 mm increments to measure the distance from the intra-articular aperture to the lateral cortex, the measurements were noted at the medial margin of femoral tunnel intra-articular aperture (Fig. 2). Using appropriate sized reamers adequate graft tunnel of more than 25mm is drilled. The PL tunnel is also drilled and measured in the

similar manner.

Computed tomography (CT) protocol and measurement

Computed tomography (CT) scans were performed with patient consent on all knees after ACL reconstruction. The same CT scanner Light Speed VCT (GE Medical Systems, Milwaukee, WI, US) was used for all examinations. The knee was placed in full extension. The collimation was 1690.625 mm. The tube parameters were 120 kVp and 200 mA. The acquisition matrix was 5129512. The field of view was 140 mm, and the slice thickness was 0.625 mm. After extracting the DICOM data from the Picture Archiving and Communication System (PACS), data were imported into OsiriX® imaging software (Version 3.8, Open source software for Mac OS).

To measure the femoral tunnel length, we selected the plane in which the entire length of the femoral tunnel showed the maximal width. Then we drew the lines along the margins of the AM and PL tunnel as the shortest and the longest length connecting the outer and the inner aperture on the sections. The average of these two measurements corresponds with the central tunnel length measured by drawing a line along the centre of the tunnel connecting the outer and inner apertures (Fig. 3). The measurements were taken by two observers to limit the observer bias.

Evaluation of data

Intraoperatively measured femoral tunnel lengths using the Endobutton indicator selection device and the Endobutton depth probe were recorded at the operating room. Femoral tunnel lengths measured by CT taken in postoperative 3 days were also recorded. We calculated the femoral tunnel length difference (femoral tunnel length measured intraoperatively - femoral tunnel length measured postoperatively). A priori power analysis was performed to determine the sample size by use of the 2-sided hypothesis test at α -level of 0.05 and a power of 1 for both AM tunnel and PL tunnel

Intraoperative (using the Endobutton indicator selection device and the Endobutton depth probe) and postoperative (CT) femoral tunnel length measurements were compared for the AM tunnel and PL tunnel separately using a two-sample t test and a paired t test. We also measure the correlation between the longest and shortest CT measurements obtained with the measurements obtained using the Endobutton indicator selection device and the Endobutton depth probe with the post op CT measurements. Statistical analysis was performed using Statistical Package for the Social Sciences (SPSS) software (version 12.0; SPSS, Chicago, IL, USA).

Statistical analysis

All Statistical analyses were made using Statistical Package Software for Social Sciences (SPSS) version 17.0 software (Chicago, IL, USA). Intraoperative femoral tunnel lengths measured using the two devices were compared with the postoperative femoral tunnel length using a paired sample t test. The femoral tunnel length differences of the two groups were also compared using paired sample t test. This study final involved 50 cases with 46 AM tunnels and 35 PL tunnels measured intra operatively by two devices and postoperatively by CT.

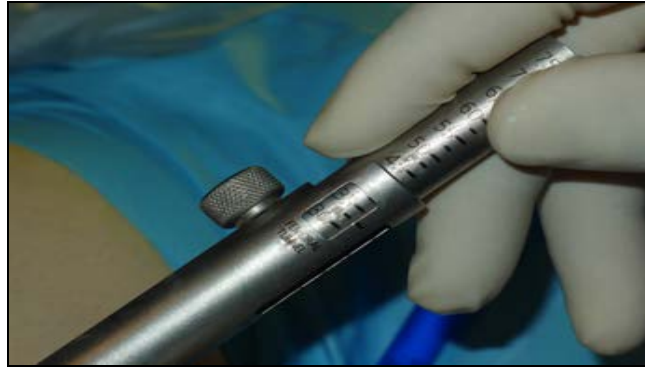


Fig 1: Measurement of femoral tunnel length using Endobutton Indicator Selection device. (a) Stab incision is made over the skin at the point of the emerging pin and Endobutton Indicator Selection device is glided over the guide pin from outside the knee until it touches bone of the lateral condyle. (b) Measurements are recorded in a small window present over the device.




Fig 2: Femoral tunnel length measurement using the Endobutton depth probe. (a) Endobutton depth probe is inserted through the medial portal (b) The measurements were noted at the medial margin of femoral tunnel intra-articular aperture using the scope through lateral portal.

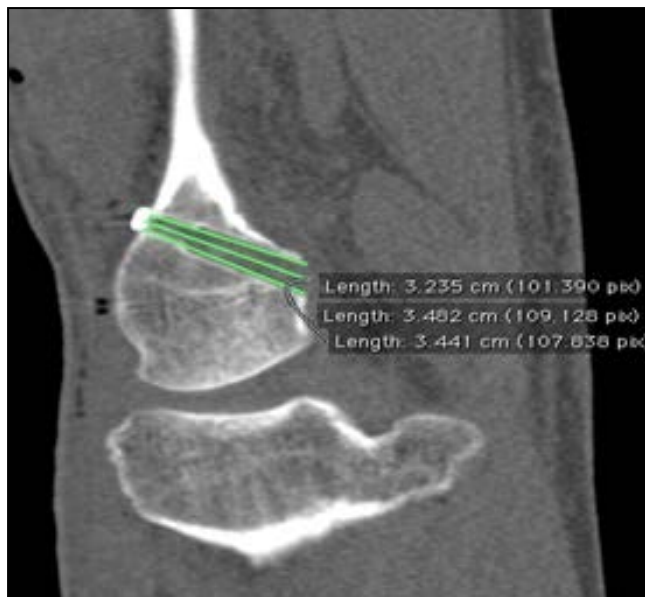

Fig 3: To measure the femoral tunnel length, we selected the plane in which the entire length of the femoral tunnel showed the maximal width. Then we drew the lines along the margins of the AM and PL tunnel as the shortest and the longest length connecting the outer and the inner aperture on the sections. The average of these two measurements corresponds with the central tunnel length measured by drawing a line along the centre of the tunnel connecting the outer and inner apertures

Results

The inter-observer ICC was 0.92 and 0.91 for AM and PL femoral tunnel, respectively. The intra-observer ICC ranged 0.98 and 0.99 for AM and PL tunnel (Table-1). The mean AM femoral tunnel length measured intraoperatively using the Endobutton indicator selection device (35.68 ± 3.99 mm) was significantly longer than that of measurements using Endobutton depth probe (34.98 ± 3.97 mm) ($P < 0.05$). The actual clinical difference being just 0.7mm. However, the mean PL femoral tunnel length measured intraoperatively in Endobutton indicator selection device (37.17 ± 3.83 mm) had not much difference compared to the measurements using

Endobutton depth probe (37.22 ± 3.74 mm) ($P = 0.842$). (Table 2) The mean AM/PL femoral tunnel lengths measured intraoperatively using either of the device were significantly longer than those measured postoperatively (CT) for AM tunnel PL femoral tunnel length).

The mean difference between measurements using the Endobutton indicator selection device and post-operative CT measurements (3.43 ± 1.93) and the Endobutton depth gauge measurements (2.74 ± 1.64) for the AM tunnel were statistically significant ($P = 0.23, < 0.05$) (Table-2).

There was no significant difference in the lengths measured using either of the device for the PL tunnel.

Table 1: Results of intra-class correlation coefficient (ICC) value of postoperative femoral tunnel length measurement A measurement was considered reliable if the ICC was higher than 0.80

	AM	95% confidence interval	PL	95% confidence Interval
Intertester ICC	0.924	0.857-0.959	0.910	0.742-0.962
Tester 1 ICC	0.992	0.986-0.996	0.992	0.985-0.996
Tester 2 ICC	0.998	0.991-0.999	0.997	0.990-0.999

Table 2: Comparison of femoral tunnel length measurements using the Endobutton indicator device and the Endobutton depth probe and the postoperative CT measurements.

Tunnel length	Tunnel	Endobutton Indicator Selection Device	Trans Portal measurement using Endobutton Depth gauge	P value
Femoral tunnel length (intraoperative)	AM (n=46)	35.68 ± 3.99 (25-44)	34.98 ± 3.97 (26-46)	0.023 (<0.05)
	PL (n=35)	37.17 ± 3.83 (29-45)	37.22 ± 3.74 (29-44)	.842 n.s
Femoral tunnel length (postoperative)	AM (n=46)	32.24 ± 3.94 (27.31-42.37)	32.24 ± 3.94 (27.31-42.37)	---
	PL (n=35)	34.69 ± 3.75 (27.80-41.87)	34.69 ± 3.75 (27.80-41.87)	---
Femoral tunnel length difference*	AM(n=46)	3.43 ± 1.93 (-3.50-7.83)	2.74 ± 1.64 (-1.20-5.89)	.023
	PL(n=35)	2.47 ± 2.03 (-0.13-9.88)	2.52 ± 2.30 (-0.03-10.88)	.842 n.s

Discussion

In our study we tried to compare the measurements of the femoral tunnel using the two different devices used in ACL reconstruction namely the Endobutton Indicator Selection Device and the Endobutton Depth Probe. We found that both the devices measure the tunnel length significantly higher than the actual tunnel length as determined using the CT scans. The measurements done for AM tunnel showed longer lengths when Endobutton Indicator Selection Device was used when compared with the Endobutton Depth Probe, though the difference was just 0.7mm between the means of the two. However not much of difference was seen for PL tunnel measurements between the two devices. There are many pitfalls in using Endobuttton depth probe for measuring the femoral tunnel length, the margin of intra-articular aperture of the femoral tunnel can be changed according to the degree of knee flexion and rotation of ruler because of elliptical shape of intra-articular aperture of the femoral tunnel in ACL. The soft tissue around aperture such as remnant ACL and poor visual field in through the lateral portal can cause difficulty to exactly localise the margin of the intra articular aperture. The technique for measuring the tunnel length utilizing a hook probe type device like Endobuttton depth gauge might be read as a diagonal through the tunnel as the probe got hooked on an edge of one aperture and pulled away from this edge to be read the other intraarticular tunnel edge. This might cause longer intraarticular femoral tunnel length measurement. Also the Endobuttton depth probe measures only a single tunnel wall most frequently the anterior wall in 90° of knee flexion in most of the cases, which is assumed to be the longer wall of the femoral tunnel, however no supporting documents could be found in this regards. Intraoperatively measured femoral tunnel length using the Endobuttton Indicator Selection Device

were also longer than the actual measurements. The reason could be because with the Endobuttton Indicator Selection Device we usually performed a stab incision on the lateral aspect of the femur. Therefore, the impacting drill sleeve on the cortex of the lateral epicondylar area of femur, iliotibial band, and other soft tissues might have impinged between the cortex and the drill sleeve^[11].

There are some limitations to this study. The post-operative tunnel length was measured by selecting the plane in which maximum tunnel width was visible and the average of the short and the long tunnel wall length were taken as the measurements far the length of the femoral tunnel. Whereas the measurement using the Endobuttton depth probe was done as a diagonal measurement through the tunnel from the intra-articular tunnel margin. To increase the accuracy of femoral tunnel length measurement using Endobuttton depth probe device it would be better to remove soft tissue around femoral tunnel intra-articular aperture to determine the exact margin of the tunnel aperture, also it would be better to measure at the margin of the intraarticular aperture showing the shortest tunnel length, because this gauge might be read as a diagonal through the tunnel and measured a little longer. To increase the accuracy of intraoperative measurement of the femoral tunnel length in ACL reconstruction using an Endobuttton Indicator Selection Device, it would be better to perform minimal soft tissue dissection to the cortex of the femur after the stab incision to prevent soft tissue impingement and use an accurate tunnel length measurement tool. Additionally, 70-degree scope in measuring femoral tunnel length through AM portal would be helpful to position accurately 2.7-mm drill tip guide at over the anatomical footprint site for AM and PL bundles. Sometimes it is difficult to hook the Endobuttton depth probe over the outer femoral cortex whereas an additional small incision may be required in case of

Endobutton Indicator device to prevent the soft tissue impingement but this incision can be used to confirm the correct placement of the Endobutton device on the lateral femoral cortex.

Conclusion

The intraoperatively measured femoral tunnel length using Endobutton indicator selection device as well as the Endobutton depth probe were longer than that measured postoperatively using CT. The mean femoral tunnel length measured using the Endobutton Indicator Selection Device was longer than the mean length measured using the Endobutton depth probe but the actual mean difference was just 0.7mm. To sum up the Endobutton Indicator Selection Device can be an alternative to the Endobutton depth probe as the difference of measurements obtained using either of the device is very small added to the advantage that the Endobutton indicator selection device is easy to use and give measurements for selection of the correct size of Endobutton.

Conflicts of interest: No conflict of interest is present in this study.

References

- Basdekis G, Abisafi C, Christel P. Effect of knee flexion angle on length and orientation of posterolateral femoral tunnel drilled through anteromedial portal during anatomic double-bundle anterior cruciate ligament reconstruction. *Arthroscopy: the journal of arthroscopic & related surgery: official publication of the Arthroscopy Association of North America and the International Arthroscopy Association.* 2009; 25(10):1108-1114. doi:10.1016/j.arthro.2009.05.018
- Bedi A, Altchek DW. The "footprint" anterior cruciate ligament technique: an anatomic approach to anterior cruciate ligament reconstruction. *Arthroscopy: the journal of arthroscopic & related surgery: official publication of the Arthroscopy Association of North America and the International Arthroscopy Association.* 2009; 25(10):1128-1138. Doi: 10.1016/j.arthro.2009.03.008
- Bedi A, Raphael B, Maderazo A, Pavlov H, Williams RJ. Transtibial versus anteromedial portal drilling for anterior cruciate ligament reconstruction: a cadaveric study of femoral tunnel length and obliquity. *Arthroscopy: the journal of arthroscopic & related surgery: official publication of the Arthroscopy Association of North America and the International Arthroscopy Association.* 2010; 26(3):342-350. Doi:10.1016/j.arthro.2009.12.006
- Chang CB, Choi JY, Koh IJ, Lee KJ, Lee KH, Kim TK *et al.* Comparisons of femoral tunnel position and length in anterior cruciate ligament reconstruction: modified transtibial versus anteromedial portal techniques. *Arthroscopy: the journal of arthroscopic & related surgery: official publication of the Arthroscopy Association of North America and the International Arthroscopy Association.* 2011; 27(10):1389-1394. Doi: 10.1016/j.arthro.2011.06.013
- Fauno P, Kaalund S. Tunnel widening after hamstring anterior cruciate ligament reconstruction is influenced by the type of graft fixation used: a prospective randomized study. *Arthroscopy: the journal of arthroscopic & related surgery: official publication of the Arthroscopy Association of North America and the International Arthroscopy Association.* 2005; 21(11):1337-1341. doi:10.1016/j.arthro.2005.08.023
- Ferretti M, Ekdahl M, Shen W, Fu FH. Osseous landmarks of the femoral attachment of the anterior cruciate ligament: an anatomic study. *Arthroscopy: the journal of arthroscopic & related surgery: official publication of the Arthroscopy Association of North America and the International Arthroscopy Association.* 2007; 23(11):1218-1225. doi:10.1016/j.arthro.2007.09.008
- Golish SR, Baumfeld JA, Schoderbek RJ, Miller MD. The effect of femoral tunnel starting position on tunnel length in anterior cruciate ligament reconstruction: a cadaveric study. *Arthroscopy: the journal of arthroscopic & related surgery: official publication of the Arthroscopy Association of North America and the International Arthroscopy Association.* 2007; 23(11):1187-1192. doi:10.1016/j.arthro.2007.06.013
- Hamilton SC, Jackson ER, Karas SG. Anterior cruciate ligament femoral tunnel drilling through anteromedial portal: axial plane drill angle affects tunnel length. *Arthroscopy: the journal of arthroscopic & related surgery: official publication of the Arthroscopy Association of North America and the International Arthroscopy Association.* 2011; 27(4):522-525. doi:10.1016/j.arthro.2010.10.002
- Hensler D, Working ZM, Illingworth KD, Tashman S, Fu FH. Correlation between femoral tunnel length and tunnel position in ACL reconstruction. *The Journal of bone and joint surgery American volume.* 2013; 95(22):2029-2034. Doi: 10.2106/JBJS.L.01315
- Iyyampillai G, Raman ET, Rajan DV, Krishnamoorthy A, Sahanand S. Determinants of Femoral Tunnel Length in Anterior Cruciate Ligament Reconstruction: CT Analysis of the Influence of Tunnel Orientation on the Length. *Knee surgery & related research.* 2013; 25(4):207-214. Doi: 10.5792/ksr.2013.25.4.207
- Kim JG, Wang JH, Ahn JH, Kim HJ, Lim HC. Comparison of femoral tunnel length between transportal and retrograde reaming outside-in techniques in anterior cruciate ligament reconstruction. *Knee surgery, sports traumatology, arthroscopy: official journal of the ESSKA.* 2013; 21(4):830-838. doi:10.1007/s00167-012-2024-4
- L'Insalata JC, Klatt B, Fu FH, Harner CD. Tunnel expansion following anterior cruciate ligament reconstruction: a comparison of hamstring and patellar tendon autografts. *Knee surgery, sports traumatology, arthroscopy: official journal of the ESSKA.* 1997; 5(4):234-238. doi:10.1007/s001670050056
- Lubowitz JH, Konicek J. Anterior cruciate ligament femoral tunnel length: cadaveric analysis comparing anteromedial portal versus outside-in technique. *Arthroscopy: the journal of arthroscopic & related surgery: official publication of the Arthroscopy Association of North America and the International Arthroscopy Association.* 2010; 26(10):1357-1362. Doi: 10.1016/j.arthro.2010.02.014
- Nebelung W, Becker R, Merkel M, Ropke M. Bone tunnel enlargement after anterior cruciate ligament reconstruction with semitendinosus tendon using Endobutton fixation on the femoral side. *Arthroscopy: the journal of arthroscopic & related surgery: official publication of the Arthroscopy Association of North America and the International Arthroscopy Association.* 1998; 14(8):810-815.

15. Qi L, Chang C, Jian L, Xin T, Gang Z. Effect of varying the length of soft-tissue grafts in the tibial tunnel in a canine anterior cruciate ligament reconstruction model. *Arthroscopy: the journal of arthroscopic & related surgery: official publication of the Arthroscopy Association of North America and the International Arthroscopy Association*. 2011; 27(6):825-833. Doi: 10.1016/j.arthro.2011.01.016
16. Robin BN, Lubowitz JH. Disadvantages and Advantages of Transtibial Technique for Creating the Anterior Cruciate Ligament Femoral Socket. *The journal of knee surgery*, 2014. Doi: 10.1055/s-0034-1382812
17. Sabat D, Kundu K, Arora S, Kumar V. Tunnel widening after anterior cruciate ligament reconstruction: A prospective randomized computed tomography--based study comparing 2 different femoral fixation methods for hamstring graft. *Arthroscopy: the journal of arthroscopic & related surgery: official publication of the Arthroscopy Association of North America and the International Arthroscopy Association*. 2011; 27(6):776-783. Doi: 10.1016/j.arthro.2011.02.009
18. Tompkins M, Milewski MD, Carson EW, Brockmeier SF, Hamann JC, Hart JM *et al*. Femoral tunnel length in primary anterior cruciate ligament reconstruction using an accessory medial portal. *Arthroscopy: the journal of arthroscopic & related surgery: official publication of the Arthroscopy Association of North America and the International Arthroscopy Association*. 2013; 29(2):238-243. Doi: 10.1016/j.arthro.2012.08.019
19. Yamazaki S, Yasuda K, Tomita F, Minami A, Tohyama H. The effect of intraosseous graft length on tendon-bone healing in anterior cruciate ligament reconstruction using flexor tendon. *Knee surgery, sports traumatology, arthroscopy: official journal of the ESSKA*. 2006; 14(11):1086-1093. Doi: 10.1007/s00167-006-0110-1
20. Zantop T, Ferretti M, Bell KM, Brucker PU, Gilbertson L, Fu FH *et al*. Effect of tunnel-graft length on the biomechanics of anterior cruciate ligament-reconstructed knees: intra-articular study in a goat model. *The American journal of sports medicine*. 2008; 36(11):2158-2166. Doi: 10.1177/0363546508320572