

E-ISSN: 2395-1958
P-ISSN: 2706-6630
IJOS 2019; 5(4): 124-129

www.orthopaper.com
Received: 09-08-2019
Accepted: 13-09-2019

Dr. Anand Gupta
Resident, Orthopaedics
Maharaja Agrasen Hospital,
New Delhi, India

Dr. Saurabh Khare
Resident, Orthopaedics
Maharaja Agrasen Hospital,
New Delhi, India

Dr. Arun Gulati
Senior Resident, Orthopaedics
Kalpana Chawla Govt. Medical
College, Karnal, Haryana, India

Dr. Shah Meghal Gautambhai
Senior Resident, Orthopaedics
Sanjay Gandhi Memorial,
New Delhi, India

Dr. Puneet Kamra
Senior Resident, Orthopaedics
Maharaja Agrasen Medical
College, Agroha, Haryana, India

Corresponding Author:
Dr. Arun Gulati
Senior Resident, Orthopaedics
Kalpana Chawla Govt. Medical
College, Karnal, Haryana, India

Clinical course of treatment of proximal one third ulna fracture by plate osteosynthesis in skeletally mature individuals

Dr. Anand Gupta, Dr. Saurabh Khare, Dr. Arun Gulati, Dr. Shah Meghal Gautambhai and Dr. Puneet Kamra

DOI: https://doi.org/10.22271/ortho.2019.v5.i4c.1659

Abstract
Objective: To study the clinical course including radiological union, fracture union time and functional outcome of plate osteosynthesis for proximal one third ulna fracture in skeletally mature individuals.
Method: 30 patients of proximal ulna fractures who were treated by plate osteosynthesis were included in this study.
Result: 30 patients were followed up for minimum duration of 6 months and the clinical outcomes were assessed according to the Mayo Elbow Performance Score (MEPS). Out of 30, our study included 21 olecranon fractures and 9 monteggia fractures. At final follow up of 6 month, our case series of olecranon fractures resulted mean MEPS of 89.3with 57.1% excellent results and 42.9 % good results, and all patients returning to pre-injury daily activities. For monteggia fractures, resulted mean MEPS score is 93.8 with 88.9% excellent result & 11.1 % good results. All fractures in our study had united by 6 months, both clinically and radiologically. Our study group had reported the complication of delayed union in 6 cases of olecranon fractures. No complications reported in treatment of monteggia fractures.
Conclusion: Our study has yielded excellent results in respect of functional outcome, radiological and clinical union without any implant related complications in internal fixation of proximal one third ulna fracture including olecranon fractures and monteggia fractures with plate osteosynthesis. Monteggia fractures treated with plate osteosynthesis yielded slightly better outcome in respect of functional outcome, radiological and clinical union than olecranon fractures. Plate osteosynthesis can be done in comminuted along with non-comminuted proximal one third ulna fractures. We recommend plate osteosynthesis for proximal one third ulna fracture, because of its consistent results with respect to fracture union, stability across the fracture site and early mobilization for better functional results.

Keywords: treatment of proximal, third ulna fracture, skeletally mature individuals

Introduction

Proximal one third ulna fractures are common adult injuries that account for approximately 10% of fractures around the elbow. These fractures comprise broad spectrum of injuries that include olecranon fractures and monteggia fracture dislocations [1]. Monteggia fracture dislocations are fracture of ulna with ligamentous failure of proximal radius resulting in dislocation of radial head [1, 2, 3]. Olecranon fractures typically result from a direct blow to the olecranon.

Proximal one third ulna fractures are commonly associated with coronoid and radial head fractures which are the negative prognostic factors. It should be treated appropriately followed by early mobilization for better outcome.

While dealing with Monteggia fracture dislocations, anatomical ORIF of the ulna with stable fixation almost always (90%) allows closed reduction of the radial head dislocation. Poor reduction of the ulna may result in persistent dislocation of the radial head.

The aim of treatment of olecranon fracture is to restore early, active, elbow motion in order to prevent joint stiffness. Open reduction and stable internal fixation with the goal of anatomical reduction of the articular surface is the gold standard for olecranon fracture treatment. Olecranon fractures can be treated by tension band wiring or plate osteosynthesis. Tension band wiring can only be used in non-comminuted fractures.

It has many pitfalls like loss of fixation, prominence of hardware, biceps tuberosity impingement, synostosis, ulnar and median nerve injury. Use of plate osteosynthesis avoids these complications and can also be used in comminuted along with non-comminuted fractures. It also provides structural stability, resists ulnar angulation, and restores ulna length [4]. In addition, plate fixation lowers the risk of fatigue failure caused by extreme bending stresses [5].

Material and Method

This hospital based prospective study was conducted in the Department of Orthopaedics at Maharaja Agrasen Hospital, New Delhi from July 2015 to March 2017. Thirty skeletally mature consecutive patients who present to the Department of Orthopaedics with fresh proximal one third ulna fracture not more than 1 month old were selected.

Inclusion criteria

1. Skeletally mature patients (More than 18 years of age) with Proximal one third ulna fracture which includes olecranon fractures and monteggia fracture dislocations.
2. Patient with compound Gustilo Anderson Grade 1 proximal one third ulna fracture who are fit for primary plate osteosynthesis.

Exclusion criteria

1. Patients who are unfit for surgery due to the associated comorbidities.
2. Patients with age less than 18 years
3. Patients with pathological fractures.
4. Patients with late presentation.(>4weeks)

Surgical approach

- Posterior midline approach to ulna was used in olecranon fractures
- Boyd's approach was used in monteggia fractures

Posterior midline approach

After cleaning and draping, Skin incision is made proximal to the tip of the olecranon as needed for access to the injured area. The skin incision was curved slightly medially around the tip of the olecranon, and distally for a few centimeters, as needed to provide access to the injured area.

In the proximal portion, the subcutaneous tissue was dissected and elevated. Over the olecranon, the olecranon bursa was removed and the triceps aponeurosis was incised exposing the bone. Behind the medial humeral epicondyle, the ulnar nerve was identified & protected. Flexor carpi ulnaris tendon was detached on the medial side, and the anconeus tendon on the lateral side as far as necessary to expose the involved articular surfaces and for an anatomical reduction and stable fixation.

For proximal ulna fractures extending into the diaphysis, the posterior approach was extended distally. The muscle origins (Anconeus, flexor carpi ulnaris and extensor carpi ulnaris) was detached from the ulna as needed to reduce and fix the fractures.

In proximal ulna injuries associated with radial head fracture, the incision was started 7 cm proximal to the tip of the olecranon. Anconeus muscle was detached and radial head was approached. In others, the subcutaneous tissues were dissected and elevated laterally exposing the septum between the anconeus and the extensor carpi ulnaris muscles to approach the radial head.

In fractures of the olecranon combined with a type II or III coronoid fracture, a medial extension of the posterior incision was made. The incision was taken 7 cm proximal to the tip of the olecranon. The ulnar nerve was dissected and isolated. The subcutaneous flap was elevated medially and the septum between the pronator teres and the common flexor tendon was exposed. The space between these muscles was dissected and elevated and freed from the elbow joint capsule.

Boyd's approach

The skin incision was taken proximal to the elbow and lateral to the triceps tendon. It was curved distally over the lateral aspect of the tip of the olecranon, and continues along the subcutaneous border of the ulna. The deep fascia was incised in line with the incision in order to approach the lateral margin of the ulna between the anconeus insertion and the flexor carpi ulnaris. The fracture ends was exposed with minimal soft tissue dissection of the bone.

Fixation

The fracture ends were exposed with minimal soft tissue dissection off the bone. Hematoma was removed and irrigated. The fracture was reduced with the help of two small pointed reduction forceps and was provisionally fixed with two K-wires or reduction clamps. The plate was contoured according to the surface anatomy of the ulna. A slight convex bend was placed over the fracture to ensure compression of the opposite cortex. A 3.5 mm cortical screw was applied in neutral position into the proximal fragment next to the fracture. Another 3.5mm cortical screw was inserted in eccentric position into the distal fragment, next to the fracture, creating compression across the fracture.

The rest of the screws was inserted in neutral position. Final adjustments of plate, if needed, was done before final tightening of the screws. Finally, after fixing ulna, the range of motion in pronation, supination, flexion and extension was assessed. Stability of fixation was checked. Wound was closed in layers. Limb was kept in above elbow slab and arm sling after wound dressing.

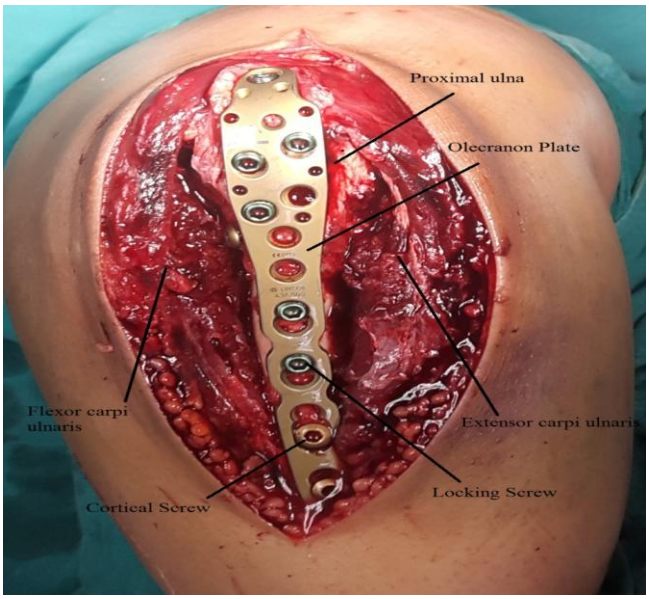

Implant details

We used 3.5 mm LCP olecranon plate for olecranon fracture fixation. For Monteggia fracture fixation 3.5 mm dynamic compression plate (DCP) or 3.5 mm limited contact dynamic compression plate (LC-DCP), or 3.5 mm locking plate (LCP) was used.





Results

The clinical outcomes were assessed according to the Mayo Elbow Performance Score. Four parameters (pain, range of motion, function and stability of elbow) were included for evaluation. Maximum points for pain given were 45, for range of motion were 20, for function were 25 and for stability of elbow were 10. Based on the total score, functional outcome were graded as Excellent (>90 points), good (75-89), fair (60-74) and poor (<60).

Out of 30, our study included 21 olecranon fractures and 9 monteggia fractures which includes 13 Mayo type II A olecranon fracture, 4 Mayo Type IIB olecranon fracture, 4 Mayo type IIIA olecranon fracture, 6 Bado Type I Monteggia fracture, 3 Bado Type II Monteggia fracture. Patients were evaluated both clinically and radiologically at 6 weeks, 3 months, and 6 months for the following:

- Radiological documentation of fracture healing course.
- Evaluation of any possible loss of reduction that might have occurred, compared to immediate post-operative radiographs.
- Functional assessment using Mayo Elbow Performance Score.
- Assessment and analysis of any complication observed.

At final follow up of 6 month, our case series of olecranon fractures resulted mean MEPS of 89.3with 57.1% excellent results and 42.9 % good results, and all patients returning to pre-injury daily activities. For monteggia fractures, resulted mean MEPS score is 93.8 with 88.9%excellent result & 11.1 % good results.

All fractures in our study had united by 6 months, both clinically and radiologically. Our study group had reported the complication of delayed union in 6 cases of olecranon fractures. No complications reported in treatment of monteggia fractures.

Pre operative Xray

6 month Post Op Xray

Flexion at 6 months

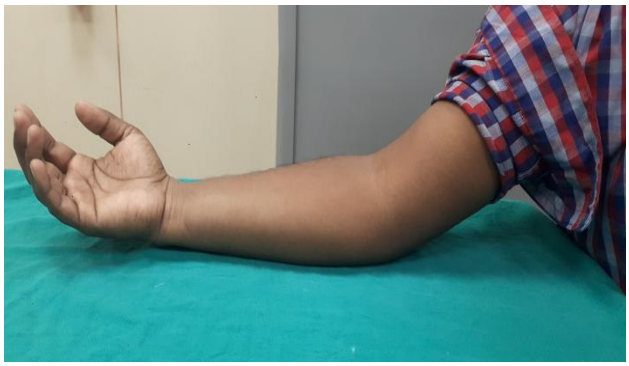

Extension at 6 months

Case 1: Olecranon fracture

Supination at 6 months

Pronation at 6 months

Pre operative xray

6 month post Op xray

Flexion at 6 months

Extension at 6 months

Pronation at 6 months

Supination at 6 months

Case 2: Monteggia fracture

Discussion

The elbow plays a critical part in the normal arm functioning. Fractures of proximal ulna threaten the integrity of both the elbow and forearm joints. The treatment goals are to maintain a stable and anatomic reduction, realign the longitudinal axis of the proximal ulna, and enable immediate rehabilitation. Various treatment options are available for management of such fractures. Initially these fractures were managed by closed reduction and splintage, later treatment was shifted towards open reduction and fixation. Techniques for surgical management varies from tension band wiring to plate fixation. In 1814, Giovanni Battista Monteggia [6] described a fracture of the shaft of the ulna associated with an anterior dislocation of the radial head. He managed the injury by closed reduction

and splintage which was suboptimal and resulted in recurrence of the radial head subluxation. Traditionally these fractures were used to be treated by closed reduction but Stimson (1907) [6] treated series of 10 patients with proximal ulna fractures by an open reduction technique instead of fracture manipulation and closed reduction. Later Speed and Boyd (1940) [7] suggested that a closed reduction of Monteggia fracture dislocation often resulted in poor outcomes and made several recommendations. For adults with acute injury, they advocated the use of an open reduction and fixation of the ulna fracture using vitallium plates and reduction of dislocated radial head through a single lateral incision. In 1967, Bado [2] classified Monteggia injuries under the term Monteggia lesion, which included types I-IV according to the level and angulation of ulna shaft fracture and the direction of dislocation of the radial head. In addition to these 4 types, Bado described a Monteggia equivalent injury that differed in radiological appearance but possessed similar characteristics especially in the mechanism of injury and in its treatment.

D Macko *et al*. (1985) [8] analysed Complications of tension-band wiring of olecranon fractures. Most common complication was symptomatic prominence of the Kirschner wires at the elbow. There was skin breakdown in few patients and infection in other. Measurable proximal migration of the Kirschner wire also occurred. In 1992, Hume MC *et al*. [9] studied clinical and radiographic comparison of tension band wiring and plate fixation in olecranon fractures and concluded that tension band wiring resulted in 37% good clinical and 47% good roentgenographic results, as compared with plate fixation, which resulted in 63% good clinical and 86% good roentgenographic results. Bailey CS *et al*. (2001) [10] evaluated the functional outcome of plate fixation for displaced olecranon fractures, both simple and comminuted and concluded that plate fixation is an effective treatment option for displaced olecranon fractures with a good functional outcome and a low incidence of complications. Anderson *et al* (2007) [11] has done a retrospective study on clinical results and patient outcomes following treatment of olecranon fractures with a congruent elbow plating system and concluded that congruent anatomic plating is a safe, effective option for the treatment of olecranon fractures with a low rate of hardware removal and stability with early motion.

Kloen P *et al*. (2009) [12] treated 26 patients of olecranon fracture and proximal ulna fractures (including monteggia fractures) by dorsal pating. All fractures united at an average 4.8 months duration. At follow-up after an average of 18 months, range of motion was on average 132 degrees /18 degrees of flexion/extension, and 75 degrees /70 degrees of pronation/supination. Early mobilization also prevented ulnohumeral arthritis.

Dominique M Rouleau *et al*. (2013) [13] stated that proximal ulna fractures can be difficult to manage because of the elbow's complex anatomy. Careful preoperative evaluation is critical because failure to restore normal anatomy of the proximal ulna could have a detrimental effect on postoperative elbow function. Determining the most appropriate option for an individual fracture is based on analysis of radiographs and CT scans, including three-dimensional reconstruction. Coronoid fractures, olecranon fractures, and associated elbow instability influence the indications for any given fixation device. Appreciating the subtleties of proximal ulna anatomy and biomechanics can lead to improved clinical outcomes. Recent concepts affecting fracture management include proximal ulna dorsal angulation, the importance of the anteromedial facet of the coronoid, and intermediate fragments of the olecranon. John A. Scolaro *et al* (2015) [14] made a study and stated that stable anatomic fixation of the ulna is essential to the treatment of both posterior monteggia and transolecranon fracture – dislocations of the elbow. The goal of surgical fixation in elbow fracture dislocation is a stable reduced joint that will tolerate immediate postoperative range of motion.

Gruszka D *et al*. (2015) [15] studied the comparison of the stability of a novel olecranon tension plate (OTP) with tension band wiring in a simulated fracture model and concluded that The concept of replacing prominent K-wires at the proximal end of the ulna using an low-profile plate with classical lag and multidirectional angle-stable screws demonstrated biomechanical advantages over tension band wiring.

In 2016 Wegmann K *et al*. [16] studied monteggia like proximal ulna fracture fixation and De Giacomo AF *et al*. [17] studied olecranon fracture fixation by different fixation devices in separate studies, and concluded the superiority of plating over other fixation devices.

Open reduction and stable internal fixation with the goal of anatomical reduction of the articular surface is the gold standard for olecranon fracture treatment. Olecranon fractures can be treated by tension band wiring or plate osteosynthesis, Tension band wiring can only be used in non-comminuted fractures. It has many pitfalls which can be avoided by the use of plate osteosynthesis and this can also be used in comminuted along with non-comminuted fractures.

Operative treatment by plate osteosynthesis has been shown to provide more predictable alignment & immediate fracture stability, allowing early elbow mobilization.

We treated thirty patients with proximal one third ulna fractures by plate osteosynthesis. The results obtained in our study were favourable.

Conclusion

Our study has yielded excellent results in respect of functional outcome, radiological and clinical union without any implant related complications in internal fixation of proximal one third ulna fracture including olecranon fractures and monteggia fractures with plate osteosynthesis. Monteggia fractures treated with plate osteosynthesis yielded slightly better outcome in respect of functional outcome, radiological and clinical union than olecranon fractures. Plate osteosynthesis can be done in comminuted along with non-comminuted proximal one third ulna fractures. It minimises complications like loss of fixation, prominence of hardware, biceps tuberosity, impingement and synostosis, ulnar and median nerve injury. It also provides structural stability, resists ulnar angulation, and restores ulna length. In addition, plate fixation lowers the risk of fatigue failure caused by extreme bending stresses. We recommend plate osteosynthesis for proximal one third ulna fracture, because of its consistent results with respect to fracture union, stability across the fracture site and early mobilization for better functional results.

References

1. Jupiter JB, Leibovic SJ, Ribbans W, Wilk RM. The posterior Monteggia lesion. J Orthop Trauma. 1991; 5(4):395-402.
2. Bado JL. The Monteggia lesion. Clin Orthop. 1967; 50:71-86.
3. Ring D, Jupiter JB, Simpson NS. Monteggia fractures in adults. J Bone Joint Surg Am, 1998, 80.

4. Ring D. Monteggia fractures. Orthop Clin North Am. 2013; 44(1):59-66.
5. Buijze G, Kloen P. Clinical evaluation of locking compression plate fixation for comminuted olecranon fractures. J Bone Joint Surg Am. 2009; 91(10):2416-2420.
6. Rehim SA, Maynard MA, Sebastin SJ, Chung KC. Monteggia fracture dislocations: a historical review. J Hand Surg Am. 2014; 39(7):1384-1394.
7. Speed JS, BOYD HB. Treatment of fractures of ulna with dislocation of head of radius: (*Monteggia fracture*). Journal of the American Medical Association. 1940; 115(20):1699-1705.
8. D Macko Szabo RM. Complications of tension-band wiring of olecranon fractures. J Bone Joint Surg Am. 1985; 67(9):1396-1401.
9. Hume MC, Wiss DA. Olecranon fractures. A clinical and radiographic comparison of tension band wiring and plate fixation. Clin Orthop Relat Res. 1992; (285):229-235.
10. Bailey CS, MacDermid J, Patterson SD, King GJ. Outcome of plate fixation of olecranon fractures. J Orthop Trauma. 2001; 15(8):542-548.
11. Anderson ML, Larson AN, Merten SM, Steinmann SP. Congruent elbow plate fixation of olecranon fractures. J Orthop Trauma. 2007; 21(6):386-393.
12. Kloen P, Buijze GA. Treatment of proximal ulna and olecranon fractures by dorsal plating. Oper Orthop Traumatol. 2009; 21(6):571-585.
13. Rouleau DM, Sandman E, van Riet R, Galatz LM. Management of fractures of the proximal ulna. J Am Acad Orthop Surg. 2013; 21(3):149-160.
14. Scolaro JA, Beingessner D. Treatment of Monteggia and Transolecranon Fracture-Dislocations of the Elbow: A Critical Analysis Review. J Bone Joint Surg Rev. 2014; 2(1).
15. Gruszka D, Arand C, Nowak T, Dietz SO, Wagner D, Rommens P. Olecranon tension plating or olecranon tension band wiring? A comparative biomechanical study. Int Orthop. 2015; 39(5):955-960.
16. Wegmann K, Engel K, Skouras E, Hackl M, Müller LP, Hopf JC *et al*. Reconstruction of Monteggia-like proximal ulna fractures using different fixation devices: A biomechanical study. Injury. 2016; 47(8):1636-1641.
17. De Giacomo AF, Tornetta III P, Sinicrope BJ, Cronin PK, Althausen PL, Bray TJ *et al*. Outcomes after plating of olecranon fractures: a multicenter evaluation. Injury. 2016; 47(7):1466-1471.