



International Journal of Orthopaedics Sciences

ISSN: 2395-1958
IJOS 2019; 5(3): 04-07
© 2019 IJOS
www.orthopaper.com
Received: 04-05-2019
Accepted: 08-06-2019

Dr. M Venkataramana Rao
Professor and Unit Chief,
Department of Orthopaedics,
SSIMS & RC, Davangere,
Karnataka, India

Dr. P Venkatesh
Resident, Department of
Orthopaedics, SSIMS & RC,
Davangere, Karnataka, India

Dr. Kiran GU
Assistant Professor, Department
Of Orthopaedics, SSIMS & RC,
Davangere, Karnataka, India

Dr. Sachin S Nimbergi
Associate Professor, Department
Of Orthopaedics, SSIMS & RC,
Davangere, Karnataka, India

A prospective study of surgical management of distal end radius fractures using variable angle locking compression plate

Dr. M Venkataramana Rao, Dr. P Venkatesh, Dr. Kiran GU and Dr. Sachin S Nimbergi

DOI: <https://doi.org/10.22271/ortho.2019.v5.i3a.1497>

Abstract

Aim: To assess the clinical and functional outcome of surgically treated distal radius fractures with variable angle locking compression plate at SSIMS-RC, Davangere during August 2016 TO June 2018.

Objectives: 1.To evaluate the radiological union in fractures of distal radius fixed with variable angle LCP, 2. To evaluate clinical and functional outcome associated with this treatment modality, 3. to study the complications associated with this study.

Materials and methods: 28 cases of distal radius fractures surgically treated with variable angle LCP according to inclusion and exclusion criteria, all patients followed up for a period of 1 year and results assessed with Gartland and Werely classification.

Results: In our study mean duration of complete radiological union was 11weeks which is comparable with other studies. We have achieved excellent results in 66.6% of cases, good results in 23.3%, fair results 10%, and no poor results. Complications like stitch abscess, reduced range of motion, complex regional pain syndrome seen in 6(20%) cases.

Conclusion: The results are evidence that Variable angle locking plates allows effective anatomic realignment and early wrist mobilization. It is biomechanically superior due to closer joint interface placement and better screw placement in different directions. Variable angle locking compression plates in distal radius fractures provide good to excellent results and are effective in the correction and maintenance of distal radius anatomy.

Keywords: Variable angle locking compression plate (VA-LCP), surgical management, distal radius fracture

Introduction

Fracture of the distal end radius are one of the most common skeletal injuries of the upper extremity, encountered in practice. Restoration of radial length, radial tilt and congruity of articular surfaces is important for good functional results [1] Failure to achieve and maintain near anatomic restoration can lead to various deformities and disabilities. Closed reduction and cast immobilization has been one of the modalities and mainstay of treatment of these fractures leading to complications like malunion, subluxation /dislocation of distal radioulnar joint resulting in poor functional and cosmetic outcome [2]. Later studies have advised operative treatment with open reduction and internal fixation with conventional T buttress plates, and more recently locking compression plates which have been used widely because of mechanical advantage [3, 4], Variable angle locking plate is a novel development of LCP is the recent method to fix simple to complex fractures of distal end radius [5]. Variable angle provide angular stability with fracture fragment specific fixation. Screws can be inserted into the place at various desired angles to fix the fracture fragment.

Materials and Methods

The study was conducted on 28 patients diagnosed with distal radius fracture admitted in SSIMS-RC teaching hospital, Davangere, surgically treated with variable angle LCP during the study period AUG 2016 to June 2018 The study is a clinical, prospective and observational study.

Correspondence
Dr. P Venkatesh
Resident, Department of
Orthopaedics, SSIMS & RC,
Davangere, Karnataka, India

After obtaining a detailed history, complete general physical and systemic examination, the patients were subjected to relevant investigations. Cases were selected according to inclusion and exclusion criteria.

Inclusion criteria: 1-Fractures of distal end radius of either side with or without ulnar styloid involvement, 2-AO Muller type23-C. 3-For fixation of complex intra- and extraarticular fractures. 4-Patients willing to participate in study. Age between 18-70 years.

Exclusion criteria: 1-Pathological fractures. 2-Skeletally immature patients. 3-Non union and Delayed presentation of fractures more than 2 weeks.

Patients admitted with distal radius fractures were classified under AO and Gartland and Werley classification.

Implant used: The VALCP distal radius plate is a 2.7mm low profile stainless steel and titanium plate with a 26° distal volar tilt that allows for optimal anatomic fracture reduction and restoration of radial inclination. The distal articular end of the plate consists of 4 locking holes for 2.7mm locking screws angled at 15°. The shaft of the plate consists of combi holes for insertion of 3.5mm locking or cortical screws [5, 6].

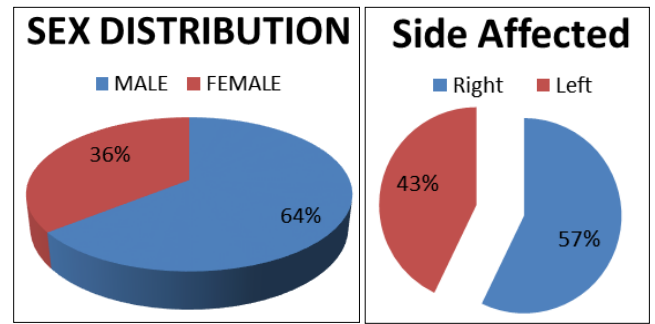
Operative procedure

Description: Modified Henry’s approach or trans- flexor carpi radialis (FCR) approach between the radial artery and FCR tendon. With the forearm in supination A longitudinal skin incision was used in line with the FCR tendon. The length of the incision depends on the plate size. The fascia was released to expose the FCR tendon, which was mobilized by incising the sheath. The tendon was then retracted in an ulnar direction and an incision made in the floor of the tendon sheath. This exposed the flexor pollicis longus (FPL) muscle belly, which was swept to the ulnar side by blunt dissection. The transverse muscle fibers of pronator Quadratus were then evident and released from the radial side of the radius and elevated Subperiosteally from the radius in a volar direction. The fracture line was clearly visualised and reduced by manipulation and ligamentotaxis. Provisional k-wires were used to maintain reduction. The appropriate plate with 2.7mm locking screws which were inserted at various desired angles upto 15° and 3.5mm cortical and locking screws were applied. Pronator Quadratus sutured covering the distal end of plate to prevent tendon irritation. Image intensifier used to assist the evaluation of fracture reduction and fixation. Patients with unstable fractures, the wrist immobilised in a below elbow splint for 4 weeks. Patients were allowed to start wrist movements at an average of four weeks post operatively. After the discharge, patient were followed at regular intervals every 4 weeks for 4months, then at 6 months and 1year. Subjective and objective functional results were graded using Demerit point system of Gartland and Werley.

Results

30 cases of distal radius fractures were treated surgically by variable angle locking compression plate in S.S Hospital, treated between august 2016 to June 2018. All cases were followed up Regularly, Average age in our study was 45.2 years. We evaluated our results and compared the functional outcomes with various other studies. There were 18 male patients (64%), 10 female patients (36%) in our study majority being male patients [Graph 1]. The right side

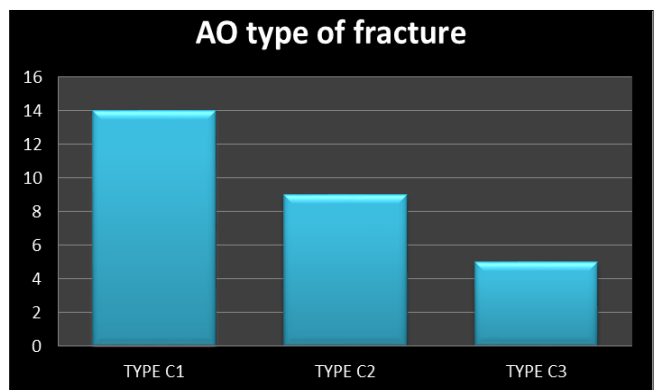
(dominant wrist) was involved in 16(57%) cases and 12(43%) involved in left side [Graph 2].



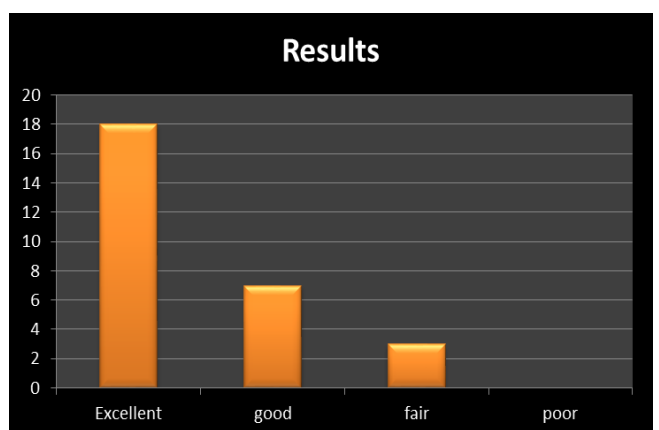
Graph 1: Sex distribution

Graph 2: Side affected

In our study 11 (36%) patients had road traffic accident and 17(64%) had a Domestic fall. Types C₁ muller’s fracture was the most common fracture type 14 out of 28 [Graph 3]. Out of 28 cases 5 (18%) patients had associated injuries. In which one patient had Ipsilateral fracture both bone leg, three patient had Head injury and one patient had Ipsilateral humerus fracture. In our study 23 (82%) patients had union within 2-3.months and 5 (18%) patients had union in 3-4 months. There was no case of delayed union. Mean time for radiological union was 11 weeks.



Graph 3: AO type of fracture



Graph 4: Results

We encountered a complication rate of 14%, out of which 1 (3.5%) was due to infection (stich abscess), 2 (7%) developed reduced range of movements and 1(3.5%) developed complex regional pain syndrome (CRPS). In our series, we had 64.3% excellent, 25% good, 10.7%, fair and no poor results[Graph 4].

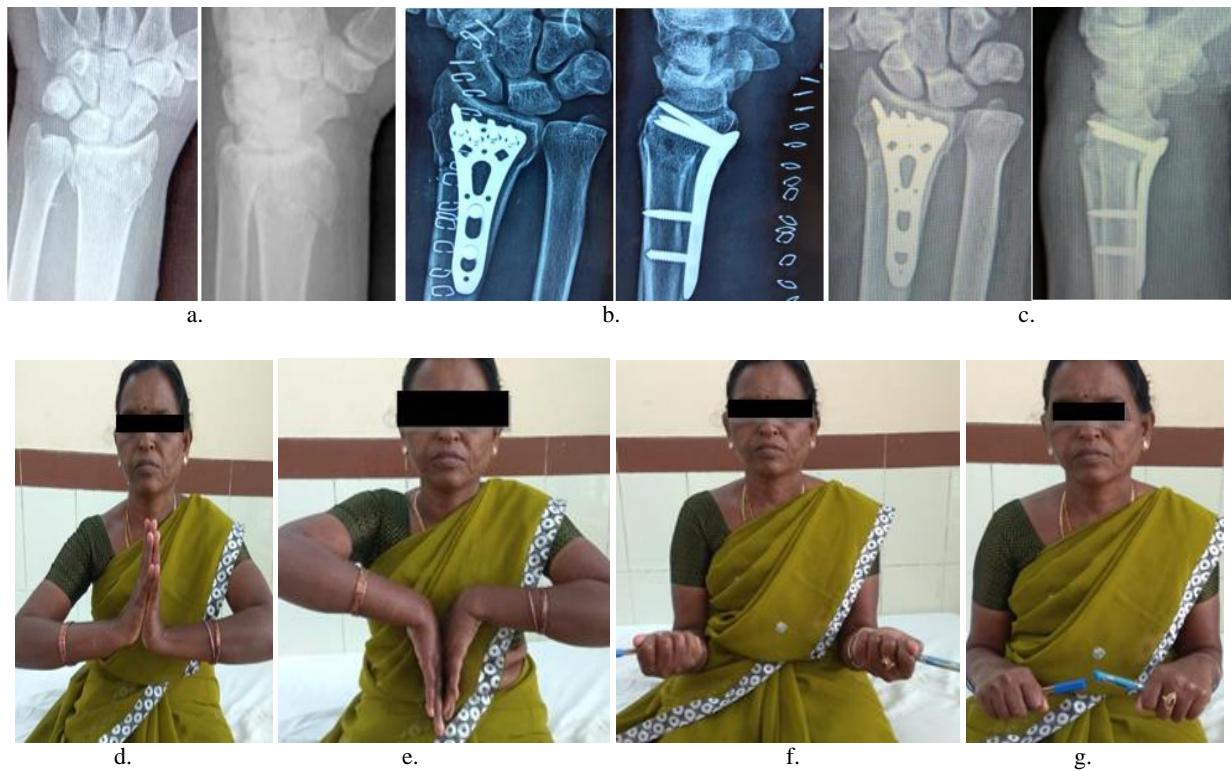


Fig 1: A 45 Yr Old Female With A. Distal Radius Fracture AO/OTA Type C1 B. Immediate Post Op Xray Of Same Patient With Distal Radius VALCP C.X-Ray Of The Patient At 6 Months Follow U, Clinical Images Of Patient With D. Dorsiflexion, E. Palmar Flexion, F. Supination, G. Pronation.

Discussion

Distal radius fractures are the most common fractures encountered in routine orthopaedic practice, restoration of articular anatomy is important for normal functioning. A combination of an improved understanding of distal radial anatomy, patient demands and the new fixation devices have changed the management of distal radial fractures. Locking plates are preferred in osteoporotic and in multiple complex fractures. During the recent years, volar approach has become more popular. Variable angle LCP is the newer implant in the treatment of comminuted intra-articular fractures of distal end of radius. Variable-angle locking compression plates (VALCPs) have increased versatility in subchondral screw placement while maintaining the advantages of a standard fixed-angle locking plates. In particular, VALCPs facilitate surgeon-directed targeted placement of the subchondral screws that can potentially maximize fracture fragment fixation [7]. Our results are compared with various other studies, in various parameters like involved side, mode of injury, type of fractures etc.

In our study the right side (dominant wrist) was involved in 16 cases and left side involvement was 12, male patients were 18 and females were 10, majority of cases were due to domestic fall at home i.e., 17 cases vs 11 cases due to road traffic accident. AO/OTA classification was used in our study for classifying the fractures which included type 23C fractures, majority of cases fell into type 23C1 i.e., 14 cases vs 9 cases type 23C2, and 5 cases were type 23C3 [8]. Which helped in achieving better results in our study. We encountered Four complications (13.3%) in our study. one being stich abscess, 2 patients developed reduced range of movements and one case developed CRPS [9, 10].

In our series, we had 64.3% excellent, 25% good, 10.7%, fair and no poor results. Patients, who obtained excellent results, had normal regular activities or no pain. Range of motion was

within the normal functional range. Radial length, volar tilt and articular step-off were within acceptable limits. They underwent earlier physiotherapy. Patients with good results had minimal residual deformities, pain and slight limitation. Patients with fair results, along with residual deformity, pain and limitation also had pain in the distal radio-ulnar joint and minimal complications. Few of their movements were less than that required for normal function.

Table 1: Comparative study of various studies showing side of involvement

Study	Right side	Left side
R.E Anakwe <i>et al.</i> , (2010) [11]	15	6
Sanjay Agarwal (2012) [12]	11	14
Kavin Khatri (2015) [13]	17	6
William Marlow [14]	15	6
our study	16	12

Table 2: Comparative studies showing cause of fracture

Study	RTA	Domestic Fall
R.E Anakwe <i>et al.</i> , (2010) [11]	14	7
Sanjay Agarwal (2012) [12]	7	17
Kavin Khatri (2015) [13]	18	4
Our study	11	17

Table 3: Comparative studies showing results and complications of various studies

study	complication rate	results
R E Anakwe <i>et al.</i> , [11]	4.8%	95% very high satisfaction
Sanjay Agarwal <i>et al.</i> , [12]	4%	100% excellent results
Kavin Khatri <i>et al.</i> , [13]	21.7%	65% excellent, 35% good results
william Marlow <i>et al.</i> , [14]	7.69%	100% excellent results
our study	14	64.3% excellent, 25% good

Conclusion

A fall on a outstretched hand is the common mode of injury causing distal radius fractures. Distal radial fractures which occur due to road traffic accidents (high energy trauma) are mostly intra- articular, displaced and unstable Gartland and Werley group II and III and AO type B2, B3, C1,C2and C3^[8]. The results are evidence that Variable angle locking plates are good implant in the treatment of intra-articular unstable fractures of distal radius. It allows effective anatomic realignment and early wrist mobilization. It is biomechanically superior due to closer joint interface placement and better screwing capability in different directions. A successful anatomic alignment was made possible regardless of the direction of fracture angulation with Variable angle volar locking plate. 90% the patients went back to their daily activities with good recovery. Use of variable angle locking compression plates in distal radius fractures provide good to excellent results and are effective in the correction and maintenance of distal radius anatomy. By using these plates, joint motions and daily functioning is recovered in a shorter time. Hence Variable angle locking compression plate is a useful implant in fixing unstable and comminuted extraarticular distal radius fractures.

References

1. Weber ER. A rationale approach for the recognition and the treatment of Colle's fracture Hand Clin. 1987; 3:3-21.
2. Cooney WP III, Dobyns JH, Linscheid RL. Complications of colles' fractures. J Bone Joint Surg. 1980; 62-A:613.
3. Helfet DL, Haas NP, Schatzker J, *et al.* AO philosophy and principles of fracture management-its evolution and evaluation. J Bone Joint surg Am. 2003; 85:1156-1160.
4. Bagby GW. Compression bone-plating: historical considerations. J Bone Joint surg Am. 1977; 59:625-631.
5. Park JH, Hagopian J, Ilyas AM. Variable-angle locking screw volar plating of distal radius fractures. Hand Clin. 2010; 26:373-380.
6. Mark Lenz, Dieter Wahl, *et al.* Concept of variable angle locking-evolution and mechanical evaluation of a recent technology journal of Orthopaedic Research Society, 2015, 988-992.
7. John Fowler R, Asif Ilyas M. Prospective evaluation of distal radius fractures treated with variable-angle volar locking Plates Jhsa. 2013; 08:116.
8. Knirk JL, Jupiter JB. Intra-articular fractures of the distal end of the radius in young adults. Journal of Bone and Joint Surgery. 1986.
9. Schütz M, Kolbeck S, Spranger A, Arndt-Kolbeck M, Haas NP. Palmar plating with the locking compression plate for dorsally displaced fractures of the distal radius-first clinical experiences Zentralbl Chir. 2003; 128(12):997-1002.
10. Rikli DA, Regazzoni P. Fractures of the distal end of the radius treated by internal fixation and early function. A preliminary report of 20 cases. J Bone Joint.
11. Anakwe RE, Khan LAK, Cook RE, McEachan JE. Locked volar plating for complex distal radius fractures: Patient reported outcomes and satisfaction J Orthop Surg Res. 2010; 5:51.
12. Sanjay Agarwala, Ganesh Mohrir S, Shreyans D. Functional Outcome in Distal Radius Fractures Treated with Locking Compression Plate. Gadiya Bombay Hospital Journal. 2012; 54:2.
13. Kavin Khatari, Vijay Sharma, Kamran Farooque, Vivek

Tiwari. Surgical treatment of unstable distal radius fractures with a volar variable-angle locking plate: clinical and radiological outcomes. Arch Trauma Res. 2016; 5(2):e25174.

14. William Marlow J, Rohit Singhal, Sujay Dheerendra, Peter Ralte, Jochen Fischer, Mohammad Waseem. Distal radius volar locking plates: Does a variable angle locking system confer a clinical advantage?. Acta Orthop. Belg. 2012; 78:309-316.