



International Journal of Orthopaedics Sciences

ISSN: 2395-1958
IJOS 2019; 5(2): 77-83
© 2019 IJOS
www.orthopaper.com
Received: 27-02-2018
Accepted: 28-03-2018

Dr. Sahu Gaurav
Junior Resident, Department of
Orthopaedics, KIMS, Karad,
Maharashtra, India

Dr. Ravindra B Gunaki
Professor, Department of
Orthopaedics, KIMS, Karad,
Maharashtra, India

Dr. Nishant K Gaonkar
Associate Professor, Department
of Orthopaedics, KIMS, Karad,
Maharashtra, India

Dr. Somil Choudhary
Junior Resident, Department of
Orthopaedics, KIMS, Karad,
Maharashtra, India

A comparative study of functional outcome of ankle joint after medial malleolar fractures treated with ORIF with TBW and CC screws

**Dr. Sahu Gaurav, Dr. Ravindra B Gunaki, Dr. Nishant K Gaonkar and
Dr. Somil Choudhary**

DOI: <https://doi.org/10.22271/ortho.2019.v5.i2b.18>

Abstract

Aim: To analyse the functional outcome of Ankle joint after medial malleolar fracture treated with ORIF with TBW and CC Screws.

Materials and Method: This is prospective study done in Krishna medical college and hospital, karad (Satara). In this study 30 cases of Medial malleolar ankle fracture were analysed. Muller Classification used. Road traffic accident, Twisting injury and fall from height are major mode of injury. 4.0 mm Cannulated cancellous screw and TBW were used for fixation.

Results: According to Baird and Jackson scoring system out of the 30 patients treated, 86.66% had excellent to good results and 13.66% had fair results. On comparing the results in both groups, better results were seen in TBW group as compared to CCS group.

Conclusion: In this study we observed that the functional outcome of Ankle joint after medial malleolus fracture treated with open reduction and internal fixation with tension band wiring gives better results in range of motion and union as compared to open reduction and internal fixation with 4.0 mm cannulated cancellous screws.

Thus, we conclude that open reduction and internal fixation with tension band wiring give better functional and radiological outcomes as compared to cannulated cancellous screws.

Keywords: medial malleolar ankle fracture, muller classification and baird and jackson scoring system

Introduction

Ankle joints are highly susceptible to injuries. This is because they are relatively mobile and bear much of the stresses associated with weight bearing. The ankle joint supports more weight per unit area than any other joint in the body [1].

Ankle joint is the most congruous joint in the lower extremity bearing upto five times the body weight [2]. Sir Robert Jones said - Ankle is the most injured joint of the body but the least well treated [3]. Ankle injuries gain importance because body weight is transmitted through it and locomotion depends upon the stability of this joint. They are usually mixed injuries, ligamentous and bony and each injury is an end result of the sequence of ligamentous and bony failure due to deforming forces.

The French have written extensively on ankle injuries beginning with Baron, Dupuytren and then Maisonneuve, but it was not until 1922 that a proper understanding of the mechanism and classification of the ankle fractures was published in a paper by Ashurst and Bromer [4].

Fractures of the medial malleolus are one of the most common fractures encountered by an orthopaedic surgeon. Their incidence have increased over the last 30 years, affecting one in every 800 people each year, and accounting for 9% of all fractures. They continue to pose vexing problems as these being intraarticular are being subjected to continuous deforming forces. It is also difficult to restore the desired anatomical continuity and congruity of their articular surfaces after reduction.

In the modern age, the treatment of osteoarticular fractures with plaster immobilisation for prolonged period is not entirely justified particularly when the fracture is sustained by relatively younger people.

Correspondence
Dr. Ravindra B Gunaki
Professor, Department of
Orthopaedics, KIMS, Karad,
Maharashtra, India

Thus, conservative treatment of these fractures is becoming a thing of past. Furthermore in elderly patients, early mobilization and early ambulation is the ideal treatment of fractures [5].

The superiority of ORIF over closed treatment have been thoroughly demonstrated in literature [6]. With evolution and advances in orthopaedics, the mode of treatment of osteoarticular fracture has changed from closed reduction and plaster immobilisation to open reduction and internal fixation. In treating medial malleolar fractures, restoration of anatomical alignment is highly essential. This is because, only a slight variation from normal is incompatible with good joint function. Ramsey and Hamilton have reported that only 1mm lateral shift of talus decreases contact area by 40% and displacement of 3 mm decreases contact area by 60% [7].

Various implants made of stainless steel came into vogue. They included screws, k-wires, tension band wires etc. Open reduction and internal fixation is an excellent method for restoration of normal anatomy of the joint.

The study of Association of Osteosynthesis (AO) has evolved the methods of utilising rigid fixation and compression for internal fixation of fractures [5]. It works on principle that the implant absorbs tension and increases compression across fracture site and aims at full restoration of painless movement and strength.

However in today's age, when different implants and different modalities are available for the treatment of medial malleolar fractures, no method is perfect and each one has its pros and cons. It is important to individualize treatment modality for every patient and not to be restricted by rigid protocols.

So, aim of this study is to determine the outcome of medial malleolar fractures treated with open reduction and internal fixation with tension band wiring and 4 mm cannulated cancellous screws which will allow us to practice more efficiently.

Objectives

To evaluate the Ankle Function after medial malleolar fracture treated with open reduction Internal Fixation at the end of 6 months.

1. To analyse functional or cilinical outcomes operated with tension band wiring and cannulated cancellous screws.
2. To analyse radiological fracture union operated with tension band wiring and cannulated cancellous screws.
3. To compare complications of medial malleolar fractures operated with tension band wiring and cannulated cancellous screws.

Methodology

This study was done to evaluate and compare the outcomes of medial malleolar fractures operated with open reduction internal fixation with tension band wiring and 4mm cannulated cancellous screws in our hospital setup.

This is a prospective study of medial malleolar fractures in 30 patients treated at Krishna hospital and Medical research center, Karad. It includes the patients presenting themselves in casualty and OPD of department of orthopaedics and newly diagnosed as medial malleolar fractures. Follow up period was till 6 months.

When the patients were seen for the first time after injury, a through history was taken regarding the time of injury, mechanism of injury, any significant past or personal history. Patients were examined giving special importance to whether the fracture was open or closed, presence of gross swelling, fracture blisters and presence of other associated injuries.

Routine investigations were done as were necessary. The diagnosis was confirmed by antero-posterior, lateral and mortise radiographs. Stabilization was done with a below knee slab, and open reduction and fixation was done once the skin condition was good and swelling had subsided.

Inclusion criteria

1. Patients of any sex.
2. Age group: 18 years above.
3. Patients who are fit for surgery.
4. Patient willing to participate in the study.
5. Transverse/Oblique vertical fracture.

Exclusion criteria

1. Unwillingness to participate in the study.
2. Patients unfit for surgery and/or anaesthesia.
3. Patients with history of previous medial malleolus fracture of either ankle.
4. Patients with vertical shear (adduction) fracture of medial malleolus.
5. Immature skeleton- Age below 18 years.

The form of treatment (tension band wiring or 4mm cannulated cancellous screws) was decided randomly. Fractures type B, type C and type D according to Muller Classification for isolated fracture of medial malleolus were included in this study.

Muller classification for isolated fracture of medial malleolus

Type A: Fracture avulsions of the tip of the malleolus.

Type B: Fracture occurring between the tip and the level of the plafond

Type C: Fracture at the level of the plafond

Type D: Fracture extending vertically above this

Out of 30 fractures, 15 were operated with open reduction and internal fixation with tension band wiring and 15 were operated with open reduction and internal fixation with 4mm cannulated cancellous screws.

The basic idea was to achieve near anatomical reduction. Open reduction and internal fixation was used in all 30 patients. It was done as a planned and elective procedure. Before patients were taken up for surgery, they were put on foot elevation and anti-inflammatory drugs for few days to reduce foot swelling. For all 30 cases anteromedial approach was used.

Post operatively limbs were immobilized in plaster splint, patients were put on antibiotics and analgesics and limbs were elevated. Dressings were done regularly and sutures were removed on average on 14th day (decided according to the wound inspection). The below knee splint was continued till 6 weeks post operatively in both groups and was then removed. Patients were assessed for fracture union radiologically. Once the fracture showed signs of union, partial weight bearing was advised, which was approximately at 6-8 weeks and it was then gradually increased to full weight bearing. Physiotherapy exercises for ankle movements were started on removal of slab.

Follow up

Weight bearing is restricted for 6 weeks. At 6 weeks the plaster was removed. Clinical examination was done regarding movement of ankle. At 6 weeks x-ray of the ankle was taken in AP, lateral and mortise views and looked for

signs of fracture union and then were advised partial weight bearing once the fracture showed signs of union. Patients were advised to keep the limb at elevation at night times and perform active movements of ankle joints. It was then gradually increased to full weight bearing. Regular follow up was done at 6 weeks, 3 months and thereafter at monthly intervals till 6 months after operation till the fracture united (Figure 1, 3). Follow up X-rays were taken to assess fracture

union, the condition of implant (Figure 2,4). Union was considered when fracture line could not be seen on radiographs and normal bony trabeculae were seen crossing across the fracture site. When patient could walk full weight bearing and did not have any tenderness.

Functional or Clinical and Radiological outcome of Ankle joint after CC-screw Fixation

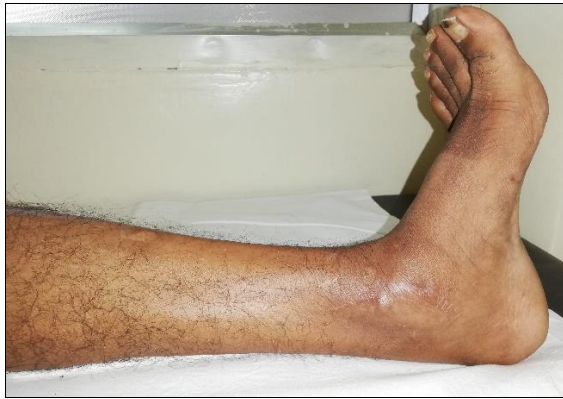

Fig 1: (a) Dorsiflexion at end of 6 months

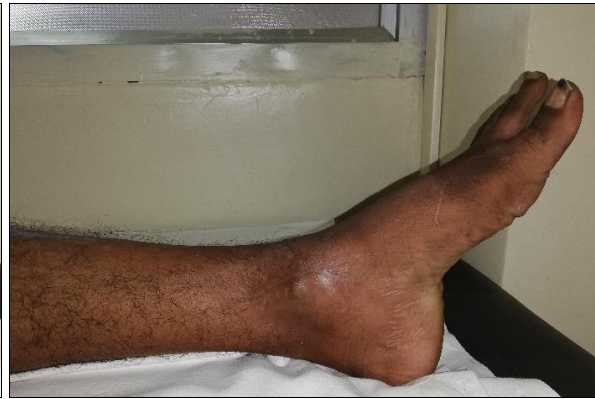

Fig 1: (b) Plantar flexion at end of 6 months

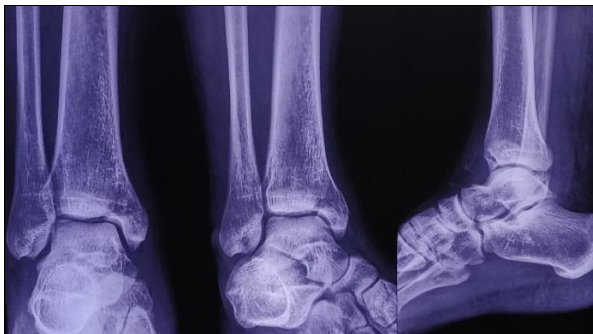


Fig 2: (a) Pre-Operative X-ray

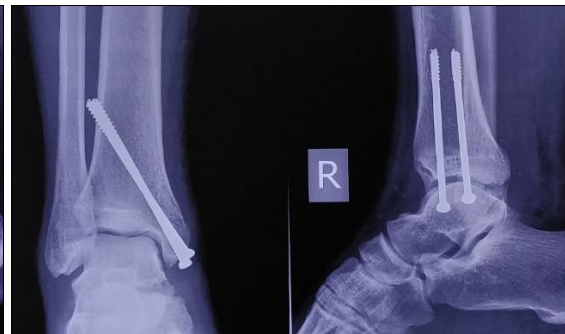

Fig 2: (b) Post-operative X-ray

Functional or clinical and radiological outcome of ankle joint after tension band wiring fixation

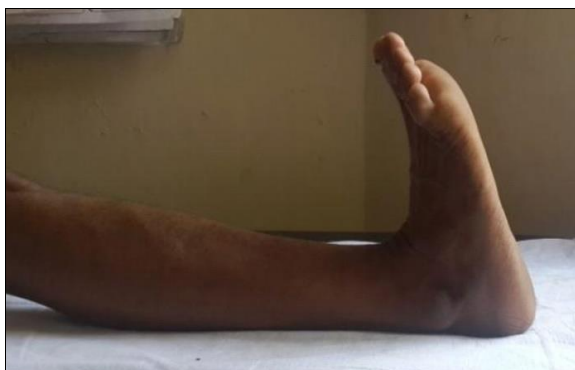

Fig 3: (a) Dorsiflexion at end of 6 months

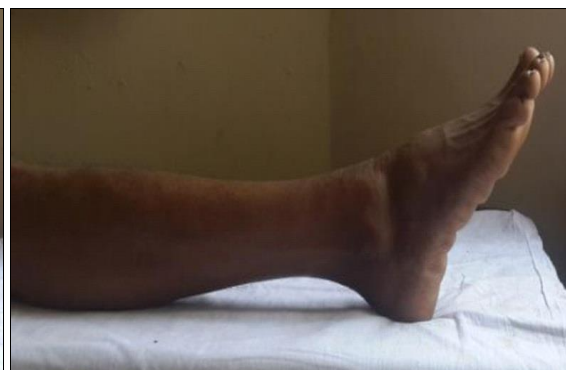

Fig 3: (b) Plantar flexion at end of 6 months

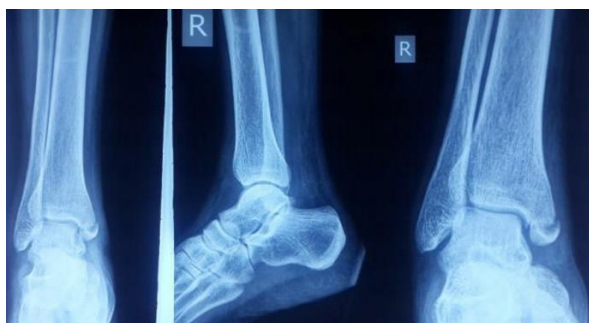

Fig 4: (a) Pre-Operative X-ray

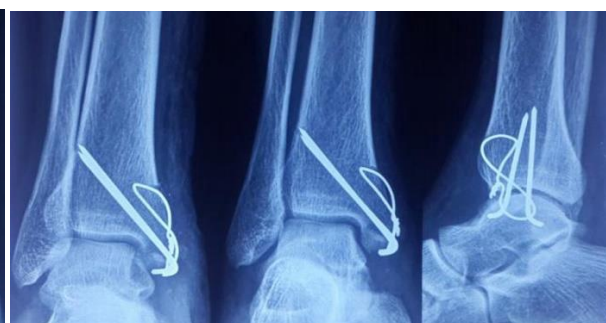

Fig 4: (b) Post-operative X-ray

Assessment of results

Baird and Jackson scoring system was used to evaluate the patients at the end of 6 months. Score and fracture union in both the groups were compared using unpaired t test. Finally correlation between results of the score and clinical data were evaluated using chi square test.

Baird and Jackson scoring system

1) Pain Score

a.	No Pain	15
b.	Mild pain with strenuous activity	12
c.	Mild pain with activities of daily living	8
d.	Pain with weight bearing	4
e.	Pain at rest	0

2) Stability of ankle

a.	No clinical instability	15
b.	Instability with sports activities	5
c.	Instability with activities of daily living ability to walk	0

3) Able to walk

a.	Able to walk desired distances without limp or pain	15
b.	Able to walk desired distances with mild limp or pain	12
c.	Moderately restricted in ability to walk	8
d.	Able to walk short distances only	4
e.	Unable to walk	0

a.	Anatomical with intact mortise (normal medial clear space, Normal 2mm superior joint space, no talar tilt)	25
b.	Same as above with mild reactive changes at the joint margins	15
c.	Measurable narrowing of the superior joint space, superior joint space 2mm, or talar tilt >2mm	10
d.	Moderate narrowing of the superior joint space, with superior space between 2 and 1mm.	5
e.	Severe narrowing of the superior joint space, with superior joint space <1mm widening of the medial clear space, severe reactive changes (Sclerotic subchondral bone and osteophyte formation)	0

A scores according to the Baird and Jackson Scoring system

Excellent	96 - 100
Good	91 - 95
Fair	81 - 90
Poor	0 - 80
Maximum possible score	100

Method of statistical analysis

The Excel and Graphpad Instat (Graphpad softwares inc, USA) software packages were used for data entry and analysis.

Observation and results

A total of 30 cases were enrolled in the study, 15 cases were operated with open reduction and internal fixation with 4mm cannulated cancellous screws and 15 cases were operated with open reduction and internal fixation with tension band wiring. The mean age in CCS group was 43.06 years whereas in TBW group was 47.06 years. According to unpaired t test, the difference was statistically insignificant.

Majority of the patients (43.33%) included in the study were in the age group 40-59 years. When Chi square test was applied for the distribution of patients in three age groups for both the operative procedures modalities it was found to be statistically non-significant.

Out of total 30 patients considered in study 20 (66.66%) were male and 10 (33.33%) were female. Almost similar ratio was seen in either of the groups.

4) Able to run

a.	Able to run desired distances without pain	10
b.	Able to run desired distances with slight pain	8
c.	Moderate restriction in ability to run with mild pain	6
d.	Able to run short distances only	3
e.	Unable to run	0

5) Ability to work

a.	Able to perform usual occupation without restrictions	10
b.	Able to perform usual occupation with restrictions in some strenuous activities	8
c.	Able to perform usual occupation with substantial restriction	6
d.	Partially disabled; selected jobs only	3
e.	Unable to work	0

6) Motion of the ankle

a.	Within 10 of uninjured ankle	10
b.	Within 15 of uninjured ankle	7
c.	Within 20 of uninjured ankle	4
d.	<50 of uninjured ankle, or dorsiflexion <5	0

7) Radiographic result

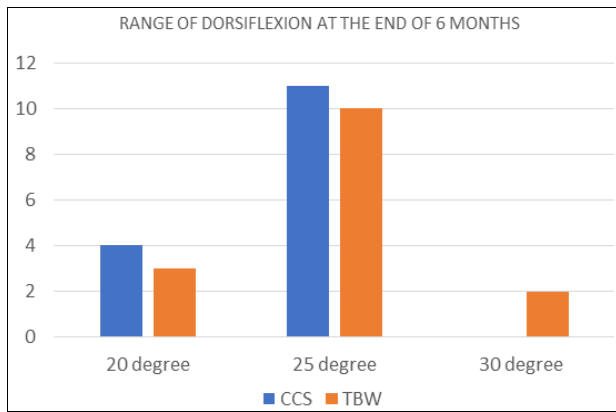
Out of total 30 patients treated 11 (36.66%) had medial malleolus fracture on right side and 19 (63.33%) had medial malleolus fracture on left side. The comparison of side affected in individual group was statistically non-significant.

In CC-Screw group, 4 (26.66%) patients had Type B fracture, 4 (26.66%) patients had Type C fracture and 7 (46.66%) patients had Type D fracture. In TBW group, one (6.66%) patient had Type B fracture, 4 (26.66%) patients had Type C fracture and 10 (56.66%) patients had Type D fracture.

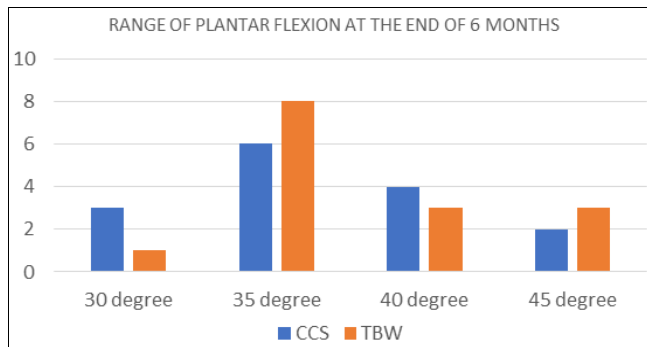
At the end of 6 weeks, the mean range of dorsiflexion in CCS groups was 12 as compare to 13.66 in TBW group, was not statistically significant and the mean range of plantarflexion in CCS group was 16.66 degrees as compared to 18.33 degrees in TBW group, which was not statistically significant.

At the end of 3 months, the mean range of dorsiflexion in CCS group was 17 degrees as compared to 19 degrees in TBW group, which was not statistically significant and the mean range of plantarflexion in CCS group was 23 degrees as compared to 24 degrees range of plantarflexion in TBW group. The improvement in the range was statistically significant (p value- 0.0274) in TBW group.

At the end of 6 months, the mean range of dorsiflexion in CCS group was 23.66 degrees as compared to 24.66 degrees in TBW group and showed no statistically significant difference (Graph 1). The mean range of plantarflexion in CCS group was 36.66 degrees as compared to 37.66 degrees range of plantarflexion in TBW group (Graph 2). The improvement in the range was statistically significant in TBW group with a p value of 0.0439.



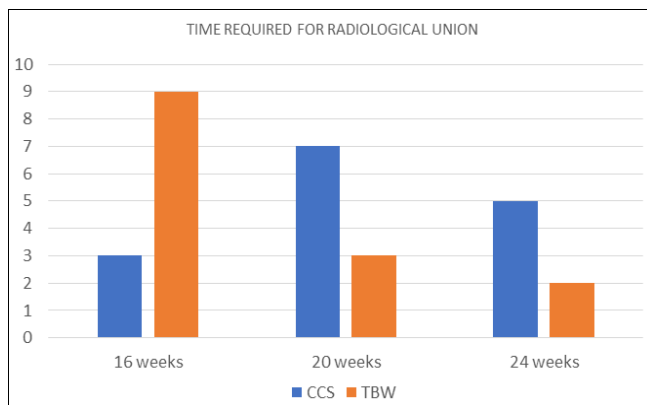
Graph 1: Range of dorsiflexion at the end of 6 months



Graph 2: Range of plantar flexion at the end of 6 months

Out of total 30 patients treated in this study, 3 cases in CCS group and 2 cases in TBW group developed postoperative infection which was similar in both groups and was statistically insignificant.

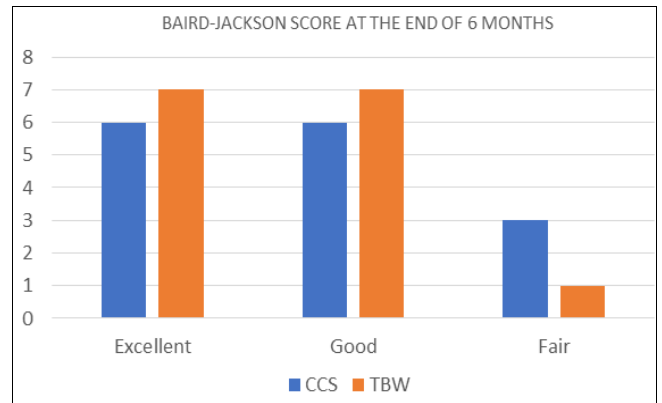
At the end of 6 months, Average time required for radiological union in CCS group was 20.53 weeks and in TBW group was 18.66 weeks (Graph 3). Union occurred earlier in TBW group. When unpaired t test was applied to these values, it was found to be statistically significant with a p value of 0.0303.



Graph 3: Time taken for radiological union

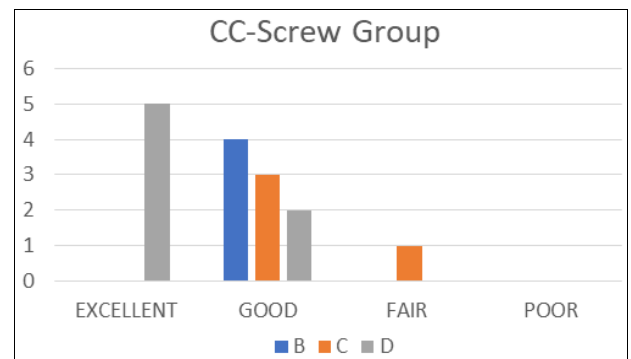
The mean Baird and Jackson score at the end of 6 months for CCS group was 94.06 and for TBW group was 95.13. The mean score in TBW group was found to be better as compared to CCS group. On applying unpaired t test, statistically significant difference was found (p value- 0.018). Out of the 30 patients treated 36.66% had excellent results, 50% had good results and 13.33% had fair results (Graph 4). On comparing the results in both groups by applying chi square test statistically significant difference was found with p

value of 0.0490, thus results of TBW groups had better results than CCS groups.



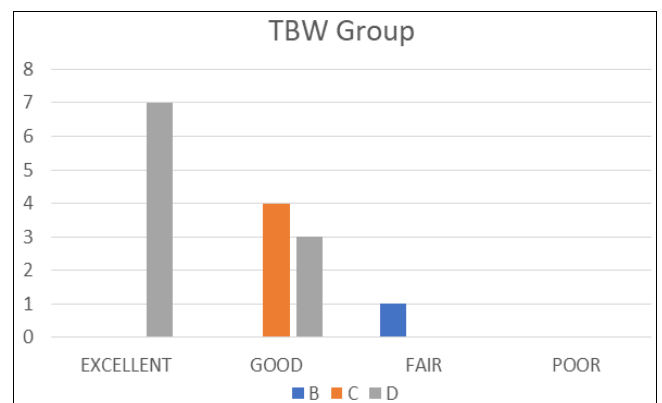
Graph 4: Baird-Jackson score at the end of 6 months.

Out of the 15 patients in CC-Screw group Type B fracture Treated had 26.66% good results, Type C fracture had 20% good results and 6.66% had fair results and Type D fracture had 33.33% Excellent results and 13.33% good results with the mean Baird and Jackson score at the end of 6 months for Type B- 92.25, for Type C- 91 and for Type D- 96.85 (Graph 5).



Graph 5: Results on the Basis of fracture Type

Out of the 15 patients in TBW group Type B fracture Treated had 6.66% Fair results, Type C fracture had 26.66% good results and Type D fracture had 46.66% Excellent results and 20.66% good results with the mean Baird and Jackson score at the end of 6 months for Type B- 90, for Type C-92.50 and for Type D- 96.70 (Graph 6).



Graph 6: Results on the Basis of fracture Type

Discussion

Malleolar injuries are the most common significant lower

extremity fracture. They primarily involve medial malleolus. They are produced indirectly by shearing and tensile forces applied through the talus [8, 9]. The treatment of medial malleolar fractures with accurate open reduction and stable internal fixation using AO method and principles was found to give a high percentage of excellent and good results. In this study the outcomes of medial malleolar fractures treated with open reduction and internal fixation with tension band wiring and 4 mm cannulated cancellous screws were evaluated and compared. The results of present study are compared to with those of previous similar studies.

The mean age of this study was 45.06 years. This finding was similar to observation of Roberts RS [10] whose study the mean age was 40 years, Beris *et al.* [11] in whose study the mean age was 43.8 years.

There was male predominance in this series which is also observed in other studies. In this study out of 30 patients, 20(66.66%) were male and 10(33.33%) were females. Nabeel Shams *et al.* [12] in his study of 30 patients had 22 male and 8 female patients. Dr. Maruthi CV [13] *et al* in their study of 40 cases had 28 males and 12 females.

In this study we observed that 33.33% are excellent and 46.66% are good results in CCS group (treated with 4mm cannulated cancellous screws) and 40% are excellent and 53.33% are good results in TBW group (treated with tension-band wiring) according to Baird and Jackson scoring system, the difference was statistically significant ($p=0.0490$). This agrees with the results of Sang-Hanko and Young- Junpark [14] who achieved excellent and good results in about 78% of cases treated with screws and 89% of cases treated with tension-band wiring. Al-Lamy *et al.* [15] also achieved excellent and good results in 80% in group treated with screws and 90% in group treated with tension-band wiring, according to the modified ankle scoring system of Olerud and Molander [16].

Table 1: Results in various studies

Study	CCS (Excellent to Good)	TBW (Excellent to Good)
Sang-Hanko and Young-Junpark [14]	78%	89%
Al-Lamy <i>et al.</i> [15]	80%	90%
Present Study	80%	93.33%

In this study the mean time for radiological bone union in CCS group was 20.53 weeks and in TBW group was 18.66 weeks with a statistical significant difference ($p=0.0303$). So union occurred earlier in tension band wiring group in this study. This is similar to SK. Nurul *et al.* [17] study that reported a mean time of 11.8 weeks for screws and 9.4 weeks for tension-band wiring; and Al-Obaidy and Al-Lamy [15] who in their study had union time of 12 weeks in screw group and 9 weeks in tension band wiring group, both of whom reported earlier fracture union in tension band wiring group.

Table 2: Radiological union in various studies

Study	CCS (Weeks)	TBW(Weeks)
SK.Nurul <i>et al.</i> [17]	11.8	9.4
Al-Obaidy and Al-Lamy [15]	12	9
Present Study	20.53	18.66

Ostrum and Litski [18] recently demonstrated the biomechanics advantages of the tension-band over other fixation techniques for medial malleolus. When resisting pronation forces and applying compression force tension-band were four times

stronger than screws. This might explain the faster union rate we were achieved in TBW group (mean of 18.66 weeks) as compared with CCS group (mean of 20.53 weeks).

We did not have any cases of non-union which were similar to the study results of S K. Nurul [17] who achieved 100% union rate in both groups. Al Lamy *et al.* [15] had experienced two cases of delayed union (5%) out of 40 cases of the study but did not report any cases of non-union.

In this study we reported loss of reduction with the use of tension band technique as a result of K-wires become loosened and migrate proximally [19]. Some reported back out of cannulated cancellous screws leading to implant loosening. On the other hand many authors did not agree with the frequency of this complication and reported that with the proper surgical techniques, wire migration was not a problem [20, 21]. In this study we did not see any wire migration, pull out of screw or loss of reduction and implant failure. Al Lamy and Al-Obaidy [15] in their study of 40 cases did not report any case of fixation failure or kirschner wires migration or loss of reduction.

Better range of motion was noticed in TBW group as compared with CCS group, with significant statistical difference ($p=0.0439$). This could be attributed to more rigid fixation with the use of tension-band. The use of tension band wire for fixation on the tension surface of a fractured bone converts the distracting tensile force in to a compressive force [22].

In this study out of 30 cases, the only postoperative complication we encountered was superficial infection. We came across this complication in 3 cases which was managed by regular dressings and administration of antibiotics. Nabeel Shams *et al.* [12] in his study of 30 patients, reported superficial infection in 2 patients. Pradeep Choudhari & Ranjeet Agrawal [23] in their study on 68 cases, superficial infection was found in only one patient.

Conclusion

In this study we observed that the functional outcome of Ankle joint after medial malleolus fracture treated with open reduction and internal fixation with tension band wiring gives better results in range of motion and union as compared to open reduction and internal fixation with 4.0 mm cannulated cancellous screws.

Thus, we conclude that open reduction and internal fixation with tension band wiring give better functional and radiological outcomes as compared to cannulated cancellous screws.

References

- Roy I, Davidovitch E, Egol AK. Ankle Fractures. In: Bucholz WR, Charles, Heckman JD, Paultornetta, Editors. Rockwood and Greens Fractures in Adults. Edition 7. Philadelphia: Lippincott Williams and Wilkins Publishers, 2009, 1975-2017.
- Simon WH, Friedenbunrg S, Richardson S. Joint Congruence; A correlation of joint congruence and thickness of articular cartilage in cogs. J Bone Joint Surg. 1973; 55:1614.
- Shelton Marvin L. Complication of fractures and dislocation of the ankle. In: Complications in orthopaedic surgery, Chapter 23, 3rd edn., ed. EPPS, Charles H, Philadelphia: J.B. Lippincott Company, 1994; 1:595-648p.
- Ashurst APC, Bromer RS. Classification and mechanism of fracture of leg bones involving the ankle: based on a

- study of 300 cases from the Episcopal Hospital. Arch Surg, 1992; 4:51-129.
5. Muller ME, Allgower M, Scheinder R, Willenegger H. Manual of internal fixation: Techniques recommended by AO group, 3rd edition. New York: Springer Verlag. 1995; 147:148-49.
 6. Weber MJ. Ankle fractures and dislocations. In: Operative orthopaedics, Chapter 50, 2nd edn., Ed. Chapman MW, Madison M. Philadelphia: J.B. Lippincott Company. 1993; 3:731-748.
 7. Ramsey L, Hamilton W. Changes in tibiotalar area of contact caused by lateral talar shift. J Bone Joint Surg. 1987; 58A:356-57.
 8. Daly PJ, Fitzgerald RH Jr, Melton LJ, Ilstrup DM. Epidemiology of ankle fractures in Rochester, Minnesota. Acta Orthop Scand. 1987; 58:539-44.
 9. Lauge-Hansen N. Fractures of the ankle. II. Combined experimental-surgical and experimental roentgenologic investigations. Arch Surg. 1950; 60:957-85.
 10. Roberts RS. Surgical treatment of displaced ankle fractures. Clin Ortop. 1983; 172:164-170.
 11. Beris AE, Kabbani KT, Xenakis TA, Mitsionis G, Soucacos PK, Soucacos PN. Surgical treatment of malleolar fractures – a review of 144 patients. Clin Orthop Related Research. 1997; 341:90-98.
 12. Nabeel Shams, Imthiaz Ahmed, Athmananda Hegde. A study on surgical treatment of ankle fractures- A clinical study of 21 cases. IJBAR. 2014; 05(04):190-192.
 13. Dr. Maruthi CV, Dr. Venugopal N, Dr. Nanjundappa HC, Dr. Siddalinga Swamy MK. Bimalleolar Fracture of Ankle Joint Managed By Tension Band Wiring Technique: A Prospective Study. Sch. J App. Med. Sci. 2014; 2(1D):428-432.
 14. Sang-Hanko M, Young-Jun Park D. Comparison between screw fixation and tension-band wiring for medial malleolus fractures. Korean Society of Foot Surg. 2002; 6(1):41-44.
 15. Al-Lamy WA, Al-Obaidy MH. Comparative Study of Internal Fixation for Displaced Closed Fracture of Medial Malleolus Using Malleolar Screw versus Tension-band Wiring. Karbala J. Med. 2008; 2(4-5):308-318.
 16. Olerud C, Molander H. A scoring scale for symptom evaluation after ankle fracture. Arch Orthop Trauma Surg. 1984; 103:190-4.
 17. Nurul SK, Parviz Shahidi *et al.* Comparative study of malleolar fractures by tension-band and malleolar screw. BOS Journal. 1998; 12(1):13-19.
 18. Ostrum RF, Listsky AS. Tension-band fixation of medial malleolar fracture. J Orthop Trauma. 1997; 6:464.
 19. Mack D, Szabo RM. Complications of tension band wiring. J Bone Joint Surg. 1999; 67:1936-1941.
 20. Kinik H, Mergen E. Self-locking tension-band technique. Arch Orthop Trauma Surg. 2002; 119:432-434.
 21. Joy G, Patzakis MJ, Harvey JP. Specify evaluation of the reduction of ankle fractures. J Bone Joint Surg. 1998; 56A:979-985.
 22. AO. Manual of Principles of fracture fixation. Chapter-3.2.3, 1:249-254.
 23. Pradeep Choudhari, Ranjeet Agrawal. Comparative Study of one versus two screws in treatment of isolated fracture of medial malleolus. International Journal of Current Medical and Applied Sciences. 2015; 7(3):151-154.