



ISSN: 2395-1958
IJOS 2019; 5(2): 35-38
© 2019 IJOS
www.orthopaper.com
Received: 17-02-2019
Accepted: 18-03-2019

Lavakumar S Loya
Associate Professor,
Mahadevappa Rampure Medical
College, Kalaburgi, Karnataka,
India

M Quadri
Mahadevappa Rampure Medical
College, Kalaburgi, Karnataka,
India

Retrograde intramedullary interlocking nailing for supracondylar fractures of femur: A prospective study

Lavakumar S Loya and M Quadri

DOI: <https://doi.org/10.22271/ortho.2019.v5.i2a.09>

Abstract

Objectives: We assessed whether a Retrograde intramedullary interlocking nail has a good outcome in cases of supracondylar Femur fractures, with respect to the degree of knee flexion, early weight bearing and return to the pre-fracture state.

Methods: We conducted a prospective study of 32 patients which presented with supracondylar femur fracture, and had undergone a closed reduction and internal fixation by Retrograde Femoral nail. Neer's and Sander's evaluation scoring system was used for evaluation.

Results: Neer's rating was used to evaluate the outcome, according to which there was good to excellent results in 68.74% cases.

Conclusion: Supracondylar femur nail is an optimum tool for many supracondylar fractures of femur, but it requires attention to technique in order to prevent the complications.

Keywords: RIMN, DFN, SCFN, Retrograde intra medullary nail, Distal femoral nail

Introduction

Supracondylar femur fractures show a bimodal age distribution, occurring more commonly in young and old population groups. In the early 1960s, there was a great reluctance towards operative management because of high incidence of infection, non-union, malunion, inadequate fixation, and lack of proper instruments, implants, as well as antibiotics. Then, the traditional management of displaced supracondylar fracture of Femur was along the principle of Watson Jones and John Charnley, which comprised of skeletal traction, manipulation of fracture and external immobilization in the form of casts and cast bracings. These methods had complications like deformity, shortening, prolonged bed rest, knee stiffness, angulation, joint incongruity, malunion, quadriceps wasting, knee instability and post-traumatic osteoarthritis.

The current trends of management include the use of AO blade plate, dynamic condylar screw and other implant systems like intramedullary supracondylar nails. Supracondylar fractures tend to collapse into varus. During the application of AO blade plate or dynamic condylar screw, the shaft of Femur is often pulled laterally displacing the line of weight bearing lateral to the anatomic axis of condyle. This creates rotational movements at the fracture site that causes pulling off the blade plate or condylar screws leading to fatigue fracture of the plates. Also, the presence of osteoporotic bone leads to fixation failures with screws and plates cutting off the soft bone.

The obvious advantage of nail is that it aligns the femoral shaft with condyles reducing the tendency to place varus movement at the fracture site. And because bending movement of an intramedullary device is substantially reduced failure of fixation in osteoporotic bone should be less. In addition, a retrograde intramedullary supracondylar nail has got distinct advantages of preservation of fracture hematoma, decreased blood loss, minimal soft tissue dissection, less operative time and reduced rate of infection. The purpose of this study is to evaluate the results of supracondylar and intercondylar fracture of femur, treated by close/open reduction and internal fixation using retrograde intramedullary supracondylar nail.

Materials and Methods

In this study, 32 patients with supracondylar fracture of Femur without intercondylar extension were studied. All the cases were treated in Basaveshwara Teaching and General Hospital, Kalaburgi, between the period of February 2017 to August 2018.

Correspondence

Lavakumar S Loya
Associate Professor,
Mahadevappa Rampure Medical
College, Kalaburgi, Karnataka,
India

The duration of follow-up ranged from 6 months to 18 months.

All the fractures in the series were post-traumatic, and no pathological fractures were included. Also pediatric group were not included. The study was restricted to fractures occurring at the region 9 cms proximal to lower end of Femur. After admission of patient, the fracture was stabilized with the use of well-padded Thomas splint. Once patient were stable, with no medical contraindication for surgery, they were operated under spinal anesthesia.

The implant used was Supracondylar Femur Nail system with instrumentation set. The nails come with a diameter of 10, 11, 12 mm, with the distal end expanded to a diameter of 13 mm. The nails are available in different lengths. All sized nails have five interlocking holes, two proximal and 3 distal, which accept bolts of size 4.9 mm. Fractures were classified with the help of radiographs according to the AO-ASIF classification. Pre-operative evaluation was done on radiographs to ascertain the length of supracondylar nail, maximum possible diameter and the lengths of interlocking bolts. A transpatellar approach was used, with mid-line incision from the inferior pole of patella to tibial tuberosity. The entry point for the nail is in the axis of the medullary canal and in the intercondylar notch, just anterior and lateral to the femoral attachment of the posterior cruciate ligament, determined on image intensifier. All the nails were locked on both the ends by bolts. Post-operatively, static quadriceps and active or assisted bedside knee mobilisation was started from the 2nd post-operative day. Partial weight bearing was allowed after 6 weeks, followed by complete weight bearing from 10th week with the help of a walker.

Results

In this study, 32 patients were included with a follow-up ranging from 6 months to 18 months. Out of the 32 patients, majority of the patients were male (22). The ages ranged from 24 to 52, with a mean age of 34.2 years. Majority sustained fractures due to high velocity vehicular accidents, followed by fall from height. Type A1 constituted 11 patients, Type A2

presentation constituted the majority (17) and type A3 were relatively rare (40). All the fractures in this series were closed fractures. Maximum patients had undergone internal fixation within 5 days after sustaining the injury. The average operative time was 68.20 mins, with the highest time taken by type A3. Average radiological union time was 16 weeks. Full weight bearing was achieved on an average in 11.68 weeks. Average flexion achieved post-operatively was 105°. There was an extensor lag of an average of 5.68°.

Table 1: Major complications seen were delayed union and deep infection. Most common complication included local symptoms at the distal bolt.

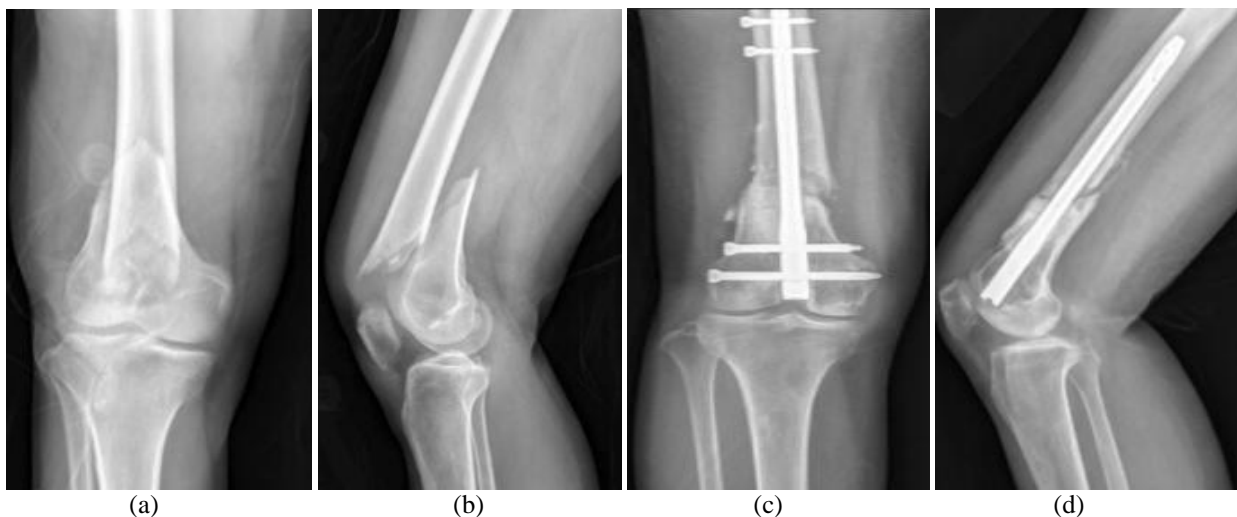
Complications	Number of cases	Percentage
Local symptoms at distal screw	5	15%
Impingement	1	3%
Superficial infection	2	6%
Delayed union	1	3%
Distal migration of nail	1	3%
Deep infection	1	3%
Distal screw breakage	2	6%
Stress fracture	0	0
Implant failure	0	0

Table 2: Neer’s rating system was used to evaluate the outcome, which allots points for pain, function, working ability, joints movement, gross and radiological appearance.

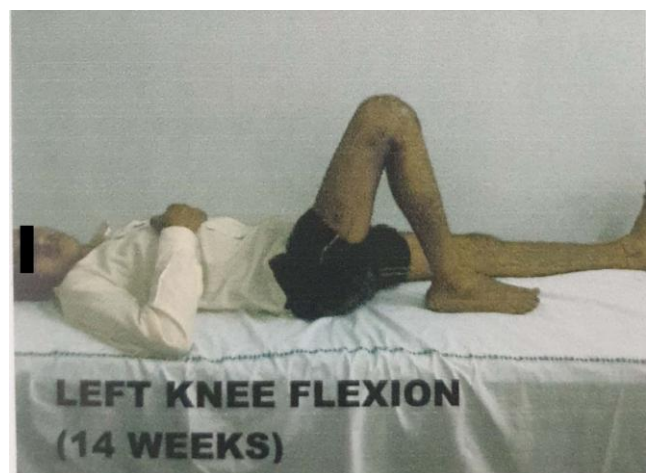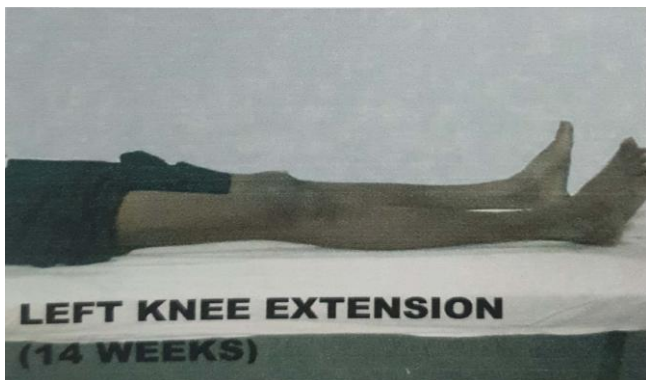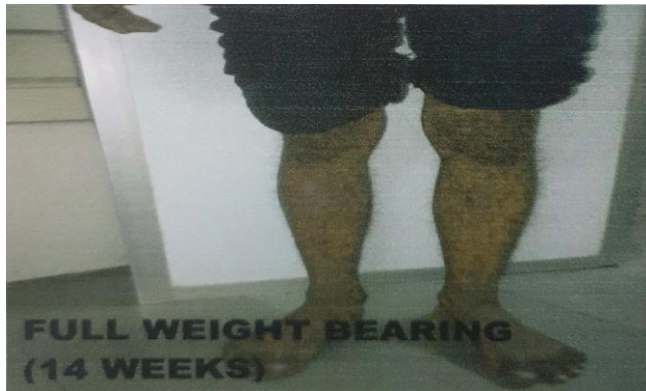
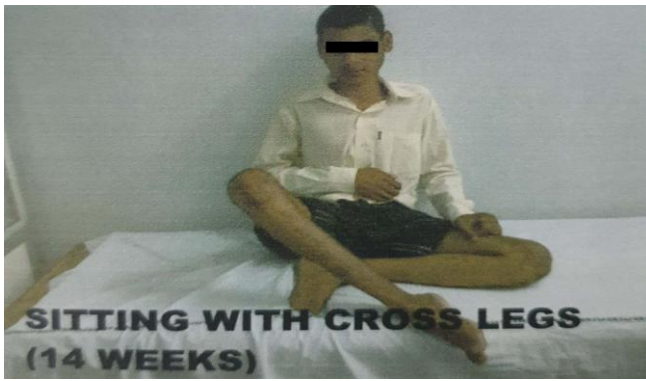Rating	Number of cases	Percentage
Excellent >85 points	17	53.12%
Good 70-85 points	5	15.62%
Fair 50-69 points	8	25%
Poor <50 points	2	06.25%

Table 3: In 68.74% cases, there was good to excellent results

Type of fracture	Average wt bearing in weeks
Type A1	11.03 weeks
Type A2	12 weeks
Type A3	13 weeks



(a, b): Pre-operative radiographs in AP and lateral views, (c, d): immediate post-operative radiographs.



Discussion

Distal femur fractures occur following high-energy impact in young patients often resulting in comminuted and open fractures, whereas low-energy injury is sufficient to cause distal femoral fractures in elderly patients with osteopenic or osteoporotic bone. Protection of soft-tissue envelope due to the minimally invasive approach and closed reduction techniques is better realized using IM nailing. Aim of this study was to evaluate clinical and radiological outcomes of

distal femur fracture stabilization using retrograde supracondylar femur nail.

Our series did not concur with that of Akib *et al*, which had a mean age of 63 years, against the mean age of 34.2 years [1]. Road traffic accidents accounted for the majority in young population, and male patients, while fall from height was the second most common mode in our series. This series varied from the results seen in a study conducted by Elsoe *et al*, which had a 61% incidence as a result of trivial trauma, which can be attributed to increased Road traffic accidents in recent years [2].

Among the various treatment modalities, many studies have been conducted on outcomes of distal femur LCP and supracondylar femoral nail. The obvious advantage of nailing is that it aligns the femoral shaft with condyles reducing the tendency of varus movement at the fracture site. Also, since the bending moment is substantially reduced in nail, so failure of fixation in osteoporotic bone is less. Stabilization of distal femur fractures with periarticular locking plates can cause inconsistent and asymmetric formation of periosteal callus [3]. Significantly less periosteal callus formed in fractures stabilized with locking plates than with IM nails [4]. But most studies conclude that plating and RIMN have similar results in the treatment of extra-articular distal femur fractures [5, 6]. Clinical outcome largely depends on surgical technique rather than on the choice of implant [7].

Another study emphasised that cement augmentation and shape memory alloy can also be used for added mechanical stability. This surgical technique is very useful for distal femur fracture with osteoporosis as it promotes fracture healing and early rehabilitation [8].

A meta-analysis concluded that RIMN and plate fixation are similar in terms of infection, non-union, delayed union, malunion, and metalwork failure [9]. Major complications encountered by us were delayed union and deep infection. Most common complication was local symptoms at the distal bolt. One study concluded that early and unrestricted mobilisation is possible with a very low risk of fracture healing complications even in elderly population group [10]. Another study also concluded that though two methods appear to have the same percentage of excellent results and same time to bony union, nailing is preferable to plating in terms of less blood loss and shorter operating time [11].

Thus, our conclusion is same as that of Handolin *et al*, i.e. distal femoral nail is a reliable alternative in distal femoral fracture treatment with a low complication rate [12].

Conclusion

Retrograde intramedullary supracondylar nail is a good fixation system for the distal third femoral fractures, particularly the extra-articular type. The operative time is lessened with decrease in blood loss. Distal screw related local symptoms is a common problem, and is related to the implant and technique. Early surgery, closed reduction, at least two screws in each fragment, and early post-operative knee mobilisation are essential for good union, and good knee range of motion.

There is not much difference in individual fracture type healing and weight bearing. Thus, it provides rigid fixation in the region of femur, where a widening canal, thin cortices and frequently poor bone graft makes the fixation difficult. Surgical exposure for nail placement requires significantly less periosteal stripping and soft tissue exposure than that of lateral fixation devices.

Reference

1. Akib Majed Khan, Quen Oat Tang, Dominic Spicer. The Epidemiology of Adult Distal Femoral Shaft Fractures in a Central London Major Trauma Centre Over Five Years. *Open Orthop J.* 2017; 11:1277-1291.
2. Elsoe R, Ceccotti AA, Larsen P. Population-based epidemiology and incidence of distal femur fractures. *Int Orthop.* 2018; 42(1):191-196.
3. Lujan TJ, Henderson CE, Madey SM, Fitzpatrick DC, Marsh JL, Bottlang M. Locked plating of distal femur fractures leads to inconsistent and asymmetric callus formation. *J Orthop Trauma.* 2010; 24(3):156-62.
4. Henderson CE, Lujan T, Bottlang M, Fitzpatrick DC, Madey SM, Marsh JL. Stabilization of distal femur fractures with intramedullary nails and locking plates: differences in callus formation. *Iowa Orthop J.* 2010; 30:61-8.
5. Demirtaş A, Azboy I, Özkul E, Gem M, Alemdar C. Comparison of retrograde intramedullary nailing and bridge plating in the treatment of extra-articular fractures of the distal femur. *J Clin Exp Med.* 2016; 9(10).
6. David SM, Harrow ME, Peindl RD, Frick SL, Kellam JF. Comparative biomechanical analysis of supracondylar femur fracture fixation: locked intramedullary nail versus 95-degree angled plate. *J Orthop Trauma.* 1997; 11(5):344-50.
7. Hierholzer Christian, Rüdén Christian von, Pötzel Tobias, Woltmann Alexander, Bühren Volker. Outcome analysis of retrograde nailing and less invasive stabilization system in distal femoral fractures: A retrospective analysis. *Indian J Orthop.* 2011; 45(3):243-50.
8. Jihyeung Kim, Seung-Baik Kang, Kyungpyo Nam, Seung Hwan Rhee, Jong Won Won, Hyuk-Soo Han. Retrograde Intramedullary Nailing for Distal Femur Fracture with Osteoporosis. *Clin Orthop Surg.* 2012; 4(4):307-312.
9. Aijun Wang, Shuangle Zong, Lixin Su, Weidong Liang, Xiaoqiang Cao, Qiutao Zheng *et al.* Meta-analysis of postoperative complications in distal femoral fractures: retrograde intramedullary nailing versus plating *Int J Clin Exp Med* 2016; 9(10):18900-18911.
10. Singh SK, El-Gendy KA, Chikkamuniyappa C, Houshian S. The retrograde nail for distal femoral fractures in the elderly: high failure rate of the condyle screw and nut. *Injury.* 2006; 37:1004-101.
11. Christodoulou A, Terzidis I, Ploumis A, Metsovitis S, Koukoulidis A, Toptsis C. Supracondylar femoral fractures in elderly patients treated with the dynamic condylar screw and the retrograde intramedullary nail: a comparative study of the two methods. *Arch Orthop Trauma Surg.* 2005; 125:73-79.
12. Handolin L, Pajarinen J, Lindahl J, Hirvensalo E. Retrograde intramedullary nailing in distal femoral fractures-results in a series of 46 consecutive operations. *Injury.* 2004; 35(5):517-22.