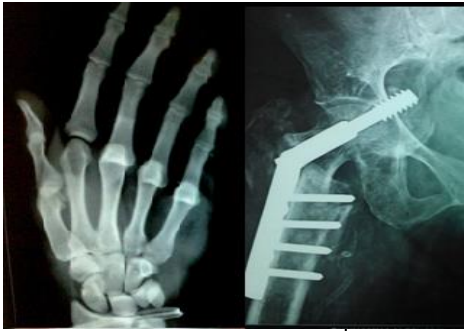

# International Journal of Orthopaedics Sciences

ISSN: 2395-1958  
IJOS 2019; 5(2): 31-34  
© 2019 IJOS  
www.orthopaper.com  
Received: 16-02-2019  
Accepted: 17-03-2019

**Dr. Madhukar KT**  
Professor, Dept. of Orthopaedics,  
Adichunchanagiri Institute of  
Medical College, B G Nagara,  
Karnataka, India

**Dr. Ahmed Zelshan**  
Junior Resident, Dept. of  
Orthopaedics, Adichunchanagiri  
Institute of Medical Sciences, B  
G Nagara, Karnataka, India

## Treatment of dorsal wrist ganglia by transfixation technique using a syringe needle

**Dr. Madhukar KT and Dr. Ahmed Zelshan**

**DOI:** <https://doi.org/10.22271/ortho.2019.v5.i2a.08>

### Abstract

**Background:** Ganglion is one lesion that is frequently seen in minor surgical practice. Treatment of dorsal wrist ganglia begins from basic reassurance to advanced endoscopic excision. Many a time's treatment not often necessary, but patients seek consultation asking for some form of definitive treatment. Recurrence is frequently seen with cyst aspiration/injection or after surgical excision. Recurrence is the common problem, whatever is the treatment modality.

**Materials and Methods:** In this study we evaluate results of 30 dorsal wrist ganglia treated by the transfixation technique using a syringe needle.

**Results:** Out of 30 cases included in this study 28 were completely cured of the symptoms giving a success rate of 93.33%, One patient (3.33%) had recurrence at 4 months and was painful and he had to undergo excision, One patient (3.33%) had recurrence at the end of 6 months.

**Discussion:** Compared to various other modalities this method is cost-effective, time consumption is less, low invasion, recurrence rate is low, and can be performed under local anaesthesia, and does not require any complicated instrument and an easy-to-master technique.

**Keywords:** dorsal wrist ganglia, transfixation technique, syringe needle

### Introduction

Ganglion is a cystic lesion that is usually found on the dorsum of the wrist but can also be seen on the volar aspect of wrist and on various other areas. It is mostly found over dorsum of the hand.

On the dorsal side of the wrist, ganglion appears because of a rent in scapho-lunate capsular ligament. This has pinch cock effect leading to unidirectional flow of the contents, from the joint towards the cyst, until the pressure in the joint and cyst equalize<sup>[1]</sup>.

These are the benign soft tissue tumors occurring around the wrist, consisting of mucin-filled cyst connected to a tendon, tendon sheath, or joint capsule<sup>[2]</sup>. It is one of the most common soft tissue tumors, accounting for about 60-70% of soft tissue tumors<sup>[3]</sup>. They may also present as intraosseous or intra tendinous<sup>[4]</sup>.

Most ganglions are seen in females in their second, third or fourth decades of life<sup>[5]</sup>. The exact cause of ganglions remains uncertain but some patient gives history of previous trauma<sup>[6]</sup>.

The capsule of the ganglion consists of compressed stroma without a cellular lining. This may be linked to the joint by a narrow channel which can act as a one way valve<sup>[7]</sup>. Even though many ganglions are not painful but most of the patient come with complaint of pain as main concern. Spontaneous resolution is commonly seen with 50% of untreated patients when assessed at six years<sup>[8]</sup>.

The management modalities for dorsal wrist ganglia begins from simple assurance to the patient without intervening to simply aspirating the cyst, aspirating and injecting with or without hyaluronidase and/or methylprednisolone, transfixation with a silk suture, breaking the cyst wall manually or by puncturing with a needle percutaneously or by percutaneously incising with a tenotome and excising the cyst radically either by open or endoscopic methods.

All of the above mentioned methods have variable rates of recurrence. Aspiration alone has higher rate of recurrence and with surgical excision, recurrence rate become lesser. All the patient do not require treatment or all the can neither afford the most advanced treatment whatever it may be what patient needs is good success rate.

### Correspondence

**Dr. Madhukar KT**  
Professor, Dept. of Orthopaedics,  
Adichunchanagiri Institute of  
Medical College, B G Nagara,  
Karnataka, India

In this study we present the results of treatment of dorsal wrist ganglia by using the transfixation technique with a suitable syringe needle -a minimally invasive day care procedure with successful results in terms of cure of patient's complaints.

### Materials and Methods

A prospective study was conducted on patients presenting to the orthopaedic out-patient department at our institute hospital for dorsal wrist ganglions from July 2017 to February 2018. Proper clinical history was taken before starting the procedure along with proper examination. Patients were given detailed explanation of the procedure and proper consent was taken.

Our study consisted of 30 subjects with dorsal wrist ganglia of size more than 5 mm and only cases where there was no any previous consultation or treatment who were followed up for a minimum period of 8 months.

There were 26 female (86.66%) patients and 4 (13.33%) male patients. Most common presenting complaint was pain (76.66%) followed by cosmetic (23.33%) irrespective of position of ganglion, sex or dominance. All selected patients

were fresh cases and none were recurrences.

### Exclusion criteria

- 1) Compound palmar ganglion.
- 2) Ganglion located close to radial artery.
- 3) Ganglion of size less than 5mm
- 4) Ganglion which is infected
- 5) Ganglion which is situated at location other than hand
- 6) Ganglion which had any previous consultation or any other treatment
- 7) Ganglion associated with arthritic disorder

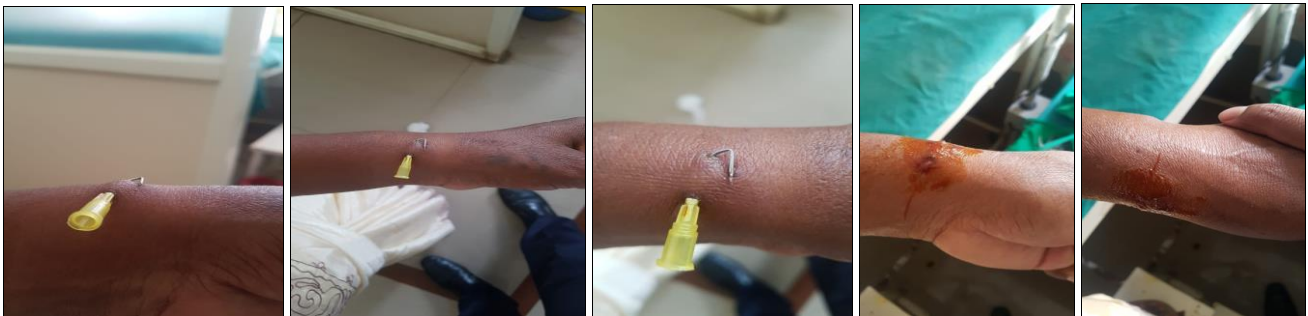### Materials

Xylocaine 2% without adrenaline, Sterile cut down tray, Disposable syringe needle, artery forceps.

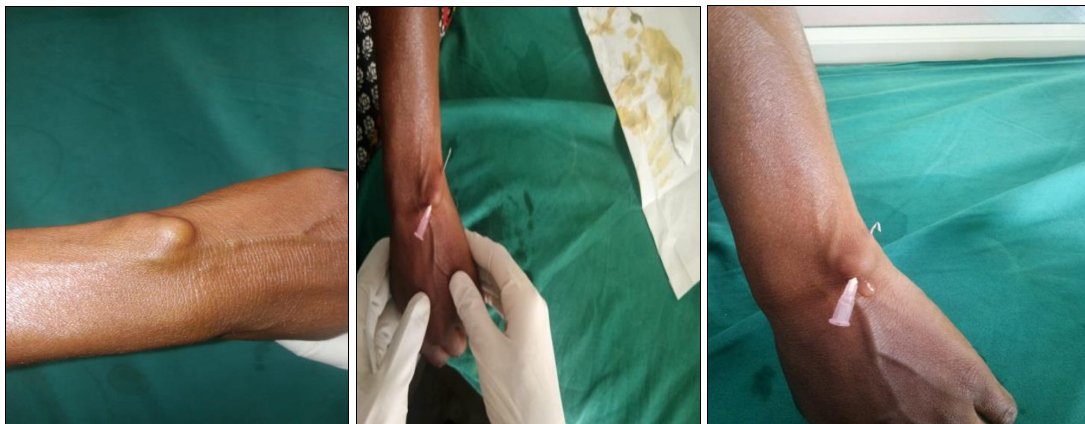
### Surgical technique

The procedure was done on our opd days in minor OT. Parts were scrubbed and prepared like routine surgical procedure. Local anaesthetic agent (Lignocaine 2% plain) was injected at the site of entry and exit of the needle.

### Case 1



### Case 2



Ganglion was punctured at one end with needle and exited from the opposite side of the ganglion, where local anaesthetic was given. Then ganglion was pressed gently but firmly to express out the material. The needle is then bent from the end of exit site with the help of an artery forceps in order to secure the needle in place. Puckering of the skin should be taken care of. Patient is sent home after a sterile dressing supplemented by analgesics and an oral antibiotic. There was no need of restriction of activity or wrist joint immobilization. Patient was encouraged to move wrist immediately after the procedure, which helps to express out the material. Patients were asked to come back after two weeks for needle removal. Patients were then followed up at 1

month, 3 months and 6 months. Patients who had a reappearance of the cyst with size 1 cm or more at the end of six Months were considered to had recurrence.

### Results

Out of the 30 patients included in our study, 28 subjects were completely cured of the symptoms, which gives us a success rate of 93.33%. There were 26 female (86.66%) patients and 4 (13.33%) male patients. Of the total 30 patients, 23 patients (76.66%) had come for the treatment because of pain in the swelling, 7 patients (23.33%) consulted for the cosmetic appearance. The dominant hands were involved more (80%) commonly than the non-dominant one (20%). None of the

patients was treated before by any previous aspiration or surgery. None of the patients developed infection. There were no recurrences up to 3 months follow up. One patient (3.33%) had recurrence at 4 months and was painful and he had to undergo excision. One patient (3.33%) had recurrence at the end of 6 months. Out of the total, 23 patients who presented with the chief complaint of pain were completely relieved of pain and 7 patients who were having apprehension of cosmetic disfigurement, were completely satisfied with their resolution of swellings. None of the patient had any complaint of wrist joint movement or restriction of joint.

**Table 1: Incidence**

Total	Male	Female
30	4 (13.33%)	26(86.66%)

**Table 2: Reason for intervention**

Reason	No
Pain	23 (76.66%)
Cosmesis	7(23.33%)

**Table 3: Age**

Age (Yrs)	No
10-25	10(33.33%)
25-40	16(53.33%)
40-55	4(13.33%)

## Discussion

The ganglion is a pseudocyst, i.e walls formed by fibrous tissue compressed non secretory that gives a presentation as a well-defined nodule, thin walled, and firm which has a gelatinous substance viscous(mucin) and which is always in contact with a capsule or articular synovial sheath. In spite of the common occurrence of these cystic lesion, there are various treatment protocols practiced till date. So regarding the treatment of ganglion, a large number of methods have been reported in the literature, bursting of the ganglion manually thumping with a heavy book (traditionally “the Bible”) being the most ancient one<sup>[9]</sup>.

it was noted that ganglia taking no treatment occasionally give history of spontaneous disappearance<sup>[10]</sup>. Different treatments include aspiration alone<sup>[11]</sup>, aspiration combined with steroid<sup>[3, 12]</sup> or hyaluronic acid injection<sup>[13]</sup>, surgical excision<sup>[1, 13]</sup>, injection of sclerosing agent<sup>[9]</sup>, manual rupture, cyst wall puncture with a needle, trans-fixation with silk suture<sup>[6, 7]</sup> and x-ray therapy<sup>[14]</sup>.

Comparison of surgical excision with aspiration and steroid injection showed wide gap in the results<sup>[3]</sup>, with success rate of around 94% for surgical excision and mere 61% for aspiration and steroid injection.

Varying rates of success of these methods have been reported which shows considerable variations. High recurrence rates ranging from 2-60%<sup>[15, 16]</sup> have been reported following various methods of treatment of the ganglion in the literature. The recurrence rate of ganglions is quite high after surgery. The recurrence rate was around 40% given in many of the reviews.

McEvedy reported a 40% failure rate following ‘simple’ excision<sup>[18]</sup>. Other modes of therapy such as crushing, aspiration and injection also reported comparable recurrence rates<sup>[17]</sup>.

Recurrence rate was further reduced by newer technique which is ‘radical’ excision, in which the ganglia were excised with an underlying portion of the joint capsule. Angelides and

Wallace (1976)<sup>[7]</sup> and Clay and Clement (1988)<sup>[10]</sup> reported recurrence rates of 1-5% compared to ‘simple’ excision which had its untoward effects. This procedure however had its own complications. Angelides and Wallace reported a loss of volar flexion from 0° to 10° in 6 patients<sup>[7]</sup>. There was loss of 2 to 3 weeks of work for men doing heavy labour of Complications reported in other series include joint stiffness, persistent pain, scapholunate dissociation, and decreased grip strength. There were also the risks of general anaesthesia and upper limb tourniquets application<sup>[9, 10, 19]</sup>.

Patients who were treated with aspiration and injection of various medications showed cure rates of 57-64% while those treated with surgical excision showed good cure rates of 84-94%.<sup>[15,18]</sup> Injection therapy reported the advantages in the form of relatively low recurrence rate (18%), no scar, simple out-patient treatment which can readily be given by junior doctor, no risk to tendons or neighbouring structures, joints, no worsening of the appearance even if injection fails to cure<sup>[18]</sup>.

All of the above mentioned controversies led to the search of new safer and equally reliable treatment and technique for dorsal wrist ganglia. In the present study of transfixation method, we passed an appropriate syringe needle through the ganglion which leads to inflammation. Needle inside acts as a foreign body and provokes a strong inflammatory response.

The needle acts as a foreign body and induced acute inflammation within 24 hours, and due to the continuous presence of needle in place, lying down of granulation tissue occurs mainly by activation of the fibroblasts present in the wall of the ganglion by 3 to 4 days. Fibrosis is finally completed by 8-10 days, thus thickening the cyst wall and hence spontaneous regression of ganglia. Prolonged contact with the needle causes more fibrosis yielding better success rate.

There are many advantages to our method. There is no need of hospitalization and the problems of scar, keloid formation and hypertrophy are completely avoided. Patients were able to return to work the following day after the procedure.

In our study of 30 cases treated by transfixation technique using a needle, we achieved a cure rate of 93.33% (34 cases) and recurrence rate of 6.66% (only two recurrence), while Kapoor *et al.* in a similar study<sup>[22]</sup>, of the 108 cases, 102 cases were followed, cure rate was 96% with recurrence rate of 4%. In another study carried out by Gang and Makhlof of the 70 cases treated<sup>[19]</sup>, 62 were followed, 95% were cured while 5% had recurrence. As per the literature in various studies for conservative and operative management of ganglion the recurrence rate is variable from 2-60%<sup>[15, 16]</sup>. With advances in technology, arthroscopic resection has been reported to very low recurrence rate of 0-5%<sup>[20]</sup>, but the expertise needed and the long learning curve is the major limitation with this method.

On comparing our results for the recurrence and cure rate with various studies we could achieve comparative low recurrence rate and high cure rate, so this proves trans-fixation technique using a syringe needle is a successful method of treatment of the ganglion.

## Conclusion

The use of our minimally invasive transfixation technique using a syringe needle for the treatment of ganglion which can be done as an outdoor procedure in the minor operation theatre, is cost effective, less time consuming, low rate of recurrence, can be carried out under local anaesthesia and not requiring any special instrument. No complications as

compared to the surgical excision. Acceptance and compliance to the treatment by the patient is excellent. A technique which can be grasped easily. It can be best alternative to surgical excision of ganglion.

Mustapha B. Arthroscopic resection of dorsal wrist ganglia and treatment of recurrences. *J Hand Surg.*

## References

1. De Villiers CM, Birnie RH, Pretorius LK, Vlok GJ; Dorsal ganglion of the wrist--pathogenesis and biomechanics. Operative v. conservative treatment; *S Afr Med J.* 1989; 75(5):214-6.
2. Nahara ME, Bucchieri JS. Ganglion cysts and other tumour related conditions of the hand and wrist, *Hand Clin.* 2004; 20(3):249-60.
3. Khan PS, Hayat H. Surgical excision versus aspiration combined with intralesional triamcinolone acetate injection plus wrist immobilization therapy in the treatment of dorsal wrist ganglion; a randomized controlled trial; *J Hand Microsurg.* 2011; 3(2):55-7. doi: 10.1007/s12593-011-0039-6. Epub 2011 Apr 20.
4. Thournburg LE, Ganglions of hand and wrist. *J AM AcadOrthop Surg.* 1999; 7(4):231-8.
5. Minotti P, Taras JS. Ganglion cysts of the wrist. *J American society for surgery of Hand.* 2002; 2:102-7.
6. Shapiro PS, Seitz WH. Non neoplastic tumours of the hand and upper extremity. *Hand Clinics.* 1995; 11:133-60.
7. Angelides AC. Ganglions of the hand and wrist. In: Green DP, *Operative hand surgery.* 2nd Ed. New York: Chirchill Livingstone. 1998, 22:81-99.
8. Burke FD, Melikyan EY, Bradley MJ, Dias JJ. Primary care referral protocol for wrist ganglia, *postgrad Med J.* 2003; 79:329-331.
9. Paul AS, Sochart DH. Improving the results of ganglion aspiration by the use of hyaluronidase. *J Hand Surg.* 1997; 22-B:219-221.
10. Clay NR, Clement DA. The treatment of wrist ganglia by radical excision. *J Hand Surg.* 1988; 13-B:187-191.
11. Head L1, Allen M2, Boyd KU2. Long-term outcomes and patient satisfaction following wrist ganglion aspiration; *PlastSurg (Oakv).* 2015; 23(1):51-3.
12. Varley GW1, Needoff M, Davis TR, Clay NR. Conservative management of wrist ganglia. Aspiration versus steroid infiltration. *J Hand Surg Br.* 1997; 22(5):636-7.
13. Craik JD, Walsh SP. Patient outcomes following wrist ganglion excision surgery. *J Hand Surg Eur.* 2012; 37(7):673-7. doi: 10.1177/1753193411434376. Epub 2012.
14. Noppachrt L, Vajara W. Randomized controlled trial between surgery and aspiration combined with methylprednisolone acetate injection plus wrist immobilization in the treatment of dorsal carpal ganglion. *J M Assoc Thai.* 2004; 87(12):1513.
15. Nelson CL, Sawmiller S, Phalen GS. Ganglion of the wrist and hand. *J Bone Joint Surg Am.* 1972; 54:1459-64.
16. Muddu BN, Morris MA, Fahmy NR. The treatment of ganglia. *J Bone Joint Surg Br.* 1990; 72:147.
17. De Orsay RH, Mecray PM, Ferguson LK. Pathology and treatment of ganglion. *Am J Surg.* 1937; 36:313-9.
18. McEvedy BV. The simple ganglion: a review of the modes of treatment and an explanation of the frequent failures of surgery. *Lancet.* 1954; 266:135-136.
19. Gang RK, Makhlof S. Treatment of ganglia by a thread technique. *J Hand Surg.* 1988; 13-B:184-186.
20. Luchheti R, Badia A, Alfaramo M, Orbay J, Indriago I,