

ISSN: 2395-1958

IJOS 2018; 4(4): 591-594

© 2018 IJOS

www.orthopaper.com

Received: 11-08-2018

Accepted: 15-09-2018

Dr. Kalyanasundaram Sivaprasad

Associate Professor, Department
of Orthopaedics, Rajarajeshwari
Medical College, Bangalore,
Karnataka, India

Dr. Ullas Mahesh

Assistant Professor, Department
of Orthopaedics, Rajarajeshwari
Medical College, Bangalore,
Karnataka, India

Dr. Pradeep Bhosale

Senior Consultant & HOD,
Orthopaedics Nanavati Hospital,
Ex- professor and HOD, Seth GS
Medical College and KEM
Hospital, Karnataka, India

Steffee plating in management of fracture spine

Dr. Kalyanasundaram Sivaprasad, Dr. Ullas Mahesh and Dr. Pradeep Bhosale

DOI: <https://doi.org/10.22271/ortho.2018.v4.i4g.66>

Abstract

Introduction: The diagnosis of a broken back has carried an ominous prognosis, since antiquity. In the writings of ancient Egyptians, as recorded in Edw Smith papers, traumatic quadriplegia was considered a, “condition not to be treated “. However, with modern treatment, the outlook towards these patients have changed for the better.

Results: Case series consisted of 33 cases, follow up period was from 5 months to 4 years. In most of the cases, implant removal was done after one to one and half years, depending upon fusion, reduction & bone implant relationship. In most of the patients good fusion in reduced position with no loosening around implants were noted.

Conclusion: Since pedicular screws & plates, Steffee variable screw placement (VSP type) fits on both sides of spine, they maintain the reduced and decompressed spine till such a time, when bony fusion occurs, since less load is shared by each plate.

Keywords: Steffee plating, variable screw placement (VSP type), fracture, Thoraco-lumbar spine

Introduction

The diagnosis of a broken back has carried an ominous prognosis, since antiquity. In the writings of ancient Egyptians, as recorded in Edwin Smith papers, traumatic quadriplegia was considered a, “condition not to be treated “. However, with modern treatment, the outlook towards these patients have changed for the better.

Treatment of fractures and fracture dislocations of the spine with neurological deficit have varied over the last century. The main question centers around, as to how well one can reduce and stabilize the fracture dislocation.

Guttmann (1949), pioneered the conservative approach to the treatment of these injuries. Now, many centers advocate early aggressive approach in stabilization followed by early mobilization to prevent the secondary complications seen with conservative management.

The main objectives are:

1. Achieving a good acceptable anatomical alignment.
2. Decompression of the spinal cord.
3. Providing stability.

By doing this supportive care was easier and it provided a stabilized pain free spine, with a favorable environment for a possible neurological recovery.

Many types of internal fixation have been used with or without external support.

In the beginning, no metal was available for fixation, that electrolysis would not loosen in a few months. With the advent of newer techniques and friendly materials, internal fixation came of age.

Fixation of spinous processes with plates & screws (Holdsworth 1953, Lewis & Mc Kibbin 1974-79), proved not only a tedious procedure but also a poor fixation. Stabilization by 2 Harrington rods achieved near anatomical reduction & stability, but required fixation of the long segment of the spine which affected spinal mobility considerably.

Steffee plate with pedicular screws fixation for fracture spine stabilization & fusion has been a revolutionary concept in recent years. While providing satisfactory reduction & stabilization, it requires fixation of only a short spinal segment.

Correspondence

Dr. Ullas Mahesh

Assistant Professor, Department
of Orthopaedics, Rajarajeshwari
Medical College, Bangalore,
Karnataka, India

In our study, we have tried to analyze fixations of Thoracolumbar fractures with Steffee plates, variable screw placement (VSP type) and pedicular screws.

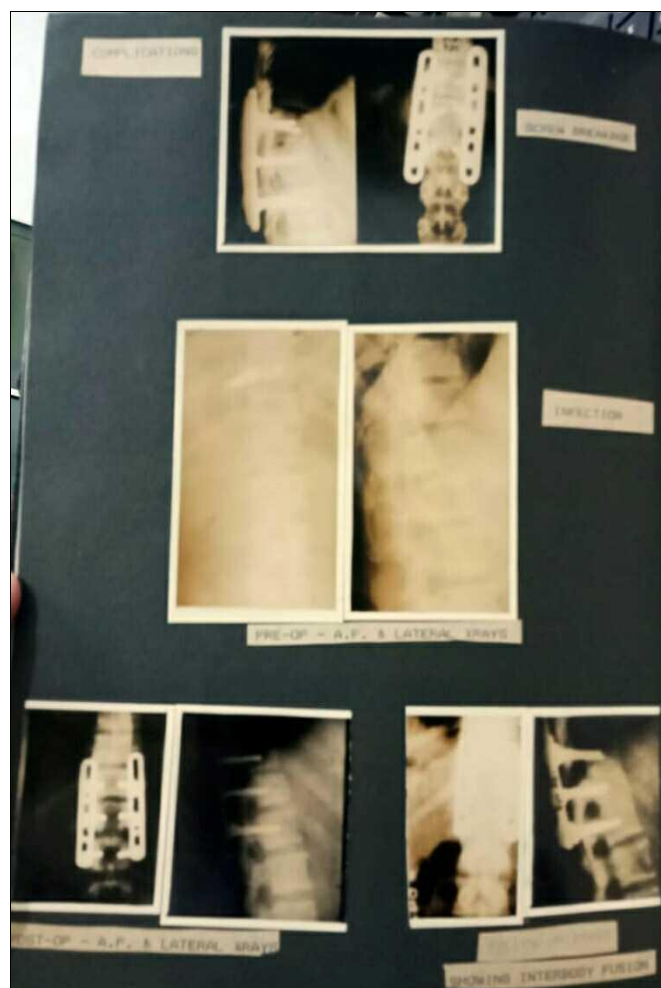
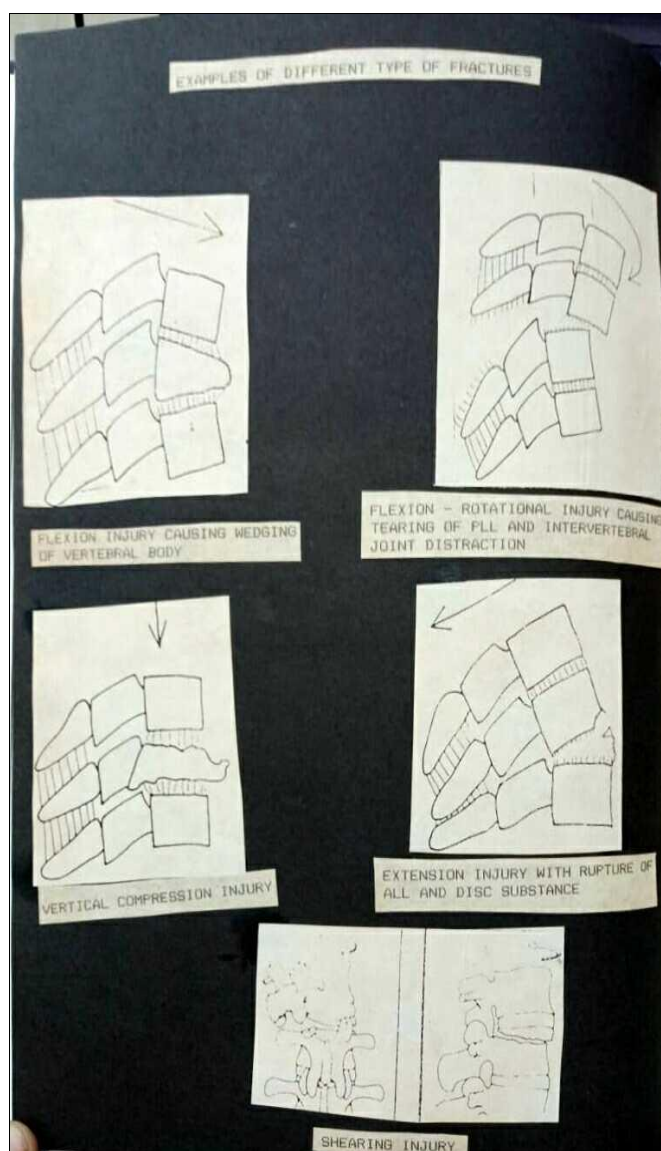
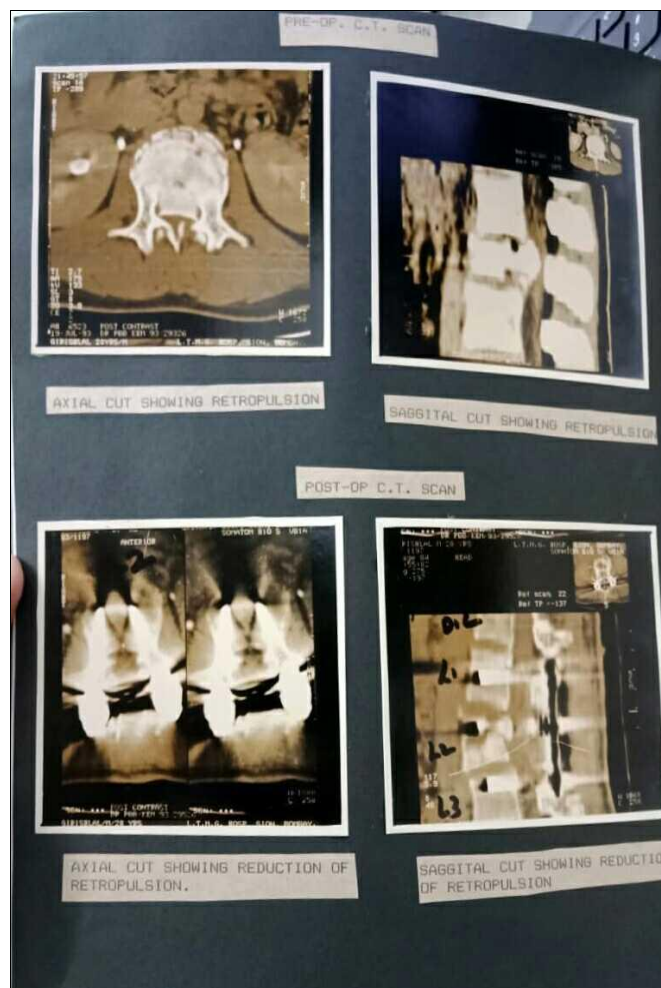
Materials and methods

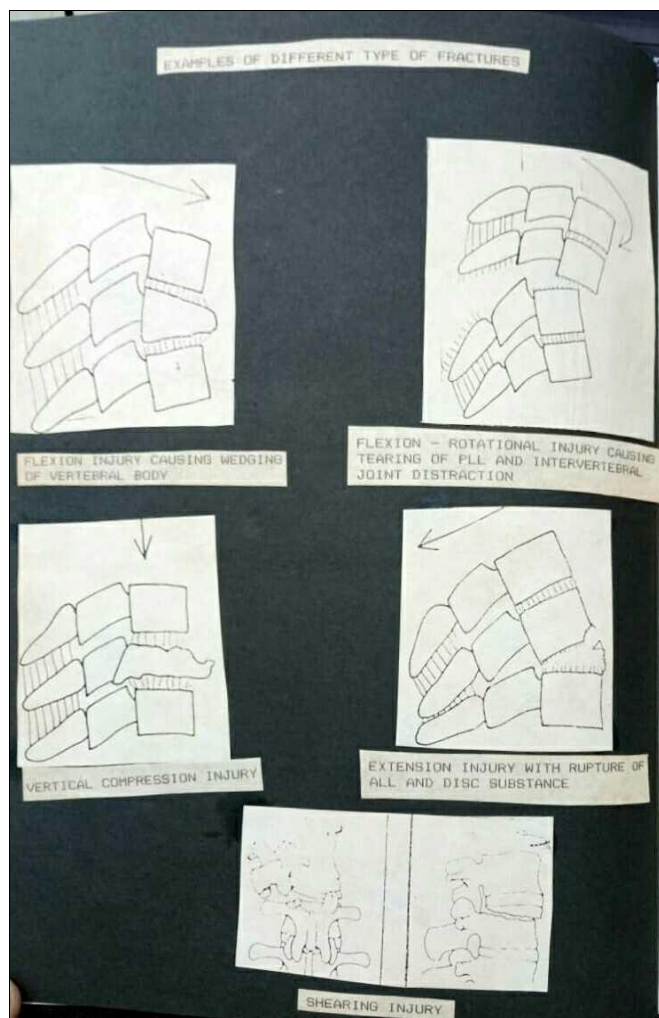
This study consisted of case series of 33 cases, follow up period was from 5months to 4years. The case series consisted of fracture and fracture-dislocations of thoracic and lumbar spine with or without neurological deficit. These were treated by 3-level fixation with pedicular screws and Steffee (VSP) plates.

Data regarding these patients was noted in the following manner:

- Name, age and sex.
- Detailed history to ascertain the mode and type of injury, neurological status following injury and after, any treatment taken.
- In general and systematic examination to rule out life threatening injuries and other associated fractures.
- A detailed examination of the spine to localize tenderness and to look for widened inter spinous distance.

Radiological assessment was then done with anteroposterior and lateral projections denoting fracture level and type. Stability was also judged from X-rays. Nine patients underwent CT scan preoperatively for better assessment.





Results

Post operative neurological status

Grade	Number of cases
A	3
B	7
C	4
D	14
E	5

Recovery assess by Frankel Grade

Pre Op Grade		Post Op Grade				
A	5	A	B	C	D	E
B	12	3	1	0	1	0
C	8	0	6	4	2	0
D	7	0	0	0	7	1
E	1	0	0	0	4	3
		0	0	0	0	1

Improvement by 1 Grade -15

Improvement by 2 Grade – 3

Improvement by 3 Grade – 1

14 patients did not have any improvement over their preoperative neurological status.

Level of fixation

One level above, One level below & One level through the fractured vertebra. Here we can see all cases were fixed by One level above & One level below which is an advantage over Harrington rod fixation.

Quality of reduction

There was reduction of retropulsion & good restoration of vertebral height in all cases which was maintained in the follow up. The hold of the screw in the fractured vertebra was good in all the cases.

Decompression

Laminectomy & pushing the fractured fragment anteriorly by punch with global decompression in all cases.

Bone grafting & fusion

All cases were fused with posterior H graft & posterolateral grafts. Follow up X rays showed good fusion in most of the cases.

Postoperative urinary function

Patients on CSIC- 12

Normal bladder function-21

Percentage of recovery in each grade

Grade	Percentage
A	15%
B	30%
C	60%
D	70%

It can be seen that patients with partial deficit had better chances of recovery.

Fracture level distribution

Majority of the cases fall between D12 & L2.

Relation of recovery to the fracture level

Fracture Level	Recovery In %
D11,D12	50%
D12	57%
L1	92%
L2	75%
L4	100%
D12,L1#	0%

Relation of recovery to type of injury

Type of Injury	Recovery In %
Wedge compression #	78%
Burst #	67%
#	0%

Lumbar level & of wedge compression type show the maximum recovery. The recovery is poorest in fracture-dislocations at any level, which maybe due to severe cord injury.

Post operative complications

Infection	1
Breakage Of Screw	1

There was no loosening in any of the cases. In one patient, infection in the form of discharging sinus was noticed at five months, which persisted till plate removal at one year. In this case, in addition to posterior & posterolateral fusion, inner body fusion also occurred leading to a good result in spite of the complication. In another patient, who followed up after one year with pain, it was found that one of the screws had broken at the plate screw junction. An implant removal was

done on him & his pain was relieved.

In most of the cases, implant removal was done after one to one and half years, depending upon fusion, reduction & bone implant relationship. As stated earlier, in most of the patients, good fusion in reduced position with no loosening around the implants were noted.

Discussion

Controversies rage high, as to the ideal solution to the management of thoracolumbar spine fractures. Only when a conclusive evidence in support of surgical treatment, backed with concrete ground surfaces, can put to rest the conservative means of management. In order literature, published whether treated by operative or non operative means, results of neurologic recovery are consistent which lends credence to Guttman's (1949) belief that, the most important factor determining neurologic recovery is the damage sustained by the neural tissue at the time of the accident, rather than the anatomic circumstances in which subsequently finds itself. This leads to the gloomy conclusion, that the best one can do for the neural tissue is to prevent further damage.

Fixation by Steffee (VSP) plate with pedicular screws achieves the following

1. Stabilizing the injured spine.
2. Reduction of dislocated vertebrae.
3. Re-establishment of spinal canal space.
4. Correction of bony deformity
5. Reduces the anterior pressure on the cord and nerve roots.
6. Does not reduce the spinal mobility, because fixation is usually one vertebra above and one below the fractured one.
7. Requires a small incision for surgery.

As far as neurological recovery goes. No instrumentation can restore back the function to the spinal cord. Surgical stabilization only prevents further damage & provides the best environment for the recovery of the undamaged cord & roots. Frankel's study (1969) of 682 patients treated by conservative means, showed that although recovery rates are comparable to the surgical methods, 3% showed neurological deterioration. Recovery in the partial lesion was only 63% as compared to the surgical means where it was 80-100%.

In the present series, there is 50% recovery in complete lesions & 100% recovery in partial lesions, of those who recovered, almost 80% had useful power.

Good to excellent results in majority of their patients have been reported and thus these studies have recommended its use in thoracolumbar trauma. Poor results have also been reported by few and were attributed to the extensive comminution of the vertebral body and lack of anterior column support.

Decompression is assuming increased importance in the approach towards neurological salvage. Laminectomy alone, makes the spine more unstable & does not decompress at all when the decompression in anterior and is therefore to be criticized.

Conclusion

1. Fracture or fracture dislocation of spine like other fractures requires good reduction & adequate immobilization, to ensure anatomic alignment & stability of the spine.
2. Surgical treatment of the fracture or fracture dislocation of the spine at the Dorso- lumbar region, is definitely

superior to conservative treatment in terms of rehabilitation, nursing care, mobilization & prevention of complications of recumbency.

3. The pedicular screw plate fixation, Steffee (VSP type) with one level above & below the fracture vertebra offered good reduction to the spine as well as good decompression.
4. Since pedicular screws & plates, Steffee (VSP type) fits on both sides of the spine, they maintain the reduced & decompressed spine till such a time when bony fusion occurs, since less load is shared by each plate.
5. It prevents the late problems of pain, deformity & instability, so that the paraplegics can well do without a painful deformed back to add to their misery.
6. Fixation is heavily indicated in partial neurological lesions & is documented to be superior to conservative management in this category.
7. Decompression has definitive importance in neurological recovery, especially in burst fractures & fracture-dislocations. It is not significant in wedge fractures.
8. Those patients who do not show any neurological recovery, can be discharged early, either in wheel chair or a tricycle, since they are able to sit comfortably & are free of bedsores & urinary tract infections.
9. Thus Steffee (VSP plate) with pedicular screw fixation has brought about an important breakthrough in the management of traumatic paraplegics, when in the absence of specialized centers in our country.

References

1. Armstrong GWD, Johnson DH. Stabilization of spinal injury using Harrington instrumentation. In proceeding of Canadian Orthopaedic Association.
2. Andrew TA, Brooks S, Figott H. Long term follow up evaluation of screw and graft fusion of lumbar spine. Clinical Orthopaedic and related research. 1986; 203:113-119.
3. Asher MA, Walter E. Stringppgen Anthropometric Studies of Human Sacrum relating to dorsal trans-sacral implant design Clinical Orthopaedic and Related Research. 1986; 203:57-61.
4. Whitecloud III TS, Bulter JC, Cochen JL, Candelora PD. Complication with the variable spinal plating System. Spine. 1989; 14:472-76.
5. Sahu SC, Goyal RK, Gupta AK. Transpedicular Steffe Plate fixation thoracolumbar spine injuries. Ind J Orthop. 1995; 29(1):9-11.
6. Frankel *et al*. The value of postural reduction in the initial management of closed injuries of the spine with paraplegia. Paraplegia. 1969; 7:179.
7. Steffee AD, Discup RS, Sitkowski DJ. Segmental Spine Plate with pedicle screw fixation. (A new internal fixation device for disorders of lumbar and thoracolumbar spine). Clinical Orthopaedics and Related Research. 1986; 203:45-53.
8. Steffee AD. The variable screw placement system with posterior lumbar inter-body fusion by Dr. P.S. Ramani, 1990.
9. Dickson JH, Harrington PR, Erwin WD. Harrington instrumentation in the fractured unstable thoracic and lumbar spine Texas Med. 1973; 69:91-90.
10. Roy Camille R, Saillant G, Mazel CH. Internal Fixation of lumbar spine with pedicle screw and plates. Clinical Orthopaedics and Related Research. 1986; 203(7-17):198.