



International Journal of Orthopaedics Sciences

ISSN: 2395-1958
IJOS 2018; 4(4): 84-88
© 2018 IJOS
www.orthopaper.com
Received: 19-08-2018
Accepted: 23-09-2018

Dobhal Aviral
Senior Resident, Orthopaedics,
AIIMS Rishikesh, Uttarakhand,
India

Patel H Keval
Post Graduate, Orthopaedics,
Santokba Durlabhji Memorial
Hospital, Jaipur, Rajasthan,
India

Shrivastava Shailendra
Senior Consultant, Orthopaedics,
Santokba Durlabhji Memorial
Hospital, Jaipur, Rajasthan,
India

Soni SS
Senior Consultant, Orthopaedics,
Santokba Durlabhji Memorial
Hospital, Jaipur, Rajasthan,
India

Dobhal Priyanka
Senior Resident, Community &
Family Medicine, AIIMS
Rishikesh, Uttarakhand, India

Role of proximal femoral nail anti-rotation in extracapsular proximal femoral fractures

**Dobhal Aviral, Patel H Keval, Shrivastava Shailendra, Soni SS and
Dobhal Priyanka**

DOI: <https://doi.org/10.22271/ortho.2018.v4.i4b.18>

Abstract

Background: Peritrochanteric fractures are devastating injuries involving young and adult population and needs surgical fixation. But there are many complications related to fixation devices & quality of bone. In view of this surgical management of peritrochanteric fractures by other better device is taken up.

Material & Method: Twenty five patients with peritrochanteric fracture were included as per inclusion & exclusion criteria. Radiographic & functional outcomes of PFNA II along with its intra & post-operative complications is evaluated.

Result: Out of 25 cases there were 13 males and 12 females with age ranging from 22- 95 yrs. Mean duration of hospital stay, operative time & blood loss was 6.28 ± 3.4 days, 54.60 ± 11.71 min & 102.80 ± 15.41 ml respectively. Radiologically ideal implant position in 88% cases & good/ acceptable reduction in 92 % patients was achieved. Good to excellent functional results of operated hip were seen in 62 % cases of peritrochanteric fractures. Intraoperative complications like fracture of lateral cortex & greater trochanter along with fixation of fracture in varus angulation in one case & failure to get anatomical reduction resulting in varus angulation in other case. Postoperatively two patients had deep vein thrombosis & two patients had shortening >4 CMS.

Conclusion: PFNA II is very effective & good fixation implant for unstable peritrochanteric fractures.

Keywords: peritrochanteric fractures, PFNA II, complication, functional outcomes

1. Introduction

Extracapsular proximal femoral fractures i.e peritrochanteric fractures mainly comprise of fracture of trochanteric and subtrochanteric region & are considered as devastating injuries that mostly affects female & elderly population due to osteoporosis and in younger population mainly due to high velocity trauma. Fixation of these fractures become difficult task due to osteoporotic bones, unstable fracture pattern & increases complications like screw cut-out when DHS is used to fix fractures. In view of this, the present study of surgical management of peritrochanteric fractures by other better fixation device is taken up. PFNA II is latest implant for management of peritrochanteric fractures which is also a collapsible device with added rotational stability. The purpose of the study was to evaluate radiographic & functional outcomes of proximal femoral nail antirotation (PFNA II) in Extra-capsular proximal femur fractures and to assess Intra-and postoperative complications of PFNA II.

2. Material & Method

2.1 Material: A Hospital based observational descriptive interventional study without control was done on twenty five patients with peritrochanteric fractures admitted in our institution from 4 April 2014 to 4 April 2015 & fulfilling following inclusion criteria i.e. fresh or within one week of injury, peritrochanteric fracture of either sex without any associated neural or vascular injuries & exclusion criteria i.e. unable to walk before injury, pathological fracture, isolated or combined medial femoral neck fracture.

2.2 Implant details: PFNA II consists of an intramedullary nail & helical blade. Nail has proximal 5° mediolateral angulation & is available in short & long version with different length & diameter. Angle of 125° & 130° between blade & nail are possible.

Correspondence

Dobhal Priyanka
Senior resident, Community &
Family Medicine, AIIMS
Rishikesh, Uttarakhand, India

Helical blade is available in different incremental length. It has option for static & dynamic locking.

2.3 Surgical methods: Reduction of fracture was done on a fracture table under image intensifier control. Affected limb was positioned in 10-15° of abduction to facilitate nail insertion. An incision of 5 cm proximal to tip of trochanter was made, fascia & fibres of gluteus medius was splitted along its length to reach tip of trochanter, with the help of bone awl entry point over tip of trochanter was made & 3.2 mm guide wire was inserted along the length of femur & position checked in AP & lateral view under C-arm. With soft tissue retracted serial incremental reaming starting with 9 mm medullary reamer done. Appropriate diameter of femur medulla depending upon fracture pattern (Intertrochanteric/subtrochanteric) appropriate length of nail was mounted on insertion handle & was introduced manually into the femur. The 130° aiming arm was attached to the insertional handle & through small lateral incision the guide wire for PFNA II blade was inserted, ensuring central position in the femoral head in AP& lateral view. Length of PFNA II blade was

measured and attached to the inserter. The outer cortex was opened with an 11 mm drill & femoral neck & head reamed with an 11 mm cannulated reamer. The blade was inserted over the guide wire, monitoring was done during insertion of the blade to the stop by applying gentle blow with the hammer. The PFNA II blade was locked by turning the impactor clockwise. Distal locking was performed by the free hand technique for long PFNA II & by using the Jig for standard PFNA II. Patients were evaluated post-operatively by reduction & implant position on X-ray hip AP & lateral view. The quality of fracture reduction was graded as good, acceptable (5-10° varus/ valgus & antiversion / retroversion) & poor (> 10° varus /valgus & antiversion/ retroversion).

The position of PFNA II blade was graded as good if it was placed into the lower half of the neck on the AP view & centrally on a lateral view.¹ Patient were followed up in OPD after 15 days at the interval of one, three and six months. On the final follow up at 6-month functional hip scoring was done using modified Harris hip score^[2]. Excellent (90-100), good (80-89) & fair (70-79), poor (<70).

Table 1: Post-operative radiological evaluation of fracture reduction and implant position & functional assessment of operated hip based on modified Harris hip score.

	Result	Number of Cases	Percentage
Reduction of Fracture	Good	20	80%
	Acceptable	3	12%
	Poor	2	8%
Implant Position	Good	22	88%
	Poor	3	12%
Modified Harris hip score	1. Excellent	7	28
	2. Good	8	32
	3. Fair	6	24
	4. Poor	2	8
	5. Loss of follow up	1	4
	6. patient expired	1	4

3. Results

In our study of 25 cases, there were 13 males and 12 females with age ranging from 22- 95 yrs with mean age of 62.68±22.77 yrs. fifteen patients from 25 cases were admitted due to slip and fall, 8 due to road traffic accident & 2 from fall from height with slight right sided predominance. Out of 25 cases, 18 were inter-trochanteric and 7 were sub-trochanteric. In Trochanteric class 50% were Boyd and Griffin type 3, in Subtrochanteric class 71.43 % were Seinsheimer type 2b and 14.29% type 2a & type 2c each. 9 patients had associated medical conditions. Mean duration of hospital stay, operative time & blood loss was 6.28±3.4 days,

54.60±11.71 min & 102.80±15.41 ml respectively. Radiologically we were able to achieve ideal implant position in 88% cases & good/ acceptable reduction in 92 % patients. Good to excellent functional results of operated hip were seen in 62 % cases of peritrochanteric fractures (Table 1).

In our study we faced intraoperative complications like fracture of lateral cortex & greater trochanter along with fixation of fracture in varus angulation in one case & failure to get anatomical reduction resulting in varus angulation in othercase (Fig.3). Postoperatively we had Deep Vein Thrombosis in two patients from which one expired & in two patients we had shortening >4 cms (Table 2).

Table 2: Intra-operative and Post-operative complications.

	Complication	No. of cases
Intra-Operative Complications	Failure to get anatomical reduction/Varus angulation	2
	Trochanter & lateral cortex femur fracture during insertion of PFNA II	1
Post-Operative Complications	DVT	2
	Shortening > 4 CM	2
	Expired (Due to DVT)	1

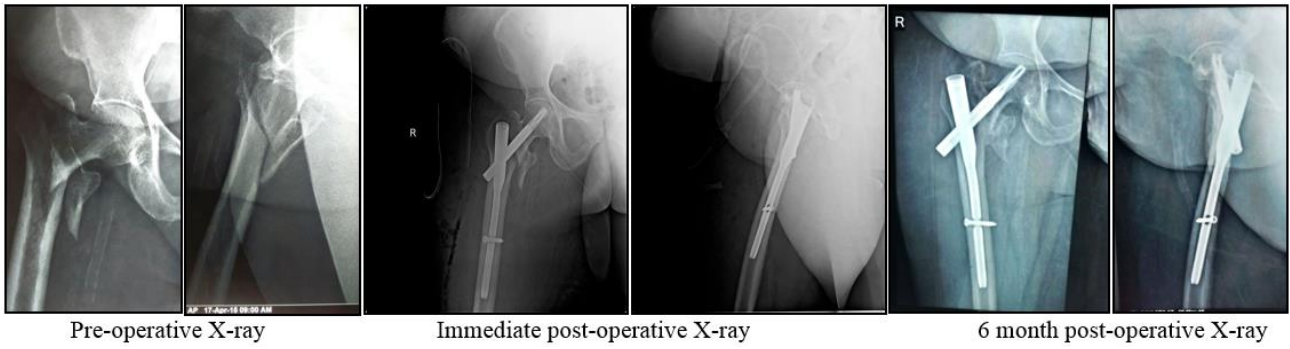


Fig 1: Pre-operative & Post-operative X-ray of Intertrochantric fractures

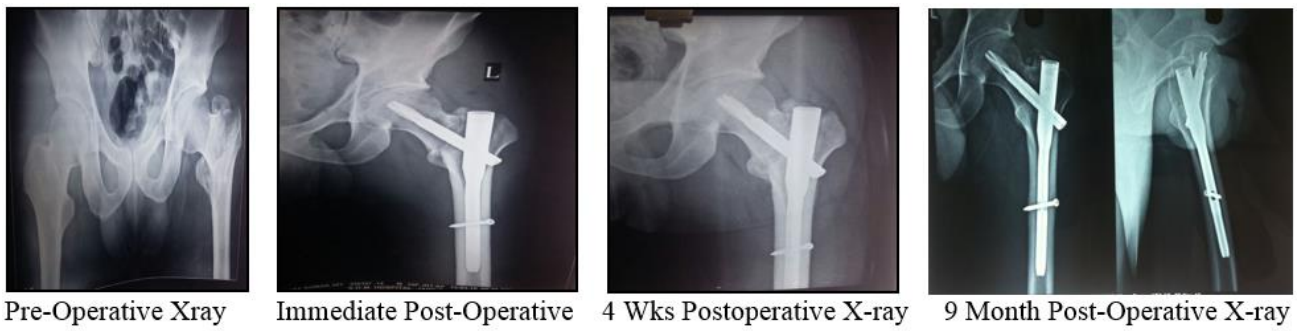


Fig 2: Pre-operative & Post-operative X-ray

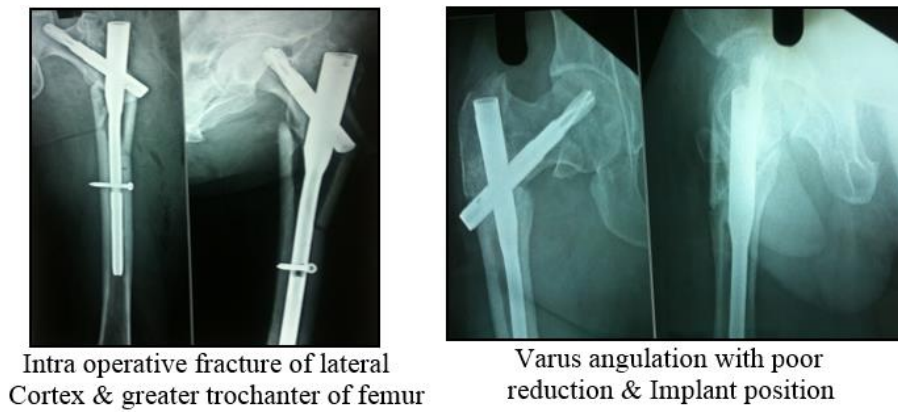


Fig 3: X-rays of Intraoperative & postoperative complications.

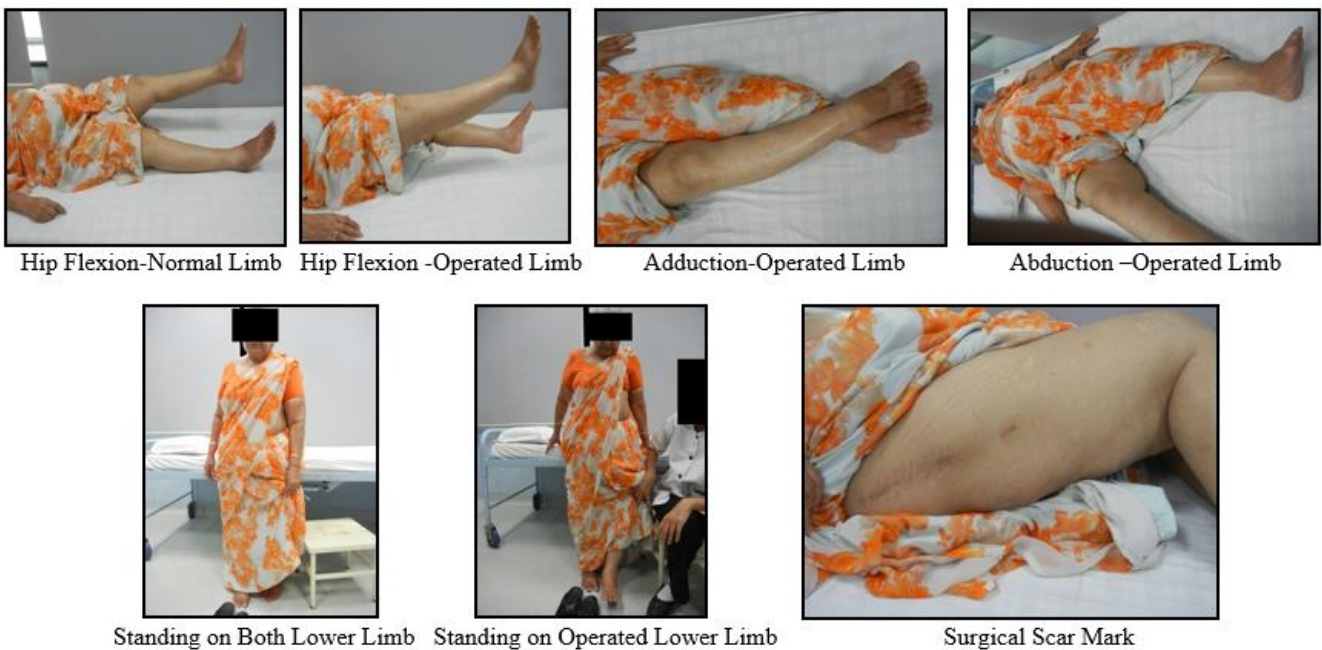

Fig 4: Post-operative functional range of motion in operated hip

4. Discussion

There has been a long debate concerning the preferred implant for stabilization of peritrochanteric femoral fractures. Two broad categories of internal fixation devices are commonly used for peritrochanteric femoral fractures, sliding compression hip screws with side plate assemblies and intramedullary fixation devices.

Sliding hip screws are the most commonly used devices. Thus far, stable trochanteric fractures have been successfully stabilized using the Dynamic Hip Screw (DHS) which provides controlled compression at the fracture site with a low rate of complications. However, insertion of the DHS requires a relatively larger exposure, more tissue handling and anatomical reduction, which increases the risk of infection and entails larger blood loss & significantly longer operative time than the intramedullary devices. In our study, operating time and blood loss seemed to be lower compared to DHS but on the contrary radiological exposure in DHS is less [3, 4]. There was, however, no significant difference in the final functional outcome between the two groups [5].

A series of biomechanical and clinical studies have proven that the DHS as an extramedullary implant is inferior to intramedullary implants in the treatment of unstable fractures [6, 7]. Relatively high price of intramedullary device such as PFNA II or Gamma Nail and good results achieved in stable fractures makes the DHS still the implant of first choice in stable trochanteric fractures.

Some studies have indicated that intramedullary devices may facilitate postoperative rehabilitation [8, 9]. One reason could be that the greatest dynamic effect in patients with the DHS occurs in the early postoperative period and this change in the fracture position can affect early walking ability. Another reason may be the greater exposure and more extensive muscle release required in the DHS technique. Although intramedullary fixation devices have the advantage of immediate full weight bearing, we took a more conservative rehabilitation programme.

From a biomechanical point of view, an intramedullary device inserted via a semi-closed procedure is to be preferred, especially in elderly patients. These implants, such as the gamma nail, PFN & PFNA II device, withstand higher static and several fold higher cyclical loading than the DHS type of implant. However, the previously used intramedullary device, the Gamma nail, is technically demanding and not forgiving with high rates of fractures of femoral shaft [10-12]. In comparison to our study we had only one case in which there is intraoperatively fracture of greater trochanter & fracture of lateral cortex of femur while introducing implant.

The PFN was developed to solve problems such as the perioperative and postoperative technical complications including anterior thigh pain and fracture of the femoral shaft described in patients treated with the gamma nail [13-15]. By having a smaller distal shaft diameter, which reduces stress concentration at the tip. Cut-out, possibly as the result of varus deviation and rotation, is still one of the most important considerations. These patterns of fixation failure are most often directly due to insufficient purchase of the implant in the femoral neck.

According to the literature, these complications, which necessitate reoperation, occur in 3% to 7% of cases [8, 15-17]. In our study, the reoperation rate is 0% & operating time and operative blood loss seemed to be lower, compared with previous study of the PFN [8, 15, 16, 18]. Although more accurate analysis with a randomized clinical trial is necessary.

The PFNA II was developed as an alternative to the PFN with

a special helical blade. The helical blade allows improved purchase in the femoral head by radial compaction of the cancellous bone around the blade during insertion [19-21]. Biomechanical tests have demonstrated that the blade has a significantly higher cut-out resistance & improved purchase in osteoporotic bone than commonly used screw systems [22], thus more suitable implant for unstable trochanteric fractures and trochanteric fractures associated with osteoporotic bone.

Thus, the helical neck blade has the advantages of fixation stability, antirotation and anti varus collapse [21]. The PFNA II seems to be associated with a lower incidence of complications.

The ideal implant for the treatment of trochanteric fractures is an easily inserted, intramedullary device that allows for controlled impaction across the fracture zone while preventing fracture site rotation [23]. The device must achieve sufficient purchase in the femoral head in order to delay or resist cut-out.

5. Conclusion

From our study we conclude that PFNA II implant is an optimal & better fixation device for most peri-trochanteric fractures. As their intramedullary placement allowed the implant to lie closer to the mechanical axis of the extremity, thereby decrease the lever arm & bending moment on the implant.

The helical blade may confer additional benefits with osteoporotic trochanteric fractures by cancellous bone compaction ensuring rotational & angular stability with a single component hence better outcome in term of earlier restoration of walking ability. In addition, as the PFNA II requires shorter operative time, ease of implantation, a smaller incision & less surgical trauma, it has distinct advantages over other modes of fixation in both unstable & stable peritrochanteric fractures provided the implantation procedure is scrupulously followed & fracture reduction is optimal.

6. References

1. Lv C, Fang Y, Liu L, Wang G, Yang T, Zhang H *et al.* The new proximal femoral nail antirotation-Asia: early results. *Orthopedics*. 2011; 34(5):351.
2. Harkess James W, Crockarell John R. Arthroplasty of the Hip. In: Canale S Terry, Beaty James H, editors. *Campbell's Operative Orthopaedics*. 12th ed. Canada: Elsevier. 2012, 159-259.
3. Liu Y, Tao R, Liu F, Wang Y, Zhou Z, Cao Y *et al.* Mid-term outcomes after intramedullary fixation of peritrochanteric femoral fractures using the new proximal femoral nail antirotation (PFNA). *Injury*. 2010; 41(8):810-7.
4. Xu YZ, Geng DC, Mao HQ, Zhu XS, Yang HL. A comparison of the proximal femoral nail antirotation device and dynamic hip screw in the treatment of unstable peritrochanteric fracture. *J Int Med Res*. 2010; 38(4):1266-75.
5. Lv C, Fang Y, Liu L, Wang G, Yang T, Zhang H, Song Y. The new proximal femoral nail antirotation-Asia: early results. *Orthopedics*. 2011; 18; 34(5):351.
6. Curtis MJ, Jinnah RH, Wilson V. *Injury*. 1994; 25:99.
7. Adams CI, Robinson CM, Court-Brown CM, *J Orthop Trauma*. 2001; 15:394
8. Simmermacher RKJ, Bosch AM, Van der Werken C. The AO ASIF-proximal femoral nail (PFN): a new device for the treatment of unstable proximal femoral fractures. *Injury*. 1999; 30(5):327-32.

9. Pajarinen J, Lindahl J, Michelsson O, *et al*: Pertrochanteric femoral fractures treated with a dynamic hip screw or a proximal femoral nail. A randomized study comparing post-operative rehabilitation. *J Bone Joint Surg Br.* 2005; 87:76-81.
10. Banan H, Al-Sabti A, Jimulia T, Hart AJ. The treatment of unstable, extracapsular hip fractures with the AO/ASIF proximal femoral nail (PFN): our first 60 cases. *Injury.* 2002; 33:401-5.
11. Harris WH. Traumatic arthritis of the hip after dislocation and acetabular fractures: treatment by mold arthroplasty: an end-result study using a new method of result evaluation. *J Bone Joint Surg Am.* 1969; 51:737-55.
12. Moroni A, Faldini C, Pegrffi F, *et al*. Dynamic hip screw compared with external fixation for treatment of osteoporotic pertrochanteric fractures. A prospective, randomized study. *J Bone Joint Surg Am.* 2005; 87:753-9.
13. Albareda J, Laderiga A, Palanca D, *et al*. Complications and technical problems with gamma nail. *Int Orthop.* 1996; 20:47-50.
14. Butt MS, Krikler SJ, Nafie S, Ali MS. Comparison of dynamic hip screw and gamma nail: a prospective, randomized, controlled trial. *Injury.* 1995; 26:615-8.
15. Herrera A, Domingo LJ, Calvo A, Martinez A. A comparative study of trochanteric fractures treated with Gamma nail or the proximal femoral nail. *Int Orthop.* 2002; 26:365-9.
16. Domingo LJ, Cecilia D, Herrera A, Resines C. Trochanteric fractures treated with a proximal femoral nail. *Int Orthop.* 2000; 25:298-301.
17. Al-yassari G, Langstaff RJ, Jones JW, Al Lami M. The AO/ ASIF proximal femoral nail (PFN) for the treatment of unBuletin of the NYU Hospital for Joint Diseases 2008; 66(4):276-9 279 stable trochanteric fracture. *Injury.* 2002; 16:386-93.
18. Takigami I, Ohara A, Yamanaka K, *et al*. Treatment and surgical technique for trochanteric fracture of the femur with proximal femoral nail. *Seikeigeka (Orthopedic Surgery).* 2005; 56:1747-50.
19. Sommers MB, Roth C, Hall H, *et al*: A laboratory model to evaluate cutout resistance of implants for pertrochanteric fracture fixation. *J Orthop Trauma.* 2004; 18:361-368.
20. Strauss E, Frank J, Lee J, *et al*: Helical blade versus sliding hip screw for treatment of unstable intertrochanteric hip fractures: a biomechanical evaluation. *Injury.* 2006; 37:984-989.
21. Windolf M, Braunstein V, Dutoit C, *et al*: Is a helical shaped implant a superior alternative to the dynamic hip screw for unstable femoral neck fractures? A biomechanical investigation. *Clin Biomech (Bristol, Avon).* 2009; 24:59-64.
22. Committee of Coding Classification of the Orthopaedic Trauma Association. Fracture and dislocation compendium. *J Orthop Trauma.* 1996; 10 (1):31-5.
23. Sommers MB, Roth C, Hall H, *et al*: A laboratory model to evaluate cutout resistance of implants for pertrochanteric fracture fixation. *J Orthop Trauma.* 2004; 18:361-368.