



# International Journal of Orthopaedics Sciences

ISSN: 2395-1958  
IJOS 2018; 4(4): 15-19  
www.orthopaper.com  
Received: 05-08-2018  
Accepted: 07-09-2018

**Dr. Krishnaraj V**  
Department of Orthopaedics,  
Govt Medical College,  
Thiruvananthapuram, Kerala,  
India

**Dr. Shanavas EK**  
Associate Professor in  
Orthopedics, Govt.TD Medical  
College, Alappuzha, Kerala,  
India

**CS Vikraman**  
Professor, Department of  
Orthopaedics, Govt. Medical  
College, Thiruvananthapuram,  
Kerala, India

## Functional outcome of patients after open reduction internal fixation in displaced intra articular calcaneal fractures

**Dr. Krishnaraj V, Dr. Shanavas EK and CS Vikraman**

**DOI:** <https://doi.org/10.22271/ortho.2018.v4.i4a.04>

### Abstract

**Background** There are lot of controversies with management of calcaneal fractures. In this prospective study, we studied the functional outcome of surgically treated displaced intra-articular calcaneal fractures.

**Aim** To evaluate the functional outcome of patients following open reduction internal fixation in displaced intra-articular calcaneus fractures under Dept. of Orthopaedics – Govt. Medical College Hospital, Thiruvananthapuram during the period of 2016-2017. Functional outcome is measured in terms of pain and function.

**Materials and Methods** 72 patients admitted with displaced intra-articular calcaneal fractures and managed with Open Reduction Internal Fixation were observed for 6 months. All fractures were fixed with calcaneal plates, by an extensile lateral approach. Regular follow ups are made at 1 month and 6 months. Functional result was compared by using Maryland foot score and also Bohler's angle.

**Results:** Incidence is much more common in males (90.3%). 20-40 year age group is most commonly affected. The spinal injuries were the most common associated injury (30.6%). Of 72 fractures, 26 were Sander's type IV (36.1%), 25 type II (34.7%) and 21 Type III (29.2%) fractures. 30 patients had Bohler's angle 21-40, 42 had less than 20. The proportion of patients having Bohler's angle <20deg were more in Sander's type IV as compared to types II and III. As Bohler's angle increases, Maryland Foot Score also increases. Complications were present in 18 (25%) patients.

Functional outcome according to Maryland Foot Score were excellent in 23.6%, good in 45.8%, fair in 23.6% and poor in 6.9% cases. Complications include stiffness, implant prominence, wound healing problems, infection and varus deformity.

**Conclusion:** Open reduction internal fixation is the ideal treatment for displaced intra-articular calcaneal fractures. Use of proper surgical timing and technique can give better results in majority of patients, avoiding many complications.

**Keywords:** Intra-articular calcaneal fractures, open reduction internal fixation, Maryland foot score

### Introduction

The calcaneus is the largest of the tarsal bones. Calcaneus is the most commonly fractured tarsal bone [1]. Fractures of the calcaneus are among the most therapeutic challenging fractures for the orthopaedic surgeon. Of calcaneal fractures, 90% occur in males between 21 and 45 years of age, thus has a major socioeconomic impact, given that patients with this injury typically sustain long periods of time off from work and away from normal recreation. Calcaneal fractures can be extra-articular (sparing the subtalar joint) or intra-articular (involving the subtalar joint). Intra-articular fractures account for approximately 75% of calcaneus fractures and have been associated with poor functional outcome [2-4]. These fractures occur due to axial load mechanism, such as a fall or a motor vehicle accident, and may be associated with other axial load injuries such as lumbar, pelvic and tibial plateau fractures. Goals common to all modes of treatment of calcaneal fractures are as follows: 1) Restoration of congruency of the posterior facet of subtalar joint, (2) restoration of the height of calcaneus (Bohler's angle), (3) reduction of the width of calcaneus, (4) decompression of the subfibular space available for the fibular tendons, (5) realignment of tuberosity into a valgus position, and (6) anatomic reduction of the calcaneocuboid joint if it is fractured.

**Correspondence**  
**Dr. Shanavas EK**  
Associate Professor in  
Orthopedics, Govt.TD Medical  
College, Alappuzha, Kerala,  
India

Open reduction and internal fixation of calcaneal fractures can have many wound related complications: Neurovascular injury, skin necrosis, infection. Wound infections are the most common complication of surgical treatment. They may be superficial or deep, with the incidence of superficial infection ranging from 10 % to 27%, and that of deep infection ranging from 1.3% to 2.5%. Acute neurologic injury can occur iatrogenically. Sural nerve is most at-risk for injury due to recent popularity of the lateral approach. The low incidence and lack of definitive consensus regarding the ideal management make it necessary to identify techniques which use lesser hardware and provide better functional outcomes in terms of shorter duration of treatment, better stability, early weight bearing, pain free joint and minimize incidence of secondary osteoarthritis.

### **Aim of the study**

To evaluate the functional outcome in patients following open reduction and internal fixation in displaced intra-articular calcaneal fractures conducted at Department of Orthopaedics, Government medical College Hospital, Thiruvananthapuram during the period of 2016-2017. Functional outcome is measured in terms of pain and function using Maryland Foot score.

### **Materials and methods**

It was a prospective study. Patients aged 20-60 years with closed, displaced intra-articular calcaneal fracture, who have undergone Open Reduction and Internal Fixation for it under Dept. of Orthopaedics, MCH, TVM during 2016-2017 period were included. Patients not having CT scan, open fractures, pathological fractures, ORIF after failed conservative management, fractures in patients with peripheral vascular disease, bleeding disorders and neuropathic joint and delayed surgery (more than 3 weeks after the injury) were excluded. All patients with displaced intra-articular calcaneal fractures reaching the Trivandrum Medical College casualty in the time period were treated by initial resuscitation and temporary stabilization of fracture by below knee slab and immediate elevation. The demographic profile, complete histories, vitals, neurovascular examination and local and systemic examinations were recorded in a proforma. X-ray ankle AP and Lateral, foot AP and oblique, Harris-heel axial view were taken. X-rays of opposite limb, spine and pelvis also taken. Bohler's angle was measured. Computerized Tomographic scan was taken. Sander's classification was used to classify the fracture patterns and compare the outcome. Later managed by definitive surgery, performed when the wrinkle sign is positive. All patients were given preoperative antibiotics. Surgery was performed within the first 2 weeks of injury to prevent difficulties with reduction as a result of early consolidation of the fracture. Complete muscle relaxation is preferred. If anaesthesia was not available, some cases were done under regional nerve block. Fluoroscopy was used intraoperatively to assess reduction. Open reduction and internal fixation is done in lateral position with or without tourniquet through lateral extensile exposure technique by Benirschke and Sangeorzan [15]. The peroneal tendons were left in their sheath. The sheath was stripped off the lateral calcaneal wall subperiosteally and held subluxed anterior to the fibula by the use of 2 K-wires. One in the fibula and one in the talus, and a third K-wire was inserted into cuboid. This no-touch technique not only retracted the peroneal tendons, but also excluded the need for manual retraction of the anterior skin flap. The calcaneofibular ligament was sharply

cut off the calcaneus and retracted anteriorly. The rectangular lateral wall was gently elevated to expose the fracture fragments. After hematoma removal, the depressed posterior facet fragment was rotated out from within the body of the calcaneus, which immediately decompressed the lateral wall. After identification of all remaining articular fracture fragments, preliminary reduction of the fragments was obtained using K-wires. If acceptable, 3.5 or 4mm lag screws were employed to maintain joint reduction. The body was reduced and a calcaneal ordinary or locking plate was used to maintain the body reduction and buttress the lateral wall. Sometimes iliac crest bone graft was used to fill the void left after reduction. Closure was performed over a drain and final films are taken. After surgery, limb elevation and IV antibiotics are continued, dressings done every 3<sup>rd</sup> day, drain removed after 48h of surgery. Patients were given a below knee POP slab after surgery which is maintained until wound healing and suture removal is usually done on the 14th day after surgery. The patients are then given below knee POP cast for six weeks. By the 6th postoperative week, active range of motion of the ankle and subtalar joint is instituted. No weight bearing is allowed till union is documented with x-rays.

### **Outcome assessment**

Clinical and Roentgenographic follow up (AP & Lateral) examination was performed at follow up at 1 and 6 months. CT scan was not performed due to financial reasons. Complications were also assessed during the follow up. Final outcome was assessed in our study by employing 'Maryland Foot Score' [11]. A maximum score of 100 points is possible in a patient with no pain, full range of sagittal and hind foot motion, no ankle or hind foot instability, good alignment, ability to walk more than six blocks, ability to ambulate on any walking surface, no discernible limp, no limitation of daily or recreational activities, and no assistive devices needed for ambulation. 55 points were assigned to function and 45 to pain. Clinically, it is not possible to determine isolated ankle joint range of motion; therefore, dorsiflexion motion and plantar flexion motion are measured with a goniometer and described as sagittal motion. Hind foot motion is expressed as a percentage of normal motion. A joint that can be passively dislocated or severely subluxated is graded as definitely unstable in these systems. Final outcome was measured by adding up the points received in each category. A score of 90-100 is taken as an excellent outcome, 75-89 as good, 50-74 as fair and a score less than 50 is considered a poor outcome or failure.

Radiological parameters considered were

Bohler's Angle

21-40 deg: Normal, 15-20 deg: Mild, 10-15 deg: Moderate, <10 deg: Severe

### **Observation and Results**

A total of 72 patients with displaced intra-articular calcaneal fractures, treated with open reduction and internal fixation were assessed in the study. Follow up of all patients were obtained till 6 months. Out of 72 patients, 65 were males and 7 were females. Age distribution ranged from 23 to 60, with mean age 39.7yrs. Of 72 patients, 70 had fall from height and 2 had Road Traffic Accident. Of 72 cases, 32 were right, 34 left and 3 bilateral.

Associated bony injuries included 22 spine fractures, 5 pelvis fractures, 5 opposite leg fracture and 1 had upper limb fracture

**Table 1:** Associated Bony Injuries

Asso Bony Injury	Frequency	Percent
Nil	39	54.2
Spine	22	30.6
Pelvis	5	6.9
Opposite leg	5	6.9
Upper limb	1	1.4
Total	72	100.0

Of 72 fractures, 26 were Sander’s type IV, 25 type II and 21 Type III fractures.

**Table 2:** Type of fracture

Type of fracture	Frequency	Percent
Sander's Type II	25	34.7
Sander's Type III	21	29.2
Sander's Type IV	26	36.1
Total	72	100.0

Average duration between injury and surgery was 6 days with a range between 1 and 14 days and a standard deviation of 2.3 days.

**Post-Operative bohler’s angle**

30 patients had Bohler’s angle more than 20deg and 42 had less than 20deg.

**Table 3:** Post-operative Bohler’s angle

Bohler’s Angle	Frequency	Percent
21-40	30	41.7
15-20	22	30.6
10-14	12	16.7
<10	8	11.1
Total	72	100.0

**Complications**

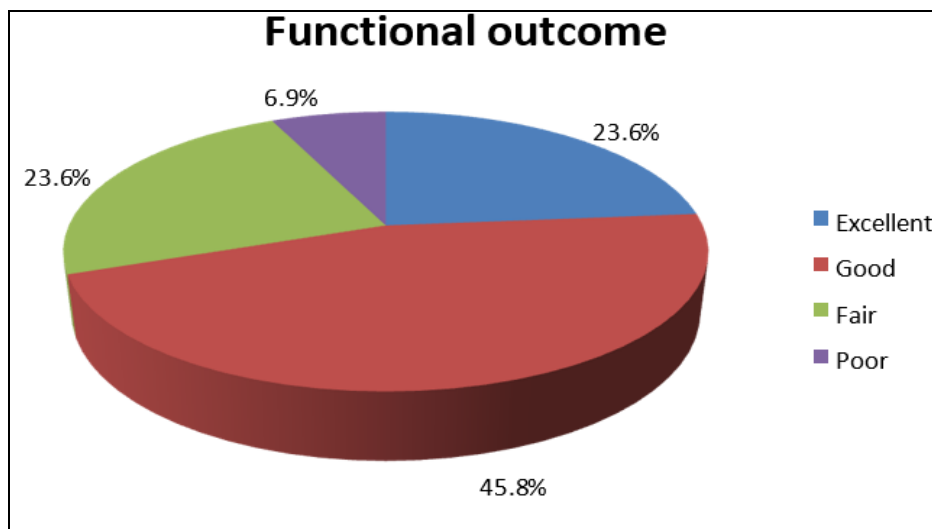
Of 72, 54 had no complications. 18 (25%) had complications (ankle and foot stiffness in 5, implant prominence in 4 and 3each had wound healing problems, infection and varus deformity)

**Table 4:** Complications

Complications	Frequency	Percent
Varus deformity	3	4.2
Infection	3	4.2
Wound healing problems	3	4.2
Implant prominence	4	5.6
Stiffness (ankle and foot)	5	6.9

**Maryland foot score and functional outcome**

The mean MFS was 77.4 ranging from 36 to 95 with a standard deviation of 13.6. 23.6% has excellent outcome, 45.8% had good, 23.6% had fair and 6.9% had poor outcomes.



**Chart 1:** Functional outcome and MFS

In the final analysis of Maryland foot score, 23.6% have excellent results, 45.8% got good, 23.6% fair and 6.9% got poor results.

**Type of fracture and post-operative bohler’s angle**

The proportion of patients having Bohler’s angle <20deg were more in Sander’s type IV as compared to types II and III.

**Table 5:** Type of fracture and post op Bohler’s angle

Type of fracture	Post Op Bohlersangle								Total	
	21-40		15-20		10-14		<10			
	N	%	N	%	N	%	N	%	N	%
Sander's Type II	16	53.3	7	31.8	0	0.0	2	25.0	25	34.7
Sander's Type III	10	33.3	8	36.4	2	16.7	1	12.5	21	29.2
Sander's Type IV	4	13.3	7	31.8	10	83.3	5	62.5	26	36.1
Total	30	100.0	22	100.0	12	100.0	8	100.0	72	100.0

$\chi^2=18.684$  df=9 p=0.028

**Functional outcome and post-operative bohler’s angle**

As Bohler’s angle increases, the Maryland foot score

increases. Excellent Maryland foot scores were obtained for normal Bohler’s angle with significant p value (<0).

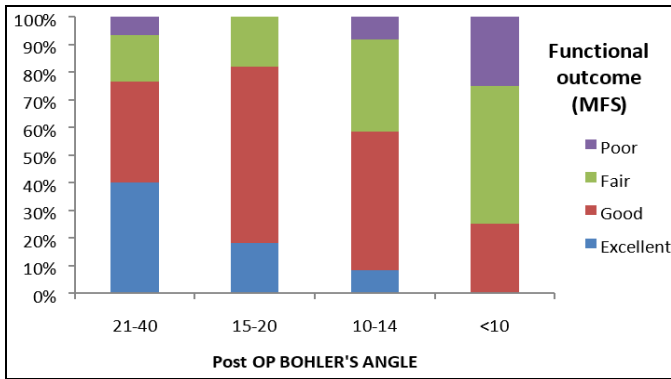
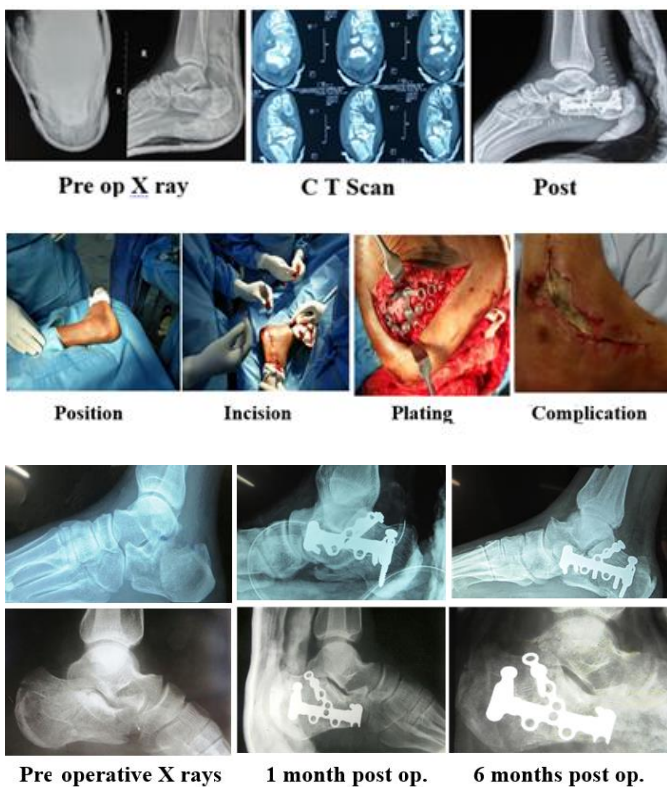


Chart 2: MFS and Post-op Bohler's angle

**Operative photographs & radiographs**



**Discussion**

Calcaneus is the most commonly fractured tarsal bone. The treatment of calcaneal fracture has, in recent years, been systematized by the use of careful classification systems and treatment algorithms. In the last few decades, operative treatment of displaced intra-articular calcaneus fracture has become a preferred treatment method with the advantage of less complication rates and better quality of life after the surgery [2, 3, 4, 22, 23, 24]. Brauer's cost-effectiveness analysis of surgery versus conservative treatment for intra-articular calcaneal fracture showed economical advantages of open reduction internal fixation in 2004 [3]. Open reduction and internal fixation can be done with ordinary or locking calcaneal plates, with or without bone grafting. There were total 72 cases in this study. Concerning age, sex, mechanism of injury and associated bony injuries, our study is comparable to the one in the literature. Analysis of the age distribution shows that this fracture affects most commonly the most productive age group. Nearly 61% of the cases fall in the age group 20-40, who are workers, which has a major socioeconomic impact, in terms of loss of productivity. In our study, there were 65 males (90.3%) and 7 females

(9.7%). It is comparable to the study by Farrell [21] who reported 90% males

In our study, 69 were unilateral (95.8%) and only 3 were bilateral fractures. This is comparable to the study by Farrell [21] who reported more than 80% unilateral fractures.

92.7% cases had fall from height as their mode of injury. Extreme trauma is needed to produce calcaneal fracture, so they are not infrequently associated with fractures of other bones. In our study, 22 (30.6%) had spinal injuries, 5 (6.9%) each had pelvic fractures and opposite limb fracture. 1 had upper limb fracture. Hence it is mandatory to examine patients in detail.

Mean time duration between injury and surgery in our study was 6.4 days. We waited till wrinkle sign was positive to prevent wound complications. We operated in the first 2 weeks of injury, because surgery after 3<sup>rd</sup> week is usually associated with high percentage of soft tissue complications, and open reduction internal fixation with more than 3 weeks delay is not recommended [2, 22, 23, 24].

**Final outcome of fractures**

In our study, we assessed the patients in follow up both radiologically and by functional evaluation using Maryland Foot Score. The mean score was 77.4. i.e., Good. 23.6% had excellent outcome, 45.8% had good, 23.6% had fair and 6.9% had poor outcomes. Our study was compared to other similar studies. The higher percentage of Sanders's type IV fracture in our study may have resulted in more fair and poor scores compared to other studies

Series	Functional Outcome (MFS)			
	Excellent	Good	Fair	Poor
Tornetta [25]	50	35	15	0
Gulabi <i>et al.</i> [26]	55	22.5	22.5	0
Sanders [14]	25	41.6	10.8	22.5
Present study	23.6	45.8	23.6	6.9

**Bohler's angle**

Bohler's tuber joint angle is commonly assessed when evaluating fractures of calcaneus. A severe calcaneal fracture will result in a significant decrease or loss of this angle. Janzen *et al.* [27], in 1992, reported that a loss of Bohler's angle was associated with a poor clinical outcome. Fernandes studied 33 patients and 38 intraarticular calcaneal fractures, with at least 2 year follow up, and found correlation with the Bohler's angle and functional outcome. However, more recently, Hutchinson and Huebner<sup>28</sup> have reported that Bohler's angle at follow-up did not correlate with the final clinical result. In our study, we found that the Maryland foot score has got an important correlation with post-operative Bohler's angle. Patients demonstrated a diminished functional outcome with a lower Bohler's angle. Higher energy injuries produce flatter Bohler's angles, with more bone and soft tissue injury. This results in a poor long-term outcome in severely displaced intra-articular calcaneal fractures.

**Complications**

The associated complications make the treatment of intraarticular calcaneal fractures a difficult entity in orthopaedics. The reluctance to treat displaced calcaneal fracture is mainly based on the fear of the orthopedician regarding the complication associated with ORIF. In our study, 25% had complications; of which, 6.9% had ankle and foot stiffness, 5.6% had implant prominence, 4.2% each had wound healing problems, infection and varus deformity.

## Conclusion

In conclusion, the fractures of the calcaneus often present as complex injuries. They assume significance because of the numerous complications and poor outcomes with significant long term quality of life issues. Distinct advances have been made in the understanding and management of displaced intra-articular calcaneal fractures. Computed tomographic scanning has been a revelation, allowing an understanding of the pathological anatomy of these fractures, and two-dimensional computed tomographic scans in both the coronal and the transverse plane are recommended. Classifications based on computed tomographic scanning (e.g. Sanders classification) are prognostic with respect to outcome. All calcaneal fractures are not treated equally. Displaced intra-articular fractures are treated by open reduction and internal fixation. In our study, the mean functional outcome after Open Reduction and Internal fixation, as evaluated by Maryland Foot Score, is 77.4 which is graded as Good. Even though we had higher percentage of Sander's type IV which is usually associated with poor outcome, the results after Open Reduction and Internal Fixation is good. The functional outcome has an important correlation with post-operative Bohler's angle.

In our study, better post-operative Bohler's angle resulted in better functional outcome, thus confirming the importance of better reduction of the fracture. 25% had complications which is comparable to previous studies. Thus Open Reduction and Internal Fixation, with proper timing, aseptic precautions and surgical technique, should be encouraged in displaced intra-articular calcaneus fractures.

## Reference

- Crosby LA, Fitzgibbons T. Computerized tomography scanning of acute intraarticular fractures of the calcaneus. A new classification system. *J Bone Joint Surg Am.* 1990; 72:852-9.
- Zwipp H, Rammelt S, Barthell S. Fracture of the calcaneus. *Unfallchirurg.* 2005; 108:737-748.
- Brauer CA, Manns BJ, Ko M, Donaldson C, Buckley R. An economic evaluation of operative compared with nonoperative management of displaced intra-articular calcaneal fractures. *J Bone Joint Surg.* 2005; 87:2471-2479.
- Lim EA, Leung JP. Complications of intra-articular calcaneal fracture. *CORR.* 2005; 391:7-16.
- Stephenson JR. Displaced fractures of the os calcis involving the subtalar joint: the key role of superomedial fragment. *Foot Ankle.* 1983; 4:91-101.
- Sanders R. Intra-articular fractures of calcaneus: present state of the art. *J Orthop Trauma.* 1992; 6:252-265.
- Leung KS, Yuen KM, Chan WS. Operative treatment of displaced intra-articular fracture of calcaneum. Medium-term results. *J Bone Joint Surg Br.* 1993; 75:196201. *ClinIrthopRelat Res.* 1963; 30:111-5.
- Gallie WE. Subtalar arthrodesis in fractures of the os calcis. *Bone and Joint surg J.* 1943; 25:731-736.
- Palmer I. The mechanism and treatment of fractures of the calcaneus-Open reduction with the use of cancellous grafts. *Bone and Joint Surg J.* 1948; 30:2-8.
- Essex-Lopresti P. The mechanism, reduction technique and results in fracture of the os calcis. *British Surg J.* 1952; 39:395-419.
- Crosby LA, Fitzgibbons TC. Intraarticular calcaneal fractures. Results of closed treatment. *Clin. Orthop. J.* 1993; 290:47-54
- Sanders R, Fortin P, DiPasquale T, Walling A, *et al.* Operative treatment in 120 displaced intra-articular calcaneal fractures- Results using a prognostic computed tomographic scan classification. *ClinOrthop J.* 1993; 290:87-95.
- Letournel E. Open treatment of acute calcaneal fractures. *Clinical Orthop J.* 1993; 290:60-67.
- Sanders R. Displaced intra-articular fractures of the calcaneus. *J Bone Joint Surg Am.* 2000; 82:225-250.
- Sangeorzan BJ, SK Benirschke, JB Carr, *et al.* Surgical management of fractures of the os calcis. *Instr Course Lect.* 1995; 44:359-70.
- Giardano CP, Koval KJ. Treatment of fracture blisters-A prospective study of 53 cases. *J Orthop Trauma.* 1995; 9:171-176.
- Kitaoka H, Schap E, Chao EY, *et al.* Displaced intra-articular fractures of the calcaneus treated nonoperatively. *J Bone Joint Surg.* 1994; 76:1531-1540.
- Folk J, Starr A, *et al.* Early wound complications of operative treatment of calcaneal fractures: Analysis of 190 fractures. *J Orthop Trauma.* 1999; 13:369372.
- Fakhouri AJ, Manoli A. Acute foot compartment syndromes. *J Orthop Trauma.* 1992; 6:223-8.
- Stephens HM, Sanders R. Calcaneal malunions- results of a prognostic computed tomography classification system. *Foot Ankle Int.* 1996; 17:395-401.
- O'Farell DA, O'Byrne JM, Mc Cabe JP, Stephens MM. Fractures of the os calcis: Improved results with internal fixation. *Injury.* 1993; 24:263-5.
- Zwipp H, Rammelt S, Barthel S. Calcaneal fractures-open reduction and internal fixation (ORIF). *Injury.* 2004; 35:SB46-SB54.
- Hart AJ, Eastwood DM. Displaced intra-articular fractures of the calcaneus: what is new? *Trauma.* 2003; 5:9-21.
- Benirschke SK, Kramer PA. Wound healing complications in closed and open calcaneal fractures. *J Orthop Trauma.* 2004; 18:1-6.
- Tornetta P. 3<sup>rd</sup>. The Essex-Lopresti reduction for calcaneal fractures revisited. *J Orthop Trauma.* 1998; 12:469-73.
- Gulabi D, Sari F, Sen C, Avci CC, Saglam F, Erdem M, *et al.* Mid-term results of calcaneal plating for displaced intra-articular calcaneus fractures. *Ulus Trauma Acil Cerrahi Derg.* 2013; 19:145-51.
- Janzen DL, *et al.* Intraarticular fractures of the calcaneus value of CT findings in determining prognosis. *AJR Am J Roentgenol.* 1992; 158:1271-1274.
- Hutchinson F, Huebner MK. Treatment of os calcis fractures by open reduction and internal fixation. *Foot Ankle Int.* 1994; 15:225-232.