



International Journal of Orthopaedics Sciences

ISSN: 2395-1958

IJOS 2018; 4(3): 242-245

© 2018 IJOS

www.orthopaper.com

Received: 11-05-2018

Accepted: 12-06-2018

Raghulraj Sundaramoorthy

M.S Ortho- Postgraduate
Student, Department of
Orthopaedics, Rajah Muthiah
Medical College and Hospital,
Annamalai University,
Tamil Nadu, India

Senthilnathan Arumugam

Professor Department of
Orthopaedics, Rajah Muthiah
Medical College and Hospital,
Annamalai University,
Tamil Nadu, India

Prabhakar Ramabadrnan

Lecturer, Department of
Orthopaedics, Rajah Muthiah
Medical College and Hospital,
Annamalai University,
Tamil Nadu, India

A prospective study of functional outcome of posteromedial plating in the management of complex tibial plateau fractures

Raghulraj Sundaramoorthy, Senthilnathan Arumugam and Prabhakar Ramabadrnan

DOI: <https://doi.org/10.22271/ortho.2018.v4.i3e.41>

Abstract

Tibial plateau fractures have a complicated intra articular fracture pattern, representing approximately 1.2% of all fractures. The occurrence of posteromedial fragment is relatively common in high energy tibial plateau fractures

Aims and Objectives: To study the role of posteromedial plating in management of complex tibial plateau fractures with a posteromedial fragment. Materials and methods: 26 cases above 25 years of age, from the patient admitted to Rajah Muthiah Medical College and Hospital, Annamalai University, Chidambaram with posteromedial fragment in tibial plateau fractures that were operated between May 2016 to May 2018 were undertaken for the study. Reduction can be maintained with a Kirchner wire and a pointed reduction clamp. The plate is placed directly over the area of maximal displacement at the apex of the fracture. Results: Of the 26 patients with type IV, V and VI Schatzker's tibial plateau fractures from x ray and CT scan of knee joint, 24 had pre contoured posteromedial plate and 2 patients had recon plate where the fragment was comparatively small and comminuted. We analysed patients with Rasmussen scoring postoperatively. In our analysis among 26 patients, functional score were excellent in 20, Good in 3, Fair in two and poor in one patient. There was one patient with grade I compound injury who had developed infection that later resolved after wound wash and resuturing on the 5th postoperative day with judicious use of antibiotics. One patient had collapse due to premature weight bearing. Two patients had transient paraesthesia of the saphenous nerve; both resolved completely.

Keywords: Posteromedial plating, Rasmussen's criteria

Introduction

Tibial plateau fractures have a complicated intra articular fracture pattern, representing approximately 1.2% of all fractures [1]. Fracture reduction can be a challenge to experienced hands and the soft tissue conditions are intolerant of careless dissection. Fractures which involve the articular cartilage of the proximal tibia often require open reduction and internal fixation to restore the joint surfaces and the alignment of the limb. The advent of computed tomography and its three dimensional reformation (3D) has allowed for an accurate assessment of this fracture pattern. Luo *et al.* described the morphology of this fracture based on the CT scan [2-4]. These studies help to understand the geometry of this fracture pattern. The Three-Column Classification demonstrates a higher interobserver reliability and can be used as a supplement to the conventional Schatzker Classification, especially in the complex and posterior comminuted tibial plateau fractures. Furthermore, the Three-Column Classification is clinically relevant and, to some degree, can instruct the surgeon in preoperative planning [5, 6]. The occurrence of posteromedial fragment is relatively common in high energy tibial plateau fractures and that the use of a posteromedial approach with direct fracture visualization, anatomic reduction and absolute stability appears to result in satisfactory outcomes.

Aims and objectives: All displaced intraarticular fractures should be surgically stabilized to restore joint congruity and prevent late subluxation and early arthritis. The aim is to study the role of posteromedial plating in management of complex tibial plateau fractures with a posteromedial fragment.

Correspondence

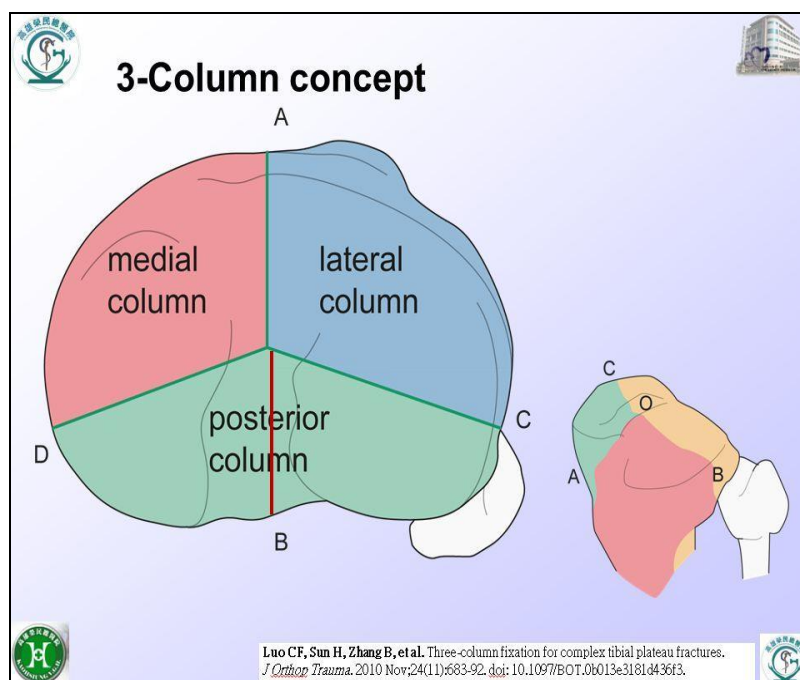
Raghulraj Sundaramoorthy

M.S Ortho- Postgraduate
Student, Department of
Orthopaedics, Rajah Muthiah
Medical College and Hospital,
Annamalai University,
Tamil Nadu, India

Materials and methods

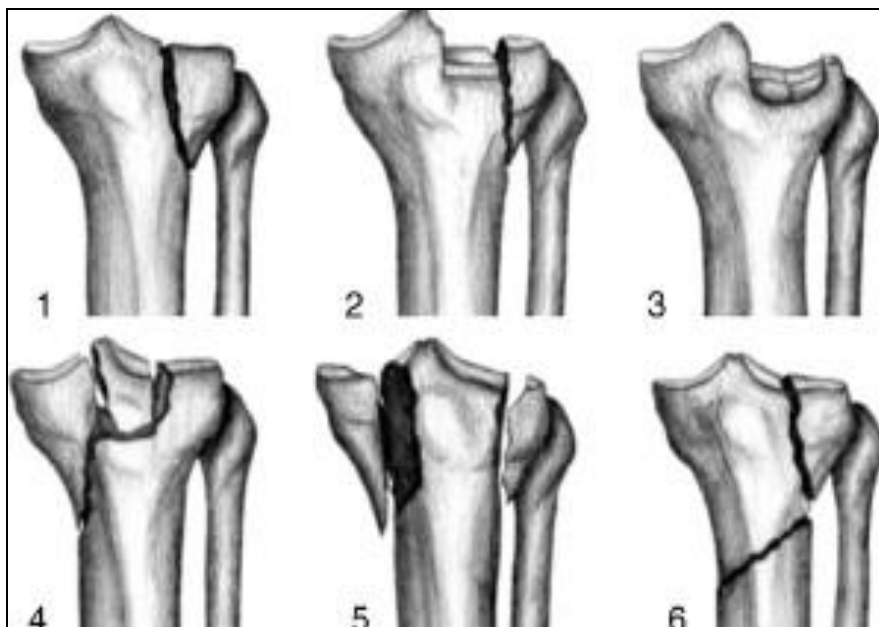
26 cases above 25 years of age, from the patient admitted to Rajah Muthaiah Medical College and Hospital, Annamalai University, Chidambaram with posteromedial fragment in tibial plateau fractures that were operated between May 2016 to May 2018 were undertaken for the study. All patients were men with mean age of 32 years (25 to 63 years). No patient had any preoperative neurovascular damage. All patients had limb elevation and temporary splinting with above knee slabs. Ice fomentation were given when there were diffuse swelling at the fracture site. Preoperative evaluation included plain radiography, anteroposterior and lateral views with CT scans of the affected knee. The fractures were classified according to Schatzker Classification [7] with X rays and the Three-Column Classification using CT scans. They were operated with plate osteosynthesis and the results were analysed using Rassmussen's knee score [9]. Modified Lobenhoffer approach to gain access to the posteromedial plateau was used. With the patient in the supine position, with sand bag below the opposite pelvis when necessary as part of a combined medial and lateral reconstruction for a bicondylar fracture. The skin

incision is made along the medial head of the gastrocnemius muscle extending from the medial femoral epicondyle proximally to the posterior border of the tibia six to eight centimeters beyond the tip of the posteromedial fragment distally. The deep interval is between the gastrocnemius muscle which is retracted posteriorly and the pes anserinus, which is retracted anteriorly. When the fragment is large, and noncomminuted, the reduction can be achieved at the level of the metaphysis and verified at the joint line via fluoroscopy or by direct observation. The reduction maneuver is traction on the tibia and extension of the knee. Reduction can be maintained with a Kirchner wire and a pointed reduction clamp. An antiglide buttress plate consisting of a small fragment third tubular or reconstruction plate is sufficient for smaller fragments and site-specific pre-contoured posteromedial plate when optimally positioned is well suited to resist deforming forces. The plate is placed directly over the area of maximal displacement at the apex of the fracture. Fracture pattern requiring lateral column fixation, 16 among 26 cases in our study had additional cannulated cancellous screws with or without washer, plate osteosynthesis laterally.



Clinical features					
Rating	Pain	Walking capacity	ROM	Clinical signs	Stability
Excellent	No	Normal	Normal	No	Normal
Good	Minimal	Walking outdoor for at least 1 h	75% of normal	+	Minimal
Fair	Occasional ache	Walking outdoor for 15 min	>50% of normal	Swelling, ++	Instability in flexion
Poor	Pain at rest	Walking indoor only	50% of normal or less	+++	Instability in flexion as well as in extension

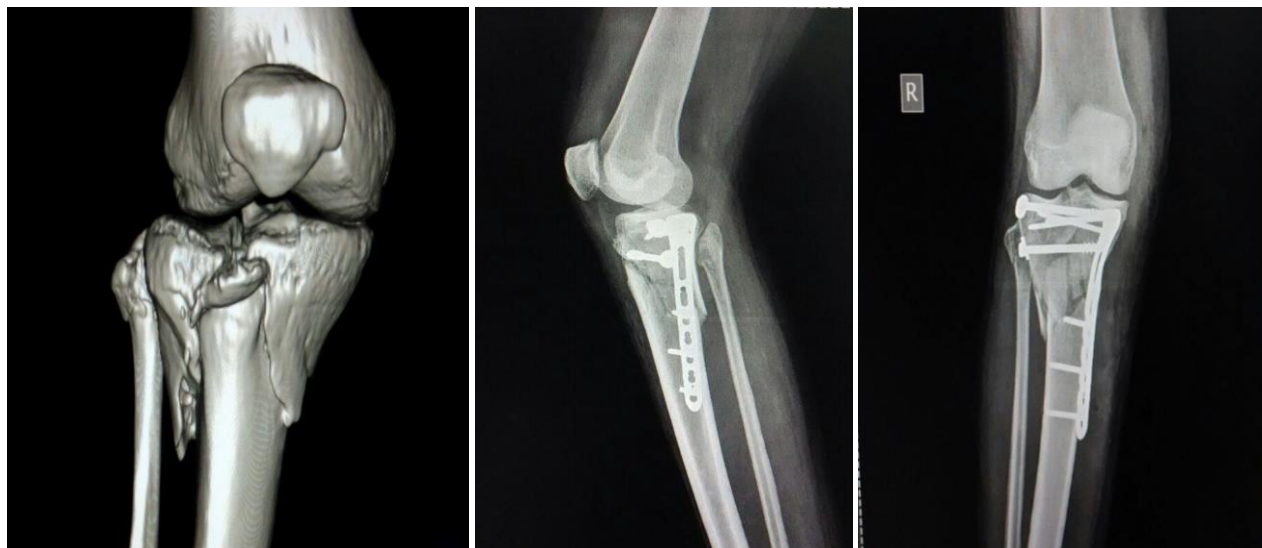ROM: Range of motion



Results

Of 26 patients, all were followed for at least a minimum period of 6 months to maximum period of 22 months. Of this 26 patients with type IV, V and VI Schatzker's tibial plateau fractures from x ray and CT scan of knee joint, 24 had pre contoured posteromedial plate and 2 patients had recon plate where the fragment was comparatively small and comminuted. Post-operative protocol was based on bony union radiologically where full weight bearing was advised only after a minimum of 12 weeks. We analysed patients with Rasmussen scoring postoperatively. Rasmussen scoring is

based on functional criteria. In our analysis among 26 patients, functional score were excellent in 20, Good in 3, Fair in two and poor in one patient. There was one patient with grade 1 compound injury who had developed infection that later resolved after wound wash and resuturing on the 5th postoperative day with judicious use of antibiotics. One patient had collapse due to premature weight bearing. Two patients had transient paraesthesia of the saphenous nerve; both resolved completely.



Discussion

The proximal tibial articular surface is one of the critical load bearing areas of the human body. Fracture of this area can occur due to a combination of axial loading and valgus or varus applied forces. Stability of the joint, alignment of the lower limb and motion of the knee joint are severely affected as a result of tibial plateau fracture. The more energy applied to the limb, more complex is the fracture.

In general, Schatzker types IV-VI fractures were categorized as high-energy related, although it is believed this category system could not include all injury types now. Luo's CT based Three-Column Classification is clinically relevant and can instruct the surgeon in preoperative planning. Knee

instability will result if these injuries are left untreated. The optimized treatment protocol should include assessing and reconstructing the stability apparatus in primary fixation of fractures. A Posteromedial fragment in CT scan warrants fixation.

Georgiadis *et al.* used combined anterior and posterior approaches for the reduction and fixation of complex tibial plateau fractures involving a large split posteromedial fragment; as a result, all fractures united in good position with no significant complications and all patients had a good range of knee motion. Moore, Patzakis and Harvey (1987) reported that nine of 11 patients treated by medial and lateral plating through an anterior incision became infected or had wound

problems. Mast, Jakob and Ganz (1989) have described the substitution of a medial plate by temporary external fixation. And Carlson treated five patients with posterior bicondylar tibial plateau fractures by direct fracture exposure and fixation through posteromedial and posterolateral incisions. A posterior plate is covered by a large muscular envelope and is not palpable unlike direct medial plating

Conclusion

Posteromedial plating plays an integral role in the functional outcome of tibial plateau fractures with posteromedial fragment.

References

1. Ariffin HM, Mahdi NM, Rhani SA, Baharudin A, Shukur MH. Modified hybrid fixator for high-energy Schatzker V and VI tibial plateau fractures. *Strategies Trauma Limb Reconstr* 2011; 6:21-26.
2. Higgins TF, Kemper D, Klatt J. Incidence and morphology of the posteromedial fragment in bicondylar tibial plateau fractures. *J Orthop Trauma*. 2009; 23:45-51
3. Barei DP, O'Mara TJ, Taitzman LA. Frequency and fracture morphology of the posteromedial fragment in bicondylar tibial plateau fracture patterns. *J Orthop Trauma*. 2008; 22:176-182.
4. Markhardt BK, Gross JM, Monu JU. Schatzker classification of tibial plateau fractures: use of CT and MR imaging improves assessment. *Radiographics*. 2009; 29:585-597.
5. Yi Zhu, Guang Yang, Cong-Feng Luo, Wade R. Smith, Cheng-Fang Hu, Hong Gao, Biao Zhong, Bing-Fang Zeng. *J Trauma Acute Care Surg*. 2012; 73(3):731-737.
6. Luo CF, Sun H, Zhang B, Zeng BF. *J Orthop Trauma*. 2010; 24(11):683-92
7. Schatzker J, McBroom R, Bruce D. The tibial plateau fracture. The Toronto experience 1968 – 1975. *Clin Orthop Relat Res* 1979, 94-104.
8. Fischer-Rasmussen T, Jensen PE. Proprioceptive sensitivity and performance in anterior cruciate ligament-deficient knee joints. *Scandinavian Journal of Medicine & Science in Sports*. 2000; 10:85-89
9. Rasmussen PS. Tibial condylar fractures. Impairment of knee joint stability as an indication for surgical treatment. *J Bone Joint Surg Am*. 1973; 55A:1331-1350.