



International Journal of Orthopaedics Sciences

ISSN: 2395-1958

IJOS 2018; 4(3): 169-174

© 2018 IJOS

www.orthopaper.com

Received: 01-05-2018

Accepted: 02-06-2018

Vinod Nair

Department of Orthopaedics,
Dr D.Y. Patil Hospital, Pimpri,
Pune, Maharashtra, India

Clevio Desouza

Department of Orthopaedics,
Dr D.Y. Patil Hospital, Pimpri,
Pune, Maharashtra, India

Amit Chaudhary

Department of Orthopaedics,
Dr D.Y. Patil Hospital, Pimpri,
Pune, Maharashtra, India

Harshal Hurkat

Department of Orthopaedics,
Dr D.Y. Patil Hospital, Pimpri,
Pune, Maharashtra, India

Shiju George

Department of Orthopaedics,
Dr D.Y. Patil Hospital, Pimpri,
Pune, Maharashtra, India

Management of knee osteoarthritis: Knee lavage combined with intra articular injections of methyl prednisolone

Vinod Nair, Clevio Desouza, Amit Chaudhary, Harshal Hurkat and Shiju George

DOI: <https://doi.org/10.22271/ortho.2018.v4.i3d.31>

Abstract

Introduction: Osteoarthritis is a degenerative joint disease. It is a slowly progressive disease that affects individuals from the fourth decade and continues to progress at a variable rate. Knee is the most common joint affected in this condition. Osteoarthritis of the knee is a common problem in India among the population above 40 years of age. Knee Lavage with intra articular injections of methyl Prednisolone is a rapid and cost effective method which decreases the symptoms of osteoarthritis for a variable period and results in better functional outcome.

Materials and Methods: This is a prospective observational study conducted on 100 knees in 75 patients suffering from Osteoarthritis treated from July 1 2016 till Dec 31 2016, in the Department Of Orthopaedics, Dr D.Y. Patil Hospital, Pimpri, Pune. All the baseline characteristics of the patients, like demographics, symptoms, Kellegren and Lawrence criteria and functional outcome were recorded. The patients were treated at our hospital with Knee Lavage combined with intra articular injections of methyl prednisolone and followed up for a minimum period of six months. The follow-up information included range of motion, scoring, patient satisfaction and overall outcome of the procedure in terms of patient acceptance. The data was analyzed to determine the functional outcome at six months.

Results: There was satisfaction in terms of symptoms of pain and range of movements of the knee. 37% patients showed excellent prognosis, good and fair prognosis was showed by 30% of the patients while only 3% people showed poor prognosis after a follow up of six months duration.

Conclusion: Knee Lavage with intra articular injections of methyl prednisolone was not only associated with excellent functional outcome and short term recovery in terms of patient satisfaction and range of movements of the knee with decrease in pain six months post-procedure but also was found to be cost effective.

Keywords: Knee, osteoarthritis, joint lavage, irrigation, methyl prednisolone

Introduction

Osteoarthritis, also known as Osteoarthrosis, is a degenerative joint disease of heterogeneous group of disorders that results in articular cartilage degeneration [1]. Although the suffix 'itis' implies that osteoarthritis is an inflammatory disorder and some evidence of synovitis is often present, inflammation does not appear to be a major component of the disorder in most patients. It is not a single disease entity but a final common end result of various patterns of joint failure. Unlike the joint destruction caused by synovial inflammation, osteoarthritis consists of a retrogressive sequence of cell and matrix changes that result in loss of articular cartilage structure and function accompanied by cartilage repair and bone remodelling actions [2]. Osteoarthritis of major joints affects the quality of life adversely leading to lot of suffering and reduces the work output as well as activity of the patient. Osteoarthritis of the knee joint also called degenerative arthritis is an old companion of mankind. It is slowly progressive disease usually starting in later part of fourth decade and then continues to progress at variable rate [3]. Its occurrence in old age suggests it to be a feature of ageing. Knee joint is the most commonly affected joint and osteoarthritis is the most common chronic human joint disease [4]. Age is the most important risk factors for osteoarthritis. With advancing age there is not only an increase in incidence and prevalence of osteoarthritis but, the severity of the disease also

Correspondence

Vinod Nair

Department Of Orthopaedics,
Dr D.Y. Patil Hospital, Pimpri,
Pune, Maharashtra, India

increases [5]. In India and world over, due to better availability of health care facilities the life expectancy has improved.

Bauer and Bennett (1936) believed that degenerative arthritis is the result of the wear and tear of increasing age and repeated trauma which may be caused by variety of ways and is not the result of the inflammatory process. Normal synovial joint may be regarded as being in a state of equilibrium in between mechanical properties of articular cartilage and the mechanical stresses imposed upon this tissue. Articular cartilage provides a resilient yet durable covering for the articulating bones of synovial joints. It transmits repetitive loads and together with synovial fluid, reduces joint friction to minimal levels [6].

Materials and methods

The current study is a prospective observational study conducted at Dr D.Y. Patil Hospital, Pimpri, Pune for duration of six months from July 1, 2016 to December 31, 2016. A total of 75 patients were included in the study, the inclusion criteria being all adult patients (age>40years) presenting with osteoarthritis of Knee diagnosed on the basis of clinical symptoms like pain, knee effusion, medial joint line tenderness, joint crepitus and morning stiffness while those patients not having any of these symptoms were excluded. Data was collected using a structured proforma. Patients were recruited on presentation to the orthopaedic consulting clinics according to the selection criteria. The purpose, procedure, risks and benefits of the study were explained to the patients and a formal written consent was taken. Patients were followed up for at least six months after the procedure and on final follow-up patients underwent post procedure assessment of range of motion of the knee using a goniometer measuring all the ranges. Patient satisfaction with the procedure was assessed through direct questioning and a satisfactory or very satisfactory response was considered acceptable in the final follow-up. Results were presented according to improvement of knee pain as presented on the visual analogue scale at follow up of 1 month, 3 months, and six months. All patients underwent knee lavage in the operation theatre after a formal written consent and by a single orthopaedic surgeon.

Procedure: In the operation theatre after thoroughly cleaning the knee, the area was painted with povidone iodine solution and draped with sterile sheets. A point was marked, a finger breadth above tibial plateau, outside the lateral border of patellar tendon while the knee was flexed at 45°. 10 ml, 2% lignocaine was injected through this point into the knee joint and in subcutaneous tissue. A stab incision was given with surgical blade No. 11 at this point with the knife handle making an angle of 45° with the leg and to the ground. The blade was pushed forwards, upward and medially. Three way arthroscopic cannula along with blunt trocar was pushed through this opening. During this procedure knee was brought to full extension. After stabilizing the patella with palm of other hand, trocar and cannula assembly was swiped side ways few times to break the intra-articular adhesions and smoothen out the under surface of patella. The trocar was removed and effusion if any was drained out. The tip of I.V. set was attached to side opening of cannula and lock was opened to run the fluid into the joint. The main proximal opening of cannula was blocked with the thumb so as to fill the joint. Once the joint was full of fluid as seen with bloating of supra patellar area, the side lock was closed and joint was emptied with a gush by pressing and squeezing the supra

patellar area with one hand and releasing the thumb block of arthroscopic cannula at the same time. This filling and emptying of the joint was repeated till 3000 ml of ringer lactate is used. Now injection Methyl prednisolone 80 mg was mixed with 5 ml 2% of lignocaine and spinal needle was attached to the syringe. Through proximal main opening of the cannula, the needle was pushed inside and material injected into joint with the side lock closed. Immediately the cannula was withdrawn and knee joint is flexed few times for good distribution of drug into the joint. Antiseptic dressing and crepe bandage was given and patient walked out of operation theatre. Apart from this procedure, medications in the form of antispasmodics, painkillers and calcium supplementation was given to the patient. This procedure was followed by Physiotherapy to the patient for static quads, static hamstrings, ankle toe movements and knee range of motion.

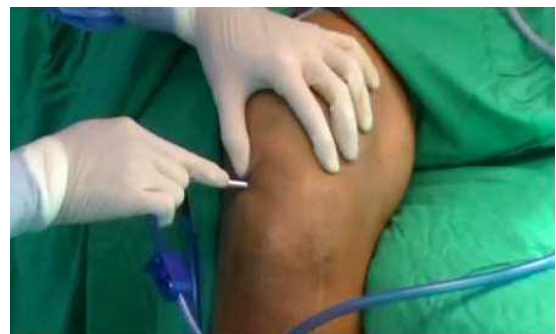

Fig 1: Arthroscopic Knee Lavage being Performed.

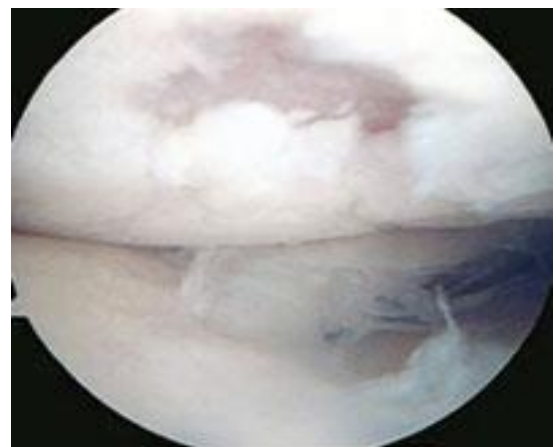


Fig 2: Arthroscopic Picture of a Osteoarthritic Knee

Evaluation of the Patients

On admission, X-rays for AP view of both the knees in standing position were taken and osteoarthritis was graded as per Kellgren and Lawrence grading (1957). Before surgery and at every follow up patient's pain perception was evaluated as per his perception of pain as per Visual Analogue Scale (VAS) where the patient marked a dot on a line 100 mm long. Pain score was presumed to be at 100 mm mark at the start of treatment.

Evaluation of results

Depending upon improvement in pain score as per Visual Analogue Scale the results were graded as follows:

1. Excellent: 90-100% improvement
2. Good: 70-89% improvement
3. Fair: 40-69% improvement
4. Poor: <40% improvement

Observations

We enrolled patients of osteoarthritis of knee joint (Grades 1 to 3 per the Kellgren and Lawrence radiological grading) coming to the out-patient department of Orthopaedics of Dr D.Y. Patil Hospital, Pimpri, Pune for the purpose of the study. 100 knees in 75 patients were subject to knee lavage with 3 liters of ringer lactate solution under anaesthesia

supplemented with intra articular injection of methyl prednisolone of 80 mg. All the patients turned up regularly for follow up at different intervals and observations were recorded as per Performa attached.

Age and sex distribution

Table 1

Age groups	No. of Patients				Total no. of patients
	One knee		Both knees		
	Female	Male	Female	Male	
40-49 years	5	6	4	-	15
50-59 years	10	9	12	3	34
60 years and above	16	4	4	2	26
Total	31	19	20	5	75

Total no. of female patients 51(68%)
 Total no. of knees in female patients 71(71%).
 Total no. of knees in male patients 29(29%)
 Total no. of male patients: 24(32%)

Total no. of patients: 75
 Average age of patient: 58 years

Duration of knee pain

Table 2

Duration of knee pain	Number of knees in patients	Percentage
<1 year	30	30%
1-2 year	25	25%
2-3 year	18	18%
3-4 year	15	15%
>4 year	12	12%

Radiological grading of osteoarthritis knee

Table 3

Radiological grades	Number of knees	Percentage
Grade 0	None	-
Grade 1	5	5%
Grade 2	10	10%
Grade 3	55	55%
Grade 4	30	30%

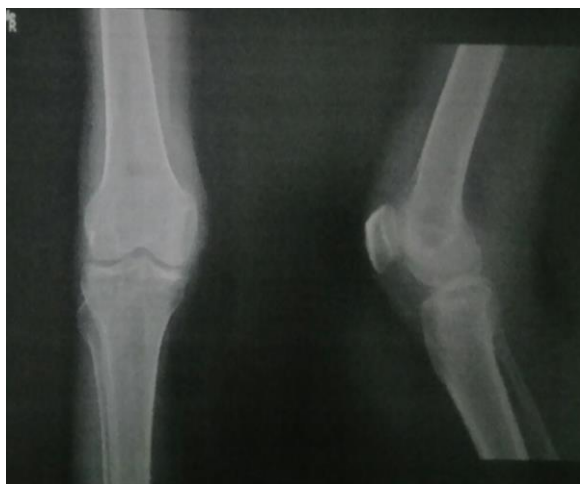

Fig 2: Pre procedure X-Ray

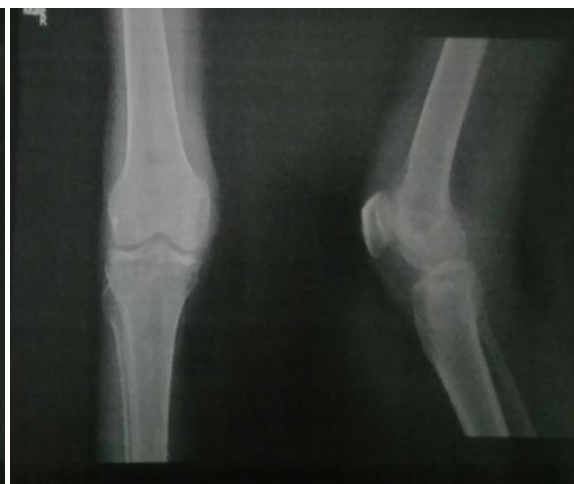

Fig 3: Post Procedure X-ray

Results

The results were graded according to improvement of knee

pain as recorded on the visual analogue scale at one, three and six months.

Results at 1 month follow up**Table 4**

Age groups	Number of knees	Kellgren and Lawrence grades → No. of knees
Excellent	37(37%)	Grade 1 → 4(10.8%)
		Grade 2 → 7(18.9%)
		Grade 3 → 26(70.2%)
		Grade 4 → 0
Good	37(37%)	Grade 1 → 1(2%)
		Grade 2 → 3(8%)
		Grade 3 → 20(54%)
		Grade 4 → 13(35%)
Fair	23(23%)	Grade 1 → 0
		Grade 2 → 0
		Grade 3 → 9(39.9%)
		Grade 4 → 14(59.1%)
Poor	3(3%)	Grade 1 → 0
		Grade 2 → 0
		Grade 3 → 0
		Grade 4 → 3(100%)
Total	100	100

Results at 3 month follow up**Table 5**

Age groups	Number of knees	Kellgren and Lawrence grades → No. of knees
Excellent	40(40%)	Grade 1 → 3(7%)
		Grade 2 → 7(17.5%)
		Grade 3 → 30(75%)
		Grade 4 → 0
Good	30(30%)	Grade 1 → 2(6%)
		Grade 2 → 3(10%)
		Grade 3 → 20(66%)
		Grade 4 → 5(16.6%)
Fair	27(27%)	Grade 1 → 0
		Grade 2 → 0
		Grade 3 → 5(18.6%)
		Grade 4 → 22(81.4%)
Poor	3(3%)	Grade 1 → 0
		Grade 2 → 0
		Grade 3 → 0
		Grade 4 → 3(100%)
Total	100	100

Results at 6 months follow-up**Table 6**

Age groups	Number of knees	Kellgren and Lawrence grades → No. of knees
Excellent	37(37%)	Grade 1 → 3(7%)
		Grade 2 → 6(16.2%)
		Grade 3 → 28(75.6%)
		Grade 4 → 0
Good	30(30%)	Grade 1 → 2(6%)
		Grade 2 → 4(13.3%)
		Grade 3 → 20(66.6%)
		Grade 4 → 4(13.3%)
Fair	30(30%)	Grade 1 → 0
		Grade 2 → 0
		Grade 3 → 7(23.3%)
		Grade 4 → 23(77.7%)
Poor	3(3%)	Grade 1 → 0
		Grade 2 → 0
		Grade 3 → 0
		Grade 4 → 3(100%)
Total	100	100

Discussion

Osteoarthritis of knee is a degenerative joint disorder and its prevalence has increased in past three to four decades because of increase in life expectancy both in males and females. With increase in age, there is corresponding increase in geriatric problem like osteoarthritis of knee that too of moderate to severe grade especially in our country where knee joint is the most commonly affected joint because of social habits of squatting and sitting cross-legged [7]. In our OPD, patients of osteoarthritis of knee constitute more than 50% of total OPD attendance daily. Since total knee joint replacement is not socially acceptable because of immense cost of implant and squatting habits of Indian patients. Arthroscopic knee lavage has a crucial role in management of osteoarthritis of knee in Indian patients [8, 9]. Total knee replacement is also not advisable in middle aged patient because of need of revision surgery later in life. The role of arthroscopy has increased in past three decades to fill the gap between conservative treatment and total knee replacement. Candidate for arthroscopic lavage usually are patients with osteoarthritis of knee who continue to be symptomatic after trial of non operative treatment which includes-Physical therapy, NSAID's and occasionally corticosteroids [10]. Among the arthroscopic procedures knee lavage with intra articular injection of methyl prednisolone has the best results [11]. Arthroscopic debridement includes limited synovectomy, removal of loose bodies, shaving of articular cartilage, removal of osteophytes, damaged meniscus etc [12]. However the ones which could not be corrected include articular cartilage that has worn away due to lack of hyaline cartilage regeneration capacity, articular surface cannot be restored to their original mirror like appearance; and the torn or degenerated meniscal tissue cannot be replaced with normal meniscal tissue [13, 14]. Although the pain relief after arthroscopic knee lavage lasts for a variable period of time, it is only a temporary measure and not a permanent cure. It is an economical, short duration procedure, can be repeated easily without blood loss or scarring of skin. The aim of this study was to achieve the objective of evaluating the results of arthroscopic knee lavage supplemented with intra articular Methyl prednisolone 80 mg in osteoarthritis of knee joint with, reference to relief of pain. A total of 75 patients (100 knees) were included in the study. The age of patients varied from a minimum of 40 years to a maximum of seventy five years with an average of 58 years. In our series and most of the studies in literature the average age lies between 40 and 70 years. It is also clear from the study that articular cartilage is strong enough to sustain the cyclic loading before the age of 40 years. The minimal cartilage changes that occur are not sufficient enough to cause any clinical problem [15, 16]. The patients showing no improvement have range from 50-75 years with an average of 59.2 yrs. The duration of knee pain in our study was >1 year in all patients and half of them had pain of >3 years. The average duration was 2.57 years. Lack of knowledge about the available treatment and poverty are the main reasons for the patient's long sufferings in India before landing up for proper treatment. In our study the patients included had osteoarthritis of radiological grades one to four as per Kellgren and Lawrence grading (1957). The main outcome measure recorded in our study was knee pain and was recorded on the visual analogue scale. The results were evaluated at one, three and six month follow up. At one month the results were excellent in 37% and good in 37% knees (Of the 37 knees showing excellent results 10.8% had radiological grade 1 osteoarthritis, 89% had grade 2 and 72%

had grade 3 osteoarthritis and of the 37 knees showing good results. 8% had grade 2, 54% had grade 3 and 35% had grade 4 osteoarthritis. At three months results were excellent in 40% and good in 30% (of the 40 knees showing excellent results 7% had grade 1, 17.5% had grade 2 and 75% had grade 3 osteoarthritis. Of the 30 knees showing good results 6% had grade 1, 10% had grade 2, 66.5% had grade 3 and 16.6% had grade 4. At 6 months the results were excellent in 37% and good in 30% knees (of the 37 knees showing excellent results 7% had grade 1, 16.2% had grade 2 and 75.6% had grade 3 osteoarthritis. Of the 30 knees showing good results 6% had grade 1, 13.3% had grade 2, 66.6% had grade 3, 13.3% had grade 4 osteoarthritis. Results were fair in 23% and poor in 3% knees at one month (Of the 23 knees showing fair results, 39% had grade 3, 60% had grade 4 osteoarthritis. Of the 3 knees showing poor results, all had grade 4 osteoarthritis. Results were fair in 27% and poor in 3% knees at 3 months (Of the 27 knees showing fair results. 18.6 had grade 3 osteoarthritis, 81.4% had grade 4 osteoarthritis. Of the 3 knees showing poor result all had grade 4 osteoarthritis). At 6 months follow up 30% knees had fair results and 3% had poor result (Of the 30 knees showing fair results. 23.3% had grade 3 osteoarthritis and 77.7% had grade 4 osteoarthritis, of the 3 knees showing poor result all had grade 4 osteoarthritis). From the above data it is observed that at 6 months out of 55 knees with grade 3 87.2% showed excellent or good results however, of the 15 knees with grade 1 and 2 osteoarthritis 100% showed excellent results. Moreover majority of the knees having fair or poor results had grade 3 osteoarthritis. Hence it is inferred that the benefit of arthroscopic knee lavage supplemented with intra-articular methyl prednisolone in osteoarthritis of knee is far better in patients with osteoarthritis of radiological grade 1 and 2 than grade 3 and 4 [15].

Isserlin in 1950 published a series of 35 cases of severe osteoarthritis of knee in which he performed a joint debridement. He reported a 66% improvement with his procedure. Jackson in 1974 proposed a role for arthroscopic management of the arthritic knee. He reported improvement in 80 to 85% of patients following arthroscopic lavage. The patients with minimal fibrillation, minimal malalignment and no instability have the most favourable response, whereas the patients with articular cartilage fragmentation have variable response and those with expose bone have unpredictable and often negative response [17, 18]. Bird and Ring (1978) reported that arthroscopic lavage resulted in improvement in 93% of patients at one week but only 50% of patients maintained their improvement at one month. Sprague (1981) reported 74% good results, 10% fair results and 16% poor results in 63 patients (69 knees) following arthroscopic debridement of the knee joint. He found no correlation between patient's age at operation and final result. He recommended arthroscopic debridement as a useful therapeutic modality. Jennings (1986) reported 71% good results (criteria not defined) as follow up examination averaging 2 years. His patients were kept non weight bearing for 8 weeks post operatively and one third of them had second look debridement during the study.

Our results of 37% excellent, 30% good, 30% good, 30% fair and 3% poor at six month follow up were compared thoroughly with the series in the literature and we are of the opinion that arthroscopic knee lavage supplemented with intra-articular methyl prednisolone in osteoarthritis of knees. Knees lavage is more beneficial for patients with radiological grade 1 and 2. This treatment reduces the need for analgesic and hence reduces the likelihood of side effects that the

patient may suffer as a result of NSAID intake^[19]. Hence this form of treatment can be used as an alternative or an adjunct to NSAIDs. It can also be tried in patients who are on high doses of NSAIDs, patients unwilling to undergo surgery, patients who require surgery but are medically unfit and patients with mild osteoarthritis who have peptic ulcer.

Conclusions

Knee lavage with intra articular injection of Methyl prednisolone of 100 knees in 75 patients of osteoarthritis knee ranging from grade 1 to grade 4 as per Kellgren and Lawrence radiological grading was done. The aim of the study was to see the effect of knee lavage with intra articular injection of Methyl prednisolone in relieving pain of osteoarthritis. Knee lavage with 3 litres of ringer lactate supplemented with intra articular injection of Methyl prednisolone is very safe and simple procedure and helps in relieving the pain in almost all the cases. This is a very simple procedure which can be used as outpatient treatment only. The magnitude of pain relief is inversely proportional to the severity of the problem but some amount of pain relief is always there. Hence we strongly recommend the use of knee lavage with intra articular injection of Methyl prednisolone in mild to moderate osteoarthritis of knee for short to medium term gains.

References

1. Frymoyer IW (Ed). Orthopaedic knowledge update 4, Home Study Syllabus Chicago, American Academy of Orthopaedic Surgeons, 1993.
2. Goldberg VM, Kellekamp DB *et al*. Osteoarthritis of the knee. Osteoarthritis diagnosis and medical /surgical management. Morkowitz R.W. Howell DS, Goldberg V Metal Philadelphia. W.B Saunders CO, 2nd Ed, 1992, 599.
3. Coventry MB. Osteotomy about the knee for degenerative and rheumatoid arthritis. JBJS. 1973; 55A:23.
4. Beighton P. The inherited disorders of connective tissue part I and II Bulletin on the Rheumatic Diseases, Number 2 and 3, 1972, 23.
5. Brandt KD, Mankin HJ. Pathogenesis of osteoarthritis: Textbook of rheumatology, Kelly WN, Harris ED, Ruddy S *et al*, Philadelphia. WB Saunder Co 4th Ed. 1933, 1355-1373.
6. Burks RT. Arthroscopy and degenerative arthritis of the knee: A review of the literature. Arthroscopy. 1990; 6:43-47.
7. Symposium: Early degenerative arthritis of the knee. JBJS. 1969; 51A:1026.
8. Anderson JK, Goldsmith WM. Arthroscopy in patients over the age of 50 years. Am J Arthroscopy. 1991; 1:15-18.
9. Baumgaertner MR *et al*. Arthroscopic debridement of the arthritic knee. Clin Orthop. 1990; 253:197-202.
10. Aichroth PM, Patel DV. A prospective review of arthroscopic debridement for degenerative joint diseases of the knee. Internet. Orthop. 1997; 151:351-355.
11. Bert JM, Maschka K. The Arthroscopic treatment of unicompartmental gonarthrosis. Arthroscopy. 1989; 5:25-32.
12. Jackson RW, Dietarichs C. The results of arthroscopic lavage and debridement of osteoarthritic knees based on the severity of degeneration: a 4 to 6 year symptomatic follow up. Arthroscopy. 2003; 19(1):13-20.
13. Jackson RW, Marans HJ, Silver RS. Arthroscopic treatment of degenerative arthritis of knee. J B J S. 1988; 70-B:332.
14. Weiss C. Ultra structural characteristics of osteoarthritis. Fed Proc. 1973; 32:1459.
15. Bird HA, Rig EF. Therapeutic value of arthroscopy. Ann Rheum Disease. 1978; 37:78-79.
16. Bohnsack M, Lipka W, Ruhmann O, Peters G, Schmolke S, Wirth CJ. The value of knee arthroscopy in patients with severe radiological osteoarthritis. Arch Orthop Trauma Surg. 2002; 122(8):451-3.
17. Burman MS. Arthroscopy or the direct visualization of joints. JBJS. 1931; 13:669.
18. Cameron JC, Saha S. Meniscal allograft transplantation for unicompartmental arthritis of knee. ClinOrthop. 1997; 337:164-171.
19. Chandnani V, Resnick D. Roentgenologic diagnosis. Osteoarthritis: Diagnosis and medical/Surgical management. Philadelphia WB Saunders Co 2nd Ed, 1992, 263.