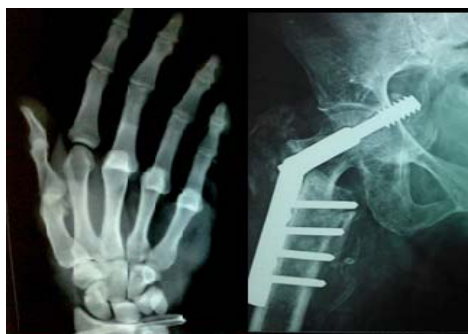



International Journal of Orthopaedics Sciences

ISSN: 2395-1958
IJOS 2018; 4(2): 1029-1033
© 2018 IJOS

www.orthopaper.com

Received: 15-02-2018

Accepted: 20-03-2018

Dr. Rajendra Kumar Pipal
Senior Resident, Department of
Orthopaedics, Govt Medical
College, Bhilwara, Rajasthan,
India

Dr. Dharmendra Kumar Pipal
Assistant Professor, Dept. of
Gen. Surgery, Dr. S. N. Medical
College, Jodhpur, Rajasthan,
India

Dr. Seema Yadav
Assistant Professor, Dept. of
Anaesthesia, Govt Medical
College, Bhilwara, Rajasthan,
India

Dr. Vibha Pipal
Senior Resident, Department of
Gynaecology and Obstetrics,
Aiiims, Jodhpur, India

Dr. Saurabh Kothari
Assistant Professor, Dept. of
Gen. Surgery, Dr. S. N. Medical
College, Jodhpur, Rajasthan,
India

Results of locking compression plate in the management of fracture distal end of femur in adults

**Dr. Rajendra Kumar Pipal, Dr. Dharmendra Kumar Pipal, Dr. Seema
Yadav, Dr. Vibha Pipal and Dr. Saurabh Kothari**

DOI: <https://doi.org/10.22271/ortho.2018.v4.i2o.147>

Abstract

Introduction: The use of locking compression plate in fractures of distal femur in our study seems to be associated with a good functional outcome and early recovery. The DF-LCP is a good implant to use for fractures of the distal femur particularly intra-articular type and osteoporotic fractures. Recent advances in technology for treatment of fractures distal end femur with locking compression plate become popular and has clear biomechanical advantages when compared with conventional plating and other method of fixation. When combined with minimally invasive surgical techniques, locking compression plate may cause substantially less iatrogenic tissue damage when compared with conventional plating. Locking compression plates offers multiple points of fixed-angle contact between the plate and screws, theoretically reducing the tendency for varus collapse that is seen with traditional lateral plates. The commonly observed complications of fracture distal end of femur are knee stiffness, implant failure and loss of reduction are minimal with it. Surgical exposure for plate placement requires significantly less periosteal stripping and soft tissue exposure than that of normal plates.

Materials and Methods: This prospective study was conducted which included 30 patients with fracture distal end of femur (Extra & intra articular type A and C based on AO classification) treated with open reduction and internal fixation with distal femoral locking compression plate (DF-LCP) between November 2011 to October 2013 at in the department of orthopaedics, Govt. Medical college & associated MBS hospital, Kota and followed-up for a minimum period of 6 months. The patient's ages ranged from 18 to 78 with a mean of 42 years. The duration of follow up ranged from 6 months to 21 months. The clinical assessment was conducted at least 6 months post-operatively using the Schatzker & Lambert scoring system.

Results: Result showed that 9 patients had excellent results, 17 good, 2 fair and 2 failures.

Conclusion: The use of locking compression plate in fractures of distal femur in our study seems to be associated with a good functional outcome and early recovery and is a good implant to use for fractures of the distal femur particularly intra-articular type and osteoporotic fractures.

Keywords: distal femoral fracture; open reduction and internal fixation; distal femur locking compression plate; combi-holes

Introduction

In the modern world with the increased density of automobile traffic on roads and ever increasing number of road accidents, there is great increase in number and severity of fractures especially high energy fractures, for instance fractures distal end of femur which are difficult to manage and associated with many complications and continue to perplex the surgeons. There is no general consensus in their management, hence evokes much controversy. Fractures leads to a complex tissue injury involving both the bone and surrounding soft tissues. The conservative management of these fractures often results in malalignment or non-unions, deformity as well as lead to stiffness of adjacent knee joint.

The fracture distal end of femur has some peculiar features

These fractures are usually comminuted which is ascribed to the thinning of cortex due to widened intramedullary canal in this area. These fractures are usually intra-articular and present in cancellous bone.

Correspondence

Dr. Dharmendra Kumar Pipal
Assistant Professor, Dept. of
Gen. Surgery, Dr. S. N. Medical
College, Jodhpur, Rajasthan,
India

The trend of open reduction and internal fixation has been revolving in last few decades with good kind of implants like 95° angled blade plate, dynamic condylar screw, condylar buttress plate, intramedullary supracondylar nail & locking compression plates. However, as the complexity of fractures needing treatment has changed from simple extra-articular supra-condylar types to inter-condylar and metaphyseal comminuted types, these implants may not be ideal.

Fractures around the knee typically require operative fixation to achieve an acceptable, functional outcome. The idea behind the Less Invasive Stabilization System (LISS) was to combine the advantages of both interlocked intramedullary nailing techniques and the early advances of the so-called biological plating technique into one system.¹ The Less Invasive Stabilization System (LISS) allows for fixed angle fixation of the distal femur and minimally invasive fixation of the femoral shaft. However, there has been concern that the implant may be too stiff, and when associated with premature weight bearing by the patient, results in ultimate failure of the implant. External fixation with devices such as the hybrid external fixator and the Ilizarov external fixator are excellent for the treatment of comminuted fractures associated with bone loss. In addition to maintaining reduction whilst awaiting union, these devices can also be used to lengthen the bone. However, pin tract infections and joint contractures are common complications of these techniques.

The complication associated with conventional plate is with increasing axial loading cycles, the screws can begin to toggle, which decreases the friction force and leads to plate loosening. If this occurs prematurely, fracture instability will occur, leading to implant failure. In contrast, LCP follow the biomechanical principles of external fixator and do not require friction between the plate and bone. LCP is a single beam construct where strength of its fixation is equal to the sum of all screw- bone interface rather than a single screw's axial stiffness or pullout resistance as seen in unlocked plates. Its unique biomechanical function is based on splinting rather than compression result in flexible stabilization. Locking the screw into the plate to ensure angular as well as axial stability, eliminates the possibility for the screw to toggle, slide or be dislodged and thus strongly reduces the risk of postoperative loss of reduction and implant failure^[5].

The Locking Compression Plate system combines the facilities of conventional plate osteosynthesis with those of the internal fixator systems. It combines the two treatment methods (i.e., the compression plating and locked internal fixation methods) into one implant. In order to achieve this combination, a new plate hole design (Combi-holes) permits the use of both standard screws and locking head screws, which achieve fixed-angle stability

It has distinct advantages

- Angular stability is provided by locking head screws (Even if monocortical)
- Accurate plate contouring is not required
- There is less damage to the periosteum and its blood supply
- It is more suitable implant for osteoporotic fractures.

The increase in stability provided by LCP is most helpful to surgeons treating a fracture in poor-quality of bone (i.e. Better fixation in osteoporotic bone), substantially less soft tissue dissection may be required, thus preserving the local blood supply and enhancing fracture healing. We did this prospective study to find out the efficacy of locking

compression plates in the treatment of fractures of distal femur & to evaluate functional outcome after completion of treatment and to assess the complications early & late and their management.

Materials and Methods

This prospective study was conducted in patients treated for distal femoral fractures with locking compression plate in the department of orthopaedics, Govt. Medical college & associated MBS hospital, Kota between 1st November 2011 to 31st October 2013 at our institution.

Inclusion criteria

- Patients aged 18 years and above and of either sex.
- Patients with distal femur fractures as determined by clinical examination and diagnostic imaging (X-rays/CT if needed) done.
- Patients presenting with lower end femur fractures with or without osteoporotic changes are included in this study.
- Closed and open (type I) distal femur fractures.

Exclusion criteria

- Patients below 18 years of age and open physis.
- Fracture more than 4 weeks old.
- Open (type II type IIIB & IIIC) distal femur fractures.
- Pre-existing local infection/ deformity.
- Patients with pathological fractures lower end femur other than osteoporosis.
- Other fractures in the same lower limb.
- Patients managed conservatively for other medical illness.
- Fracture lower end femur with neurovascular compromise or knee joint dislocations.
- Patients lost in Follow-up & non compliance patients.

Surgical technique

Patient was placed supine on a radiolucent ordinary OT table with a rolled sheet under the knee. Pneumatic tourniquet applied. A lateral approach was used in all patients. A submuscular tunnel was created using an osteotome. The distal extension of the skin incision was dependent on whether or not an arthrotomy (In C2 & C3 type of fractures) needs to be performed. If joint exposure was needed, the incision was carried to the level of the Gerdy's tubercle.

All reduction was achieved by indirect methods. This involved using small bolsters/bumps placed underneath the distal thigh to correct sagittal plane deformities. Reduction clamps and traction were used to correct alignment in the coronal plane. Under image intensifier guidance, alignment and rotation were restored by judging the hip rotation on the uninjured side using the lesser trochanter as a guide^[3]. The distal fragment was held in the same position as that for the intact femur. Leg length was maintained by traction. In difficult fractures where reduction could not be achieved by indirect methods Open Lateral Approach used for open reduction & internal fixation.

Following reduction, temporary fixation was achieved by the use of multiple Kirschner wires. Under IITV control inter-condylar type fractures were converted to a single condylar block with the help of multiple Kirschner wires and 6.5mm partially threaded cannulated cancellous screw before DF-LCP fixation. Later on Kirschner wires were removed. For proximal fixation, at least 3 or 4 (preferably) locking screws were used. In some patients 2 or 3 locking screws and one simple cortical screw used (for compression) in between. All proximal screws were bi-cortical. For distal fixation, at least 3

or 4 (preferably) metaphyseal locking screws were used. Their sizes did not violate the intercondylar notch space.

Under fluoroscopic guidance, the incision was made over the lateral aspect of the thigh at the level of the proximal screw holes. In most of cases combined technique of internal fixation used. A compression technique of Hansmann. C *et al.*, was used for transverse or short oblique fractures whereas a bridging technique was used for comminuted fractures [2, 8]. Primary bone grafting was performed in patients with severe comminution and bone loss. Postoperatively, the operated limb was kept in elevation on a splint with the knee in 10° to 15° of flexion.

Joint capsule arthrotomy and the iliotibial band were closed with absorbable sutures. A drain was put at fracture site for continuous suction which was removed within 48 hours of operation. Wound was closed in routine manner.

Results

The study sample consisted 30 patients, who satisfied the inclusion criteria were included and all were treated with DF-LCP. Nine patients were female and twenty one patients were male (table-1).

Table 1: Sex Distribution

Sex	Number of patients	Percentage (%)
Male	21	70
Female	9	30
Total	30	100

Table 2: Age Distribution

Age Group (in Years)	Number of patients	Percentage (%)
18-35	12	40
36-45	8	26.66
46-60	5	16.66
> 60	5	16.66
Total	30	100

The patient's age ranged from 18 to 78 years with a mean age of 42 years. Youngest patient in our study was 18 years old and oldest patient was 78 yrs old. The majority of patients (20 out of 30) were fall between 18-45 years of age as they were more involved in outdoor activities or more exposed to vehicular trauma. The Mean age of the patients in the study was found out to be 42.73 years.

In our study, majority 27 patients, (90%) had high energy trauma due to road traffic accident, 3 (10%) had low energy (trivial) trauma due to fall on floor. 27 patients had closed fracture and 3 had open fracture (Guttilo's type I) (table-2). All fractures were classified according to Muller's adopted by AO/OTA classification.

Table 3: Mode of Injury

Mode of Injury	Closed Fracture	Open Fracture	Total	Percentage
Road traffic accident	22	2	24	80
Fall on floor	3	0	3	10
Fall from height	2	1	3	10
Total	27	3	30	100

Results were showing that A.O. type C2 fractures (n=12, 40%) were most common type fractures, C1 (n=6, 20%), C3 (n=5, 16.66%), A3 (n=3, 10%) and A1 & A2 were (n=2, 6.66%) each in this study. There was none of the cases of type B fracture in our study (Table-4).

Table 4: Type of Fracture

Type of Fracture (A.O. Type)	Number of Patients	Percentage
A1	2	6.66
A2	2	6.66
A3	3	10
B1	0	0
B2	0	0
B3	0	0
C1	6	20
C2	12	40
C3	5	16.66

Table 5: Associated Injury

Fracture/ Injury	No. of Cases	%
Fracture tibial plateau in other lower limb	2	6.67
Fracture forearm bones	2	6.67
Fracture distal radius	1	3.33
Fracture humerus	1	3.33
Fracture olecranon	1	3.33
Fracture medial malleoli in other lower limb	1	3.33
Fracture Calcaneum in other lower limb	1	3.33
Head Injury	2	6.67

In our study, the mode of injury was RTA (high energy trauma) in majority of cases which was associated with injury to other body parts also. Associated injuries were present in 36.67% of cases.

Table 6: Time at which Partial weight bearing started

Achieved time (weeks)	No. of Cases	Percentage
6-7	18	56.66
8-9	10	36.66
10-12	2	6.66
> 12	0	0
Total	30	100

In present study, this table shows that majority of cases allowed to bear partial weight at 6-9 weeks. Mean were 7.33 weeks. SD is 1.34, which is statistically significant.

Table 7: Time at which Full weight bearing started

Achieved time (Weeks)	No. of Cases	Percentage
12-14	2	16.66
14-16	23	76.66
16-20	2	6.66
>20 (Delayed)	2	6.66
Total	30	100

In our study, this table show that majority of cases allowed to bear full weight between 14-18 weeks after radiological union achieved. Mean were 16.14 Weeks. S.D 1.80, which was statistically significant.

Table 8: Duration of stay in hospital

In days	Femur	
	No.	%
< 5	7	23.33
5-10	2	6.66
10-15	21	70
total	30	100

The average length of hospitalisation was 11.5 days with a range of 3 to 15 days (Table-8).

The average number of days from injury to surgery was 4.5 days with a range of 2 to 10 days (Table-9).

Table 9: Time Interval between injury and Surgery

Time Interval	No. of Cases	Percentage
Within 3 days	17	56.66
4-7 days	10	33.33
> 7 days	3	10
Total	30	100

Radiological Union

In present study, the mean radiological union time was 16.14 weeks. SD 1.98. P value was <0.0001, which was statistically significant.

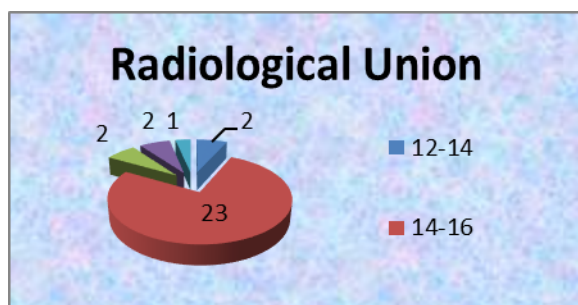


Chart 1: Radiological Union

Table 10: Complications

Complications	No. of Cases	Percentage
Superficial infection	2	6.66
Fever	2	3.33
Occasional Pain	6	3.33
Delayed Union	2	6.66
Plate Back out	Nil	0
Deep Infection	Nil	0
Non- Union	1	0
Implant failure- screw/ plate breakage	Nil	0
Stress Fracture	Nil	0

In our study, 2 patients had Superficial Infection & fever and 2 patients had delayed union which showed signs of union later on follow-up. One patient had signs of nonunion. None of patients had implant failure (screw/plate breakage), stress fracture and deep infection.

Table 11: Range of Motion of the affected Knee

Range of Motion	Number of Patients	Percentage
< 90	2	6.66
90-120	19	63.33
>120	9	30
Total	30	100

Mean flexion 112° (range 75° to 130°). Using Schatzker & Lambart knee scoring system, there were nine excellent results, seventeen good, two fair and two failures.

In the present study, Out of the 30 patients 9 (30%) had Range of Motion greater than 120°, which according to the criteria described previously falls in the excellent range. 19 patients (63.33%) had a range of motion between 90° - 120° which falls in the good category. 2 patients had fair and 2 had poor outcome. Mean Range of Motion 112° degree. SD 2.01 which was statistically significant (Table-11).

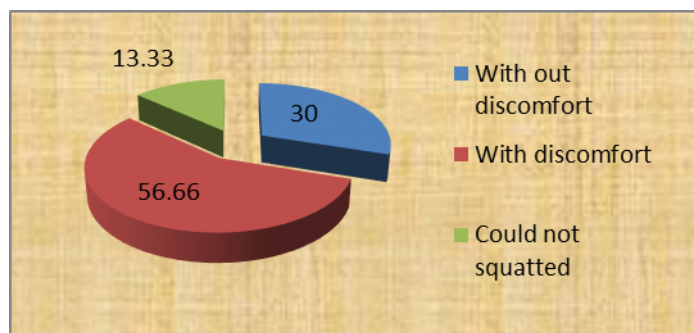


Chart 2: Sitting in squatting position

In the present study, 9 out of 30 (30 %) of cases squatted without discomfort those had excellent results, 17 cases (56.66 %) squatted with discomfort those had good results and 4 cases (13.33%) could not squatted those had fair & poor results.

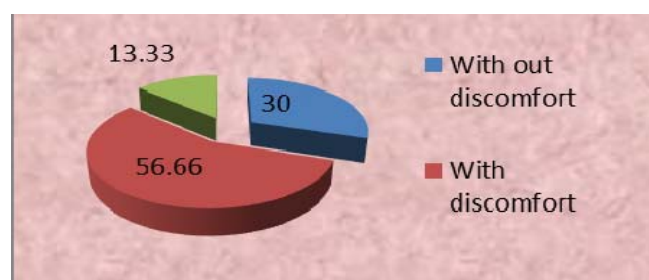
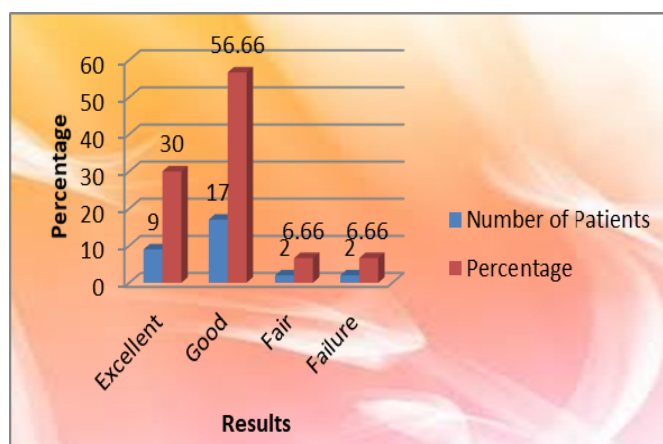


Chart 3: Sitting in cross lagged position



Graph 4: Functional result (Schatzker lambert Grading)

In present study, this table shows 17 out of 30 cases 56.66 % had good results. 9 cases out of 30 cases 30 % had excellent and 2 cases 6.66% had fair results (Unsatisfactory) and 2 cases 6.66% had failure results.

Discussion

There are several options for management of distal femur fractures. In the last decade, the use of LISS type internal fixation brought a new perspective for the treatment of articular fractures cases with small distal fragment and fractures in osteoporotic bones.

It was a prospective study. In the present study, (70%) patients were male & (30%) patients were female. Ravi M Nayak *et al.*, observed in their study that 70.96% patients were male and 29.04% were female [8].

In the present study, the most common mode of injury was

road traffic accidents (80%) in young people & remaining (20) % was because of fall from height or domestic falls in elderly. These are similar in the series of Ravi M Nayak *et al*, where 77.41% cases were brought to the hospital due to road traffic accidents & 19.24% were came due to falls and 10.04% were came because of assault [8]. On the contrary in the study of Ej Yeap *et al*, 63.63% patients had injury due to motor vehicle accidents [9]. In our country, road traffic accidents are very common due to bad road conditions, poor traffic control and rash driving. Most of young age group had fracture of distal femur by road traffic accident and most of elderly people due to falling down on floor. That is why in our series & also of other studies young age group persons involved more.

The most common fracture in the present study was C2 (40%) followed by C1, C3 and A2 respectively. Similar observations were also found in the series of Rajesh C *et al*, where C2 type occurred in 12 cases (36.66%) followed by C3, A2, & A3 [7]. Most of the patients in our study, 27 cases (90%) were operated within 10 days after injuries. Similar observations made by Ej Yeapet, they found that the average number of days from injury to surgery was 9.9 days [10]. In our study delay in elective surgery was due to either late reporting to the hospital or because of other associated comorbid medical or surgical problems such as hypertension, diabetes, blunt trauma abdomen, head injury etc.

The mean time to radiological union in our study was 16.14 weeks (range 14-18 weeks). This is comparable to contemporary study of Rajesh C *et al*, where mean time was 16.8 weeks [6]. On the contrary in the series of Ravi M Nayak *et al*, mean time was 12 weeks (ranged 12-16 weeks), while in the series of Ej Yeap *et al*, mean time was 18 weeks (ranged 6-36 weeks) [8, 10]. The difference in the mean time to union could be attributed to different types of fractures being included in every study and also to the different age groups of patients included.

The mean range of motion in the present study was 112° with more than 50% patients having knee range of motion more than 110°. In the present study, ROM of the affected knee was > 120° in 9 (30 %) cases, 90-120° in 19 (63.33%) cases and <90° in 2 (6.66%) cases. Other workers had Similar results in their studies like Ej Yeap *et al*, observed that mean range of motion was 107.7° (range 40°-140°) [9].

The LCP acts on the internal fixator principle. As screws once locked to the plate do not pull the fracture towards the implant, and hence there is no displacement of the fracture once reduced. LCP combi-holes in the plate shaft facilitate intraoperative choice between angular stability and/or compression or both. The LCP is compatible with minimally invasive percutaneous osteosynthesis (MIPO), enables biological fixation. As it preserves periosteal blood supply and bone perfusion, and requires less soft-tissue dissection, contribute to enhance fracture healing. In the present study, the objective was to assess the effectiveness of LCP in the management of distal femur fracture in adults.

DF-LCP can be used to bridge comminuted distal femur fracture, healing between fragments must occur by secondary bone healing with callus formation which is mediated by interfragmentary motion in the millimeter range. The outcome seems to correlate with type of fracture, anatomic reduction, bone quality, length of time elapsed from injury to surgery, concomitant injuries, and exact positioning and fixation of the implant (Neer CS *et al*,) [4].

In our study, excellent results were in all A type of fractures and some cases of type C1. The failure was noted in C3 type

of fractures and fair to good results were noted in type C2 & some cases of C1. None of type B case was found in the present study. This shows that final results depends on type of fractures largely apart from other factors like age of patients, open/closed injuries, bone quality, fracture reduction, stable internal fixation and physiotherapy.

Conclusion

The use of locking compression plate in fractures of distal femur in our study seems to be associated with a good functional outcome and early recovery. The DF-LCP is a good implant to use for fractures of the distal femur particularly intra-articular type and osteoporotic fractures. However, anatomic reduction, accurate positioning and fixation are required to produce satisfactory results. The device provides good angular stability & thus helps in early mobilization, even in comminuted fractures. The commonly observed complications of fracture distal end femur are knee stiffness; implant failure and loss of reduction are minimal with DF-LCP.

The DF-LCP provides good stable fixation in the metaphyseal region of femur, where a widen canal, thin cortices and frequently poor bone stock make fixation difficult. Surgical exposure for plate placement requires significantly less periosteal stripping and soft tissue exposure than that of normal plates. We recommend use of this implant in all type of fractures distal end of femur, specially useful in osteoporotic fractures in adults.

References

1. Frigg R, Appenzeller A, Christensen R, Frenk A, Gilbert S, Schavan R. The development of the distal femur Less Invasive Stabilization System (LISS). *Injury*, 2001; 32:SC24-31.
2. Hansmann C. Eine neue Möglichkeit der fixierung der fragmente beikmolizierten frakturen. *Versh. dtsch. ges. chir.* 1886, 158.
3. Hampton. Quoted by Stewart MJ, Sisk TD, Wallace SL. Fractures of distal third offemur. A compression method of treatment *JBJS*. 1966; 48(A):7840807.
4. Neer CS, Gratham SA, Shelton ML, *et al*. supracondylar fractures of adult femur. *JBJS*. 1967; 49(A):591-613.
5. Zlowodzki M, Williamson RS, Cole PA, *et al*. Biomechanical evaluation of the Less Invasive Stabilization system angled blade plate, and retrograde intramedullary nail for the internal fixation of distal femur fractures. *J Orthop Trauma*. 2004; 18:494-502.
6. Dhanasekara Prabu, Chandra R. Results in distal femoral fractures after fixation with a locking compression plate in a level 1 Trauma center in India. *Journal of Young Medical Researchers*, 2013.
7. Lane WA. *Operative Treatment of Fracture* Ed 2. London, Medical Publishing Company, 1914.
8. Ravi M Nayak, MR Koichade. Minimally invasive plate osteosynthesis using a locking compression plate for distal femoral fracture. *Journal of Orthopaedic Surgery*. 2011; 19(2):185-90.
9. Yeap EJ, Deepak AS. Distal femoral Locking compression plate fixation in Distal Femoral Fractures: Early Results. *Malaysian Orthopaedic Journal*. 2007; 1(1):12-17. ISSN 1985 2533.