



International Journal of Orthopaedics Sciences

ISSN: 2395-1958
IJOS 2018; 4(1): 456-458
© 2018 IJOS
www.orthopaper.com
Received: 16-11-2017
Accepted: 19-12-2017

Dr. Ravi Mehrotra
M.S. Orthopaedics, Clinical
Fellow Joint Replacement Unit,
Sir Ganga Ram Hospital,
New Delhi, India

Dr. Pawan Kumar
M.S. Orthopaedics, Clinical
Fellow Joint Replacement Unit,
Sir Ganga Ram Hospital,
New Delhi, India

Dr. Deepinder Chaudhary
M.S. Consultant Joint
Replacement Surgeon, Sir Ganga
Ram Hospital, New Delhi, India

Dr. Pratik Patel
D. Orth, Dnb Student, Sir Ganga
Ram Hospital, New Delhi, India

Dr. Ashwani Singh
Senior Resident Orthopaedics,
S.N. Medical College, Agra,
Uttar Pradesh, India

Melorheostosis: Case report of rare disease

**Dr. Ravi Mehrotra, Dr. Pawan Kumar, Dr. Deepinder Chaudhary,
Dr. Pratik Patel and Dr. Ashwani Singh**

DOI: <https://doi.org/10.22271/ortho.2018.v4.i1.g.66>

Abstract

Introduction: Melorheostosis is a rare chronic bone disease, characterized by linear hyperostosis along the bone cortex. First case described in 1922 by Leri and Joanny. It can affect any bone, being more frequent in long bones. The etiology remains unknown although several theories have been proposed. Men and women are equally affected, and no hereditary features have been discovered. Onset is insidious, and most common symptoms are pain, deformity and joint stiffness. The diagnosis is obtained by combining the clinical and radiological findings (mainly radiography with typical image in "candle wax"). There is no definitive or specific treatment, being always palliative.

Case report: We describe a case of a 35-year-old woman presented with a history of left forearm dull and aching pain with mild swelling. There was no relevant family history or trauma. Physical examination revealed a firm non-tender swelling over distal half of the left forearm. The pathology report described nonspecific, dense cortical bone with mature and immature bone tissues. X-rays showed hyperostosis of the radius of the right forearm (image in "candle wax"). The patient is in physical therapy program and has a positive response to analgesics and intravenous bisphosphonate zoledronic acid.

Conclusion: The exact etiology remains unclear. There is no definite treatment available for this rare disease. Only symptomatic treatment improve the condition of the patients, quit well result obtain with zoledronic acid and physiotherapy.

Keywords: Melorheostosis, mild swelling, bisphosphonate zoledronic acid, physiotherapy

Introduction

Melorheostosis is quite a rare chronic bone disorder characterised by mesodermal dysplasia of bone, also known as Leri's disease, candle bone disease or melting wax syndrome. The disease was first described by Leri and Joanny in 1922 [1]. The etiology is unknown, although several theories have been proposed, such as a mesenchymal cell differentiation defect (genetic mutation in LEMD 3 gene, vascular disorders or inflammatory processes. None of these theories have been completely proven [2]. It can affect any bone, being more common in long bones. Men and women are equally affected, and no hereditary features have been reported. Most common presentation is pain & most common involved bone part is diaphysis of long bones with rare involvement of axial skeleton [3]. Diagnosis is obtained by combining the clinical and radiological findings (flowing hyperostosis/ candle wax appearance) [4]. There is no definitive treatment, it always palliative.

Case report

A 35-year-old woman presented with a history of left forearm dull and aching pain with mild swelling. Her limb pain presented since last 12 years. The swelling gradually progressed. There was no relevant family history or trauma. Physical examination revealed a firm non-tender swelling over distal half of the left forearm. The swelling was bony hard, non-tender and Skin temperature was normal. Elbow and wrist joint movement was normal as compare to right side. No other abnormality was detected in the right upper limb and lower limbs. Plain radiographs (Fig 1) of left forearm showed extensive, dense, irregular cortical hyperostosis, resembling candle wax, extending along the length of bone, resulting in deformity of the bone and narrowing of the medullary cavities. A plain radiograph of the bones on the right upper limb was normal. MR findings reveal near total diaphyseal cortical extensive homogenous osteoid overgrowth encroaching on medullary cavity resulting in expansion and remodelling of

Correspondence

Dr. Ravi Mehrotra
M.S. Orthopaedics, Clinical
Fellow Joint Replacement Unit,
Sir Ganga Ram Hospital,
New Delhi, India

left radial shaft, no evidence of any associated vascular malformation or soft tissue abnormality, no pathological fracture seen (fig 2). Laboratory findings revealed a normocytic anaemia, serum calcium, phosphorus, alkaline phosphatase, ESR, C-reactive protein, α -fetoprotein, carcinoembryonic antigen were all within normal limits. The

pathology report described nonspecific, dense cortical bone with mature and immature bone tissues. Single infusion of 5 mg zoledronic acid over 30 minute and analgesics were given to the patient. Physiotherapy started to prevent the deformity. After 3 months in follow up, the patient reported alleviation of the pain.

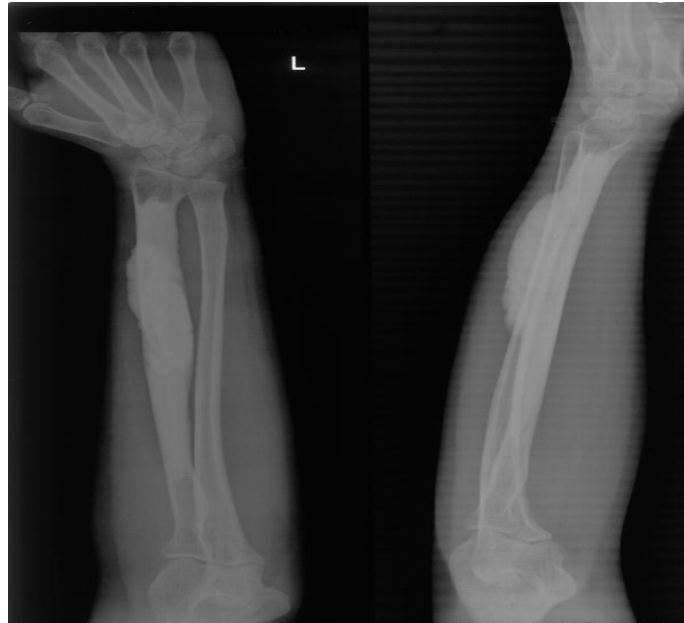

Fig 1: X- ray left forearm AP and Lateral showing hyperostosis left radius cortex with obliteration of medullary canal and candle wax appearance of cortex.

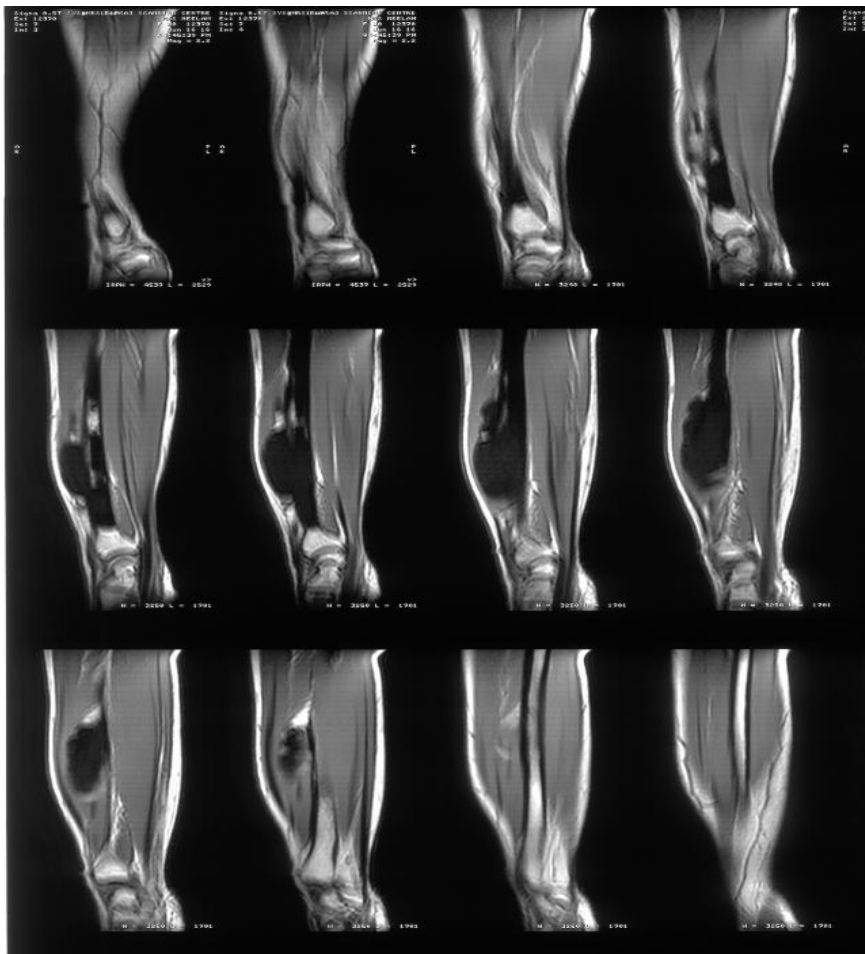


Fig 2: MR findings reveal near total diaphyseal cortical extensive homogenous osteoid overgrowth encroaching on medullary cavity resulting in expansion and remodelling of left radial shaft, no evidence of any associated vascular malformation or soft tissue abnormality, no pathological fracture seen.

Discussion

We reported this case because of its rarity and on differential diagnosis doubts raised to other disease such as osteomyelitis or tumors. When it affects long bones it is usually diagnosed by the characteristic “dripping candlewax” image. Bone biopsy and microbiological cultures of affected tissue must be done to differentiate the disease from above mentioned differential diagnosis, although these investigations are not required for the diagnosis of melorheostosis. The disease affects Male and female equally, and no hereditary features have been discovered. This rare disease has insidious onset, and usually present with dull aching pain due to subperiosteal bone formation. Skin becomes rough, hard and in 17% of cases that may have hyperpigmentation. Melorheostosis commonly affects, the long bones of the upper and lower limb, it can affects short bones of hand and foot, but rarely the axial skeleton [5, 6]. Melorheostosis may present in a monostotic, polyostotic, or monomelic form. The monomelic form is most common [7]. In this patient, left forearm was affected.

The several hypotheses are given but the exact aetiology remains unclear. Most accepted hypothesis was given by Murray and McCredie 1979 [8] was that, embryonic infection of nerve root causes neural scarring and segmental bone sclerosis responsible for melorheostosis. Kim J-E demonstrated that there is down regulation of adhesion proteins those involved in osteoblastic regulation, specifically transforming growth factor β induced gene product, which helps in the development of hyperostosis and associated soft tissue abnormalities [9]. Another possible aetiology of melorheostosis is a loss of function mutation in the LEMD3 gene, a protein involved in bone morphogenic protein and tumor growth factor- β signalling [10]. Above mentioned both hypothesis support the genetic involvement of the disease so further work have to be done, to find out exact cause and role of gene therapy for this rare disease.

Routine lab investigations usually are normal. Histological findings are usually nonspecific and often show dense bone formation with combination of mature and immature bone elements [11]. Osteoblastic activity along the margins of osteons is common feature, whereas osteoclastic activity is not prominent [12]. In this patient haematological reports was almost normal. Radiological features show flowing hyperostosis appear like hardened wax which has dripped down the side of the candle.

Treatment is mainly symptomatic; Bisphosphonate and physiotherapy are commonly used [13]. Operative treatment consists of tendon lengthening, hyperostosis bone excision, osteotomies, sympathectomy and amputation. In melorheostosis, Potential causes of the bone pain included increased osteoclastic bone resorption and activation of pain receptors, raised intraosseous pressure and increased vascularity secondary to hyperostosis and soft tissue involvement around joints. Thus, bisphosphonate treatment would be expected to reduce inflammatory bone pain and symptoms in melorheostosis via a number of mechanisms. Bisphosphonates inhibit osteoclastic bone resorption by direct and indirect actions on osteoblasts and macrophages and bone vascularity. They have been shown to decrease bone pain, slow progression of bone lesion [14].

The prognosis of a patient with melorheostosis is quit variable, it depends on the anatomical location, soft tissues extension, and other soft tissue changes. Melorheostosis does not shorten life Span, however, morbidity may be considerable. The diseases have a slow, chronic course, with

periods of exacerbation and arrest. Recurrence is common after operative excision [15].

Conclusion

Melorheostosis is a rare chronic bone disease, characterized by linear hyperostosis along the bone cortex. It is only diagnosed by characteristic candle wax type appearance in x-ray film. There is no definite treatment available for this disease. Only symptomatic treatment improves the condition of the patients, better result obtains with intravenous zolendronic acid and physiotherapy.

References

1. Leri A, Joanny J. Une affection non décrite des os hyperostose en coulée sur toute la longueur d'un membre ou melorhéostose Bull Mem Soc Med Hosp Paris. 1922; 46:1141-1145.
2. Hellemans J, Preobrazhenska O, Willaert A, Debeer P, Verdonk PC, Costa T *et al.* Loss-of-function mutations in LEMD3 result in osteopoikilosis, Buschke-Ollendorff syndrome and melorheostosis. Nat Genet. 2004; 36(11):1213-8.
3. Biau O, Avimadje M, Guira O, Adjagba A, Zannou M, Hauzeur JP. Melorheostosis with bilateral involvement in a black African patient. Joint Bone Spine. 2004; 71(1):70-2.
4. Long HT, Li KH, Zhu Y. Case report: severe melorheostosis involving the ipsilateral extremities. Clin Orthop Relat Res. 2009; 467(10):2738-43.
5. Greenspan A, Azouz EM. Bone dysplasia series: melorheostosis: review and update. Can Assoc Radiol J. 1999; 50:324-330.
6. Freyschmidt J. Melorheostosis: a review of 23 cases. Eur Radiol. 2001; 11:474-9
7. Zeiller SC, Vaccaro AR, Wimberley DW, Albert TJ, Harrop JS, Hilibrand AS. Severe myelopathy resulting from melorheostosis of the cervicothoracic spine: a case report. J Bone Joint Surg Am. 2005; 87:2759-2762.
8. Murray RO, McCredie J. Melorheostosis and the sclerotomes: a radiological correlation. Skeletal Radiol. 1979; 4:57-71.
9. Kim J-E, Kim E-H, Han E-H *et al.* A TGF- β -inducible cell adhesion molecule, β ig-h3, is downregulated in melorheostosis and involved in osteogenesis. J Cell Biochem. 2000; 77:169-78.
10. Mumm S, Wenkert D, Zhang X, McAlister WH, Mier RJ, Whyte MP. Deactivating germline mutations in LEMD3 cause osteopoikilosis and Buschke-Ollendorff syndrome, but not sporadic melorheostosis. J Bone Miner Res. 2007; 22:243-250.
11. Ethunandan M, Khosla N, Tilley E, Webb A. Melorheostosis involving the craniofacial skeleton. J Craniofac Surg. 2004; 15:1062-1065.
12. Campbell CJ, Papademetriou T, Bonfiglio M. Melorheostosis: a report of the clinical, roentgenographic, and pathological findings in fourteen cases. J Bone Joint Surg Am. 1968; 50:1281-1304.
13. Kumar *et al.* melorheostosis- case report of rare disease. J orthop case rep. 2014; 4(2):25-27.
14. Wood J, Bonjean K, Ruetz S *et al.* Novel antiangiogenic effects of the bisphosphonate compound zoledronic acid. J Pharm Experimental Therapeutics. 2002; 302:1055-61.
15. Goldman AB, Schneider R, Huvos AS, Lane J. Case report 778. Melorheostosis presenting as two softtissue masses with osseous changes limited to the axial skeleton. Skeletal Radiol. 1993; 22(3):206-210.