



International Journal of Orthopaedics Sciences

ISSN: 2395-1958
IJOS 2018; 4(1): 335-338
© 2018 IJOS
www.orthopaper.com
Received: 17-11-2017
Accepted: 21-12-2017

Dr. Suyog Chavhan
Senior Resident, Department of
Orthopedics, V.N. Desai
Hospital, Santacruz, Mumbai,
Maharashtra, India

Dr. Ranjit Modak
Senior Resident, Department of
Orthopedics, V.N. Desai
Hospital, Santacruz,
Mumbai, Maharashtra, India

Dr. Srikanth Madikattu
Senior Resident, Department of
Orthopedics, Jehangir Hospital,
Pune, Maharashtra, India

Dr. Jemikumar Kansagara
Senior Resident, Department of
Orthopedics, Jehangir Hospital,
Pune, Maharashtra, India

Dr. Amrut Swami
Assistant Professor, Department
of Community Medicine, RCSM
GMC Kolhapur, Maharashtra,
India

A cross sectional study of functional outcome of proximal humerus fractures treated with closed reduction and percutaneous pinning

Dr. Suyog Chavhan, Dr. Ranjit Modak, Dr. Srikanth Madikattu, Dr. Jemikumar Kansagara and Dr. Amrut Swami

DOI: <https://doi.org/10.22271/ortho.2018.v4.i1e.50>

Abstract

The most common orthopaedic injuries related to falls and road traffic accidents are fractures. Mostly these are hip fractures, distal radial fractures and the fractures of humerus. Proximal humerus fractures represent approximately 4% of all the fractures. Increased number falls and increased prevalence of osteoporosis leads to more number of cases of proximal humerus fractures. In elderly patients the most common mechanism of injury in proximal humeral fractures is a fall from standing height onto an outstretched upper extremity. In patients less than 50 years of age, high energy trauma like motor vehicle accidents and falls from significant heights or athletic injuries are the most common causes for these fractures.

In our study, we evaluated 50 cases of proximal humerus fractures treated at department of orthopaedics of a medical college and tertiary care institute. Patients were treated with closed reduction and percutaneous pinning. Neer's functional assessment was used for post-operative functional assessment of these cases. Majority of the patients were from the age group of 41-60 years (50%), 56% were males while 44% were females. Most of the patients had right sided humeral fractures (62%). Commonest mode of injury in these patients was fall (68%), while rest of the patients (32%) had road traffic accidents. Majority of the patients (66%) required 10-12 weeks for union of fractures, the mean time of union being 10.63 weeks. 2 – Part Neer's type patients contributed 56% of the study population. 75% of the patients did not have any complication. Only one patient experienced failure of fracture healing, while most of the patients (56%) had excellent functional outcome.

Keywords: proximal humerus fractures, percutaneous pinning, functional outcome

Introduction

With increase in age, the incidence of injuries and fractures increases. The most common fractures are hip fractures, distal radial fractures and the fractures of humerus. Proximal humerus fractures represent approximately 4% of all fractures and 26% of humerus fractures^[1]. The risk factors for proximal humeral fractures are primarily associated with low bone mineral density and an increased risk of falls. The most common mechanism of injury in proximal humeral fractures in elderly patients is a fall from standing height onto an outstretched upper extremity. In patients aged less than 50 years, the mechanism is often related to high-energy trauma, such as significant falls from height, motor vehicle accidents, or athletic injuries^[1].

The proximal humerus fractures lead to temporary disability and a significant loss to working young and middle aged population with loss of working hours and problems in daily routine. Restoration of the function of the limb is of paramount importance. Treatment of proximal humerus fracture has been the subject of much controversy and confusion.

Several therapeutic approaches have been proposed depending on fracture pattern, patient's age, general health status, and level of activity: conservative treatment^[2], open reduction and internal fixation (ORIF)^[3], joint replacement^[4,5] and percutaneous fixation^[6,7].

Although a number of reports have described the outcome of treatment of proximal humeral fractures, comparison of this fracture is hampered by inconsistency in fracture classification, treatment and evaluation methods^[8,9].

Correspondence

Dr. Suyog Chavhan
Senior Resident, Department of
Orthopedics, V.N. Desai
Hospital, Santacruz, Mumbai,
Maharashtra, India

Neer classification system is one of such classification systems for proximal humerus fractures.

Present study was planned to evaluate the functional outcome of proximal humeral fractures treated with closed reduction and percutaneous pinning.

Objectives

1. To study cases of proximal humerus fractures.
2. To study the functional outcome of these cases.

Methodology

A cross sectional study of cases of proximal humerus fractures treated at Dr. Vasantrao Pawar Medical College and Hospital, Nashik, Maharashtra. This study was carried out for a period of two years, August 2014 to July 2016. All the cases of proximal humerus fractures, visiting the Orthopaedics department OPD and admitted cases were included. Consecutive type of non-probability sampling was used for selection of study subjects. A total of 50 consecutive patients were included in the study after satisfying the eligibility criteria and after obtaining the written informed consent.

Inclusion criteria

1. Adults, more than 18 years of age with proximal humerus fractures.
2. Two, three or four part fractures (defined as < 45 degree of angulation of articular surface or less than 1 cm of displacement between major fragments).
3. Where fracture is un-displaced or displaced, but there is no comminution.
4. Where fracture can be reduced close.
5. Maintenance of glenohumeral congruity.
6. Patients willing to participate in the study.

Exclusion criteria

1. Medically unfit patients.
2. Pathological fractures. (Excluding osteoporotic fractures)
3. Shaft humerus fractures with proximal extension.
4. Seropositive patients.
5. Neer’s one part fracture.

The detailed clinical history, complete general, systemic examination and preoperative investigation findings were noted in a predesigned proforma.

After doing closed reduction and percutaneous pinning, post-operatively, all the patients were assessed for the functional outcome using Neer’s functional assessment key at post-operative interval of 1 month, 3 month and 6 month.

To study the post-operative complications of procedure, the patients were assessed after 24 hrs and on subsequent scheduled follow-up. Post-operative complication if any of the procedure were also noted.

Statistical analysis

Data collected using the proforma prepared for the study, data was entered in Microsoft Excel 2013 and results were presented as per requirement in terms of frequencies and percentages.

Ethical approval was obtained from the institutional Ethics committee and patients willing to participate by giving written informed consent were included in the study.

Results

Mean age of the study participants was 51.6 years, with majority of the patients (50%) between the age group of 41 – 60 years. 24% patients were less than 40 years while 26% patients were more than 40 years. There were total 28 males (56%) and 22 females (44%) in our study. Right sided fractures were seen in 62% of the patients & Left sided fractures were seen in 38%. Most common mode of injury was fall, observed in 34 patients (68%), 16 patients (32%) had injuries due to road traffic accidents (RTA). Mean time for union of proximal humeral fractures after closed reduction and percutaneous pinning was 10.63 weeks. Union was achieved in 17 patients (34%) within 8-10 weeks and in 33 patients (66%) within 10-12 weeks.

Table 1: Distribution of patients based on type of fracture:

Fracture Type (Neer’s)	Number of Patients	Percentages
2 - Part	28	56%
3 - Part	19	38%
4 - Part	3	6%
Total	50	100%

Majority of patients, 28 (56%) were of 2-part Neer’s type, others were of 3- part (38%) and 4- part (6%).

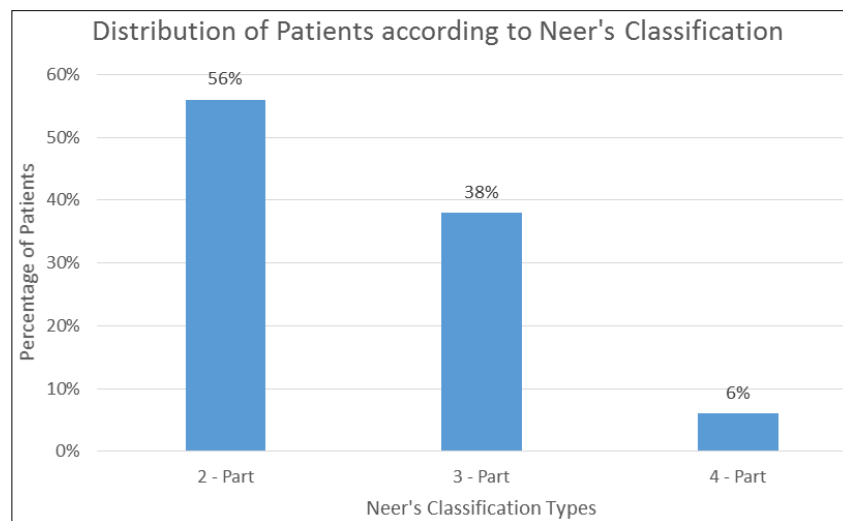


Fig 1: Neer's Classification Types

Out of all the patients, reduction was achieved in 47 patients (94%), while failed reduction was seen in 3 patients (6%). In failed reduction cases, 2 patients had 3 – part fractures while one had 4 – part fracture.

Table 2: Post-operative complications.

Complications	Number of Patients	Percentage
Loss of Reduction	5	10%
Pin Loosening	3	6%
Pin Tract Infection	4	8%
None	38	76%
Total	50	100%

38 (76%) out of the all 50 patients didn't have any complications post operatively. While 12 patients experienced post-op complications, 5 (10%) patients had Loss of Reduction, 3 (6%) experienced Pin Loosening, while 4 (8%) had Pin Tract Infection.

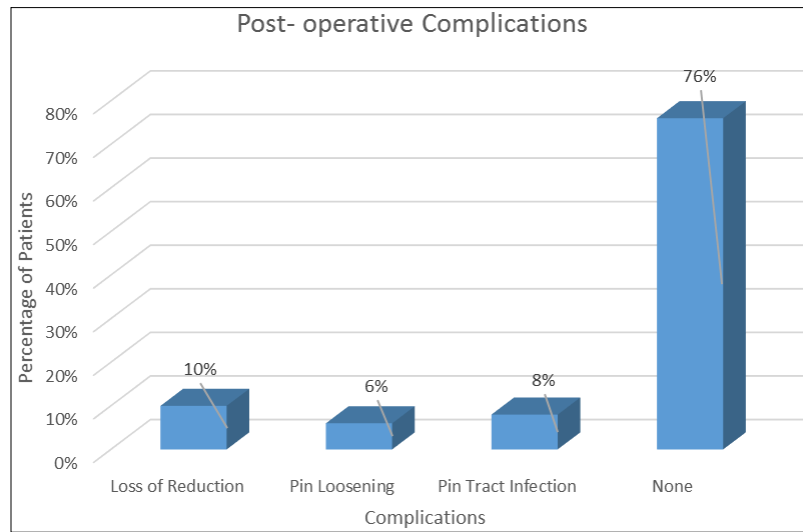


Fig 2: Post- operative Complications

Table 3: Distribution of patients on Functional Outcome

Functional Outcome	Number of Patients	Percentage
Excellent	28	56%
Satisfactory	9	18%
Unsatisfactory	12	24%
Failure	1	2%
Total	50	100%

Excellent functional outcome was observed in 56% cases while satisfactory outcome was seen in 18% cases. Unsatisfactory outcome was observed in 12 (24%) cases while failure was seen in 1 (2%) case.

One case of failure was a 70 year old male with 3 part fracture occurred as a results of vehicular accident. Proper reduction was not achieved in this cases which ultimately led to poor outcome.

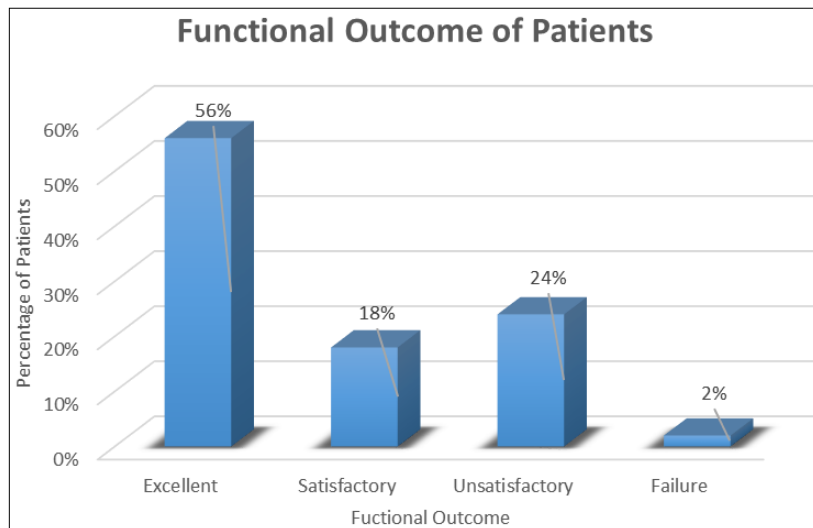


Fig 3: Functional Outcome

Conclusion

Our study concluded that closed reduction and percutaneous pinning is effective, reliable and less invasive procedure in the management of proximal humerus fractures, achieving good results in most of the patient.

This technique was useful to maintain and stabilize the reduction, the reduction restores the anatomic alignment and early mobilization of the stabilised fracture fragments. This

maximizes the shoulder motion and helps in early return to normal activities. The associated complication rate was also minimal.

References

1. Court-Brown CM, Garg A, McQueen M *et al.* The epidemiology of proximal humeral fractures. *Acta Orthop Scand.* 2001; 72:365-371.

2. Zyto K, Ahrengart L, Sperbert A, Törnkvist H. Treatment of displaced proximal humeral fractures in elderly patients. *J Bone Joint Surg Br.* 1997; 79B:412-7.
3. Ring D. Current concepts in plate and screw fixation of osteoporotic proximal humerus fractures. *Injury.* 2007; 3:559-68.
4. Reitman RD, Kerzhner E. Reverse shoulder arthroplasty as treatment for comminuted proximal humeral fractures in elderly patients. *Am J Orthop.* 2011; 40:458-61.
5. Jaberg H, Warner JJ, Jakob RP. Percutaneous stabilization of unstable fractures of the humerus. *J Bone Joint Surg Am.* 1992; 74A:508-15.
6. Karataglis D, Stavridis SI, Petsatodis G, Papadopolous P, Christodoulou A. New trends in fixation of proximal humeral fractures: A review. *Injury.* 2011; 42:330-8.
7. Bigliani LU, McCluskey GM 3rd. Prosthetic replacement in acute fractures of the proximal humerus. *Semin Arthroplasty.* 1990; 1(2):129-37.
8. Bastian JD, Hertel R *et al.* Initial post-fracture humeral head ischemia does not predict development of necrosis. *J Shoulder Elbow Surg.* 2008; 17(1):2.
9. Fjalestad T, Hole MO, Blücher J, Hovden IA, Stiris MG, Strømsøe K *et al.* Rotator cuff tears in proximal humeral fractures: an MRI cohort study in 76 patients. *Arch Orthop Trauma Surg.* Aug 14, 2009.