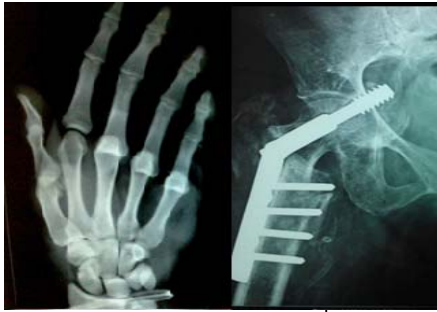



# International Journal of Orthopaedics Sciences

ISSN: 2395-1958  
IJOS 2017; 3(2): 482-487  
© 2017 IJOS  
www.orthopaper.com  
Received: 11-02-2017  
Accepted: 12-03-2017

**Dr. Tarsem Motten**  
Lecturer, SKIMS Medical College  
Bemina, Srinagar, Jammu and  
Kashmir, India

**Dr. Raghavendra V**  
Assistant Professor,  
Department of Orthopaedics,  
PES Medical College, Kuppam,  
Andhra Pradesh, India

**Dr. Nadeem Ali**  
Senior Resident, Orthopaedics,  
Skims Medical College, Srinagar,  
India.

## Functional outcome of management of lower lumbar (L-3 to L-5) burst fractures: A multicentre study of 34 cases

Tarsem Motten, Raghavendra V and Nadeem Ali

DOI: <http://dx.doi.org/10.22271/ortho.2017.v3.i2e.41>

### Abstract

**Aim and Objective:** Lower lumbar burst fractures are rare entity with most of the literature restricted to small case series. There is no clear cut consensus on the guidelines for management. Here we present functional results of different modalities of treatment of this rare type of spine injury.

**Material and Methods:** The study was conducted at two tertiary care centres over a period of 9 years. Patients with lower lumbar burst fractures were evaluated for associated injuries, modality of treatment, Pain score (VAS) and neurological status (Frankel Grade) at the time of injury and at final follow up were recorded. The final functional outcome was evaluated using Smiley-Webster functional score.

**Results:** A total of 34 patients with an average age of 37.3 years (24 males; 10 females) and a mean final follow up of 27.9 months were enrolled. 21 patients had L3, 8 had L4 and 5 had L5 burst fractures. 10 patients were managed conservatively by brace and 24 underwent surgical intervention. The pain score (VAS) improved from a mean of 8.5 at the time of injury to a mean of 1.6 at final follow up. Patients with neurological injury had on average improvement of one Frankel grade. 88% patients had excellent to good final functional outcome.

**Conclusion:** Lower lumbar burst fractures are high velocity injuries with other non-spinal injuries being associated. Most of the patients have good functional outcome with both conservative as well as surgical intervention. Patients with complete cauda equina have poor outcome with respect to neurological recovery.

**Keywords:** Burst fracture, Frankel Grade, cauda-equina syndrome, pedicle screws, thoracolumbosacral orthosis

### 1. Introduction

Burst fracture is a type of vertebral fracture which involves both the anterior and middle column of the spine with varying degree of retropulsion of the bony fragment(s) in the spinal canal [1, 2].

Burst fractures most commonly affect thoracolumbar junction. Burst fractures involving lower lumbar spine are rare accounting for 1 to 4% of all the spine fractures [3, 4]. Besides, lower lumbar spine fractures are unique with respect to anatomy, biomechanics and neurology [5]. Strong iliolumbar ligaments and presence below the pelvic brim give additional stabilization to this part of the spine as compared to thoracolumbar spine [6].

Due to physiological lordosis in lower lumbar spine, axial compression forces produce a uniform compression of vertebral body with lesser chances of anterior collapse after treatment and subsequent kyphotic deformity, which is different from thoracolumbar junction injuries where axial compression produces more compression anteriorly due to physiological kyphosis [1, 2, 6, 7].

Widest spinal canal and presence of only nerve roots makes neurological involvement less common than in the thoracolumbar region fractures [8] Since nerve roots of the cauda equina carry lower motor neurons, injury to these behaves like peripheral nerve injuries [9, 10].

With respect to thoracolumbar injuries there are definitive classification systems and guidelines about the management. But with lower lumbar spine fractures, the literature is limited and there are no well defined classification systems and management protocols [11]. Here we present the functional outcomes of burst fractures of lower three lumbar segments that had been managed by different well documented and known modalities at two different tertiary care centres.

**Correspondence**  
**Dr. Tarsem Motten**  
Lecturer, SKIMS Medical College  
Bemina, Srinagar, Jammu and  
Kashmir, India

**2. Material and methods**

This prospective study was conducted at two tertiary care centres over a period of nine years from January 2008 to December 2016. The study included all the subjects who had traumatic burst fracture of any of the lower three lumbar vertebrae (L-3 to L-5) and were of the age of 18 years or above but less than 65 years. Patients with pathological fractures or multiple level spine fractures or those who had follow up of less than 24 months were excluded.

Patient’s age, sex, mode of injury, level of burst fracture and associated injuries were recorded. Complete neurological examination of each case was done and neurological injury was graded according to Frankel Grading System. The local pain was graduated as per visual analogue scale (VAS). The type of intervention that was performed was recorded. Complications, if any, were documented. At the final follow up the neurological status was graded again as per Frankel Grading System and local pain by VAS. Frankel grade and VAS at the time of injury and final follow up were compared. The final functional results were graded as per Smiley-Webster Scale, based on occupational status before injury and at the final follow-up (Table I).

The data collected was analysed using Statistical Package for the Social Sciences (SPSS) software and results expressed as

mean ± SD. For statistical analysis ANOVA test was used to compare the outcome between non-operative and operative group. A p-value less than 0.05 is considered statistically significant and a value less than 0.01 is highly significant.

**Table 1:** Smiley-Webster Functional Scale

Excellent	Complete recovery with return to previous work and activities.
Good	Occasional leg and or back pain; occasional use of bracing, but return to previous work and activities.
Fair	Recovery incomplete (partial); needs permanent support and change or modification of work and activities.
Poor	No recovery; cannot return to work.

**3. Results**

A total of 34 patients (24 males and 10 females), with an average age of 37.3 ± 12.1 years (range: 19 to 60 years) were enrolled for the study. There were 21 patients with L3 burst fractures, 8 with L4 burst fractures and 5 with L5 burst fractures. Fall from height was the most common mode of injury seen in 23 patients followed by road traffic accident in 10 patients. Fall of heavy weight on back was mode of trauma in one patient (Table II).

**Table 2:** Demographic profile, mode of trauma, pain score, Frankel grade of neurological status, mode of treatment and final functional outcome of the study population.

S. No	Age(yrs)/ Sex	Level	MOI	Neurological Injury (Frankel Grade)	Initial VAS	Treatment	Final Follow up (months)	Neurological Status Final F/U (Frankel Grade)	VAS (final F/U)	Final Outcome (Smiley-Webster)
1.	44/ M	L-3	FHW	E	9	Brace	26	E	1	Excellent
2.	30/M	L-3	RTA	A	9	Decomp, Cage recon. and PSS L2-L4	28	D	1	Good
3.	20/ M	L-3	RTA	C	9	Decomp, Post Fusion, PSS L2-L4	25	D	3	Fair
4.	36/ M	L-3	RTA	E	8	PSS L2-L4	24	E	1	Excellent
5.	51/ M	L-5	RTA	E	7	Brace	24	E	2	Excellent
6.	45/ M	L-3	FFH	E	7	PSS L2-L4	26	E	1	Excellent
7.	35/ F	L-3	FFH	E	10	PSS L2-L4	25	E	2	Excellent
8.	21/ M	L-4	FFH	E	8	PSS L3-L5	29	E	1	Excellent
9.	24/ M	L-4	FFH	E	9	PSS L3-L5	26	E	2	Excellent
10.	31/ F	L-3	FFH	A	10	PSS L2-L4	31	A	3	Poor
11.	55/ F	L-4	FFH	E	9	Brace	24	E	1	Excellent
12.	49/ M	L-3	FFH	E	9	PSS L2-L4	35	E	1	Excellent
13.	43/ M	L-4	FFH	E	10	Decomp. cage recon, PSS L3-L5	32	E	1	Excellent
14.	60/ M	L-3	FFH	E	7	PSS L2-L4	29	E	1	Excellent
15.	26/ F	L-4	FFH	C	8	PSS L3-L5	27	D	3	Fair
16.	48/ M	L-4	FFH	D	8	PSS L3-L5	25	E	1	Good
17.	33/ M	L-3	RTA	C	9	PSS L1-L5 (long seg.)	28	E	3	Excellent
18.	27/ M	L-3	FFH	E	10	Decomp. cage recon, PSS L2-L4	26	E	2	Excellent
19.	49/ M	L-3	FFH	D	10	PSS L1-L4 (long seg.)	38	E	3	Good
20.	51/ F	L-3	FFH	E	7	Brace	26	E	0	Excellent
21.	52/ F	L-5	FFH	E	8	Brace	25	E	1	Excellent
22.	59/ M	L-3	FFH	E	9	Brace	33	E	0	Excellent
23.	37/ M	L-3	FFH	E	7	Brace	24	E	2	Excellent
24.	22/ M	L-3	RTA	E	9	Decomp. cage recon, PSS L2-L4	24	E	1	Excellent
25.	42/ M	L-4	FFH	E	7	Brace	25	E	2	Excellent
26.	35/ M	L-3	FFH	E	8	Brace	24	E	1	Excellent
27.	19/ F	L-5	RTA	E	7	PSS L4-S1	39	E	2	Excellent
28.	32/ F	L-3	FFH	A	9	PSS L2-L4	29	A	3	Poor
29.	23/ F	L-3	FFH	C	9	Decomp. cage recon, PSS L2-L4	27	D	2	Good
30.	36/ M	L-3	RTA	C	9	Decomp. cage recon, PSS L2-L4	24	E	1	Excellent
31.	33/ F	L-5	RTA	D	10	PSS L4-S1	27	E	3	Good
32.	25/ M	L-5	FFH	E	8	PSS L4-S1	36	E	1	Excellent
33.	24/ M	L-4	RTA	D	8	PSS L3-L5	32	E	2	Excellent
34.	50/ M	L-3	FFH	E	7	Brace	24	E	0	Excellent

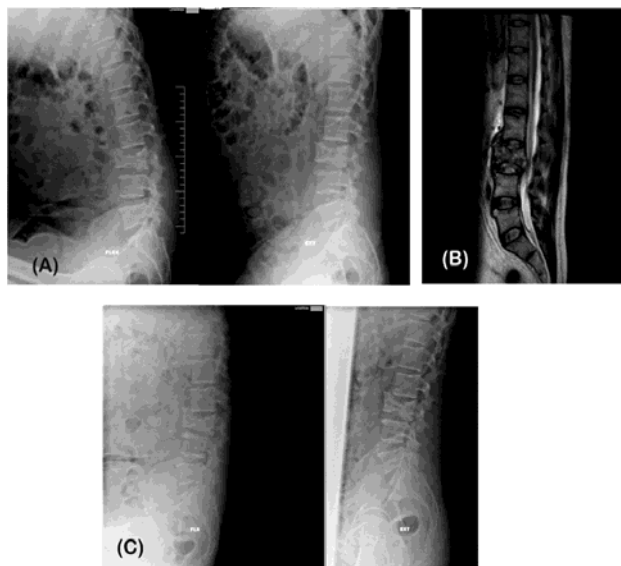
Ten patients had associated injuries of the other systems. Calcaneal fracture was the most common associated orthopaedic trauma (n = 3). One patient had bilateral calcaneal fractures and two had unilateral. One patient with unilateral calcaneal fracture had a talo-navicular dislocation in the contralateral foot. One patient had a proximal tibial fracture and one had distal radius fracture. Two patients had abdominal injuries (sigmoid perforation and splenic laceration) and both were associated with seat belt injuries.

Two patients had closed head injuries and one patient had chest trauma (multiple rib fractures with haemothorax). Twenty two patients had no neurological deficit. Among 12 patients with neurological deficit, 3 had complete cauda equina syndrome, 4 had incomplete cauda equina syndrome and 5 had isolated nerve root injuries. The neurological status was graded as per Frankel Grade (Table II; Table III). The local pain prior to any intervention and at final follow up was graduated as per VAS (Table II).

**Table 3:** Neurological status (Frankel Grade).

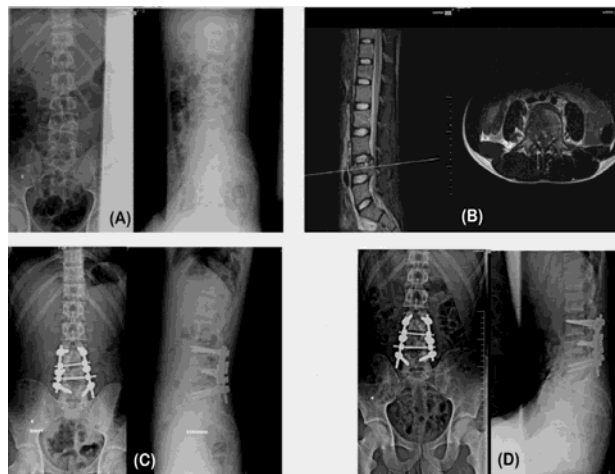
At the time of injury						
Frankel Grade	A	B	C	D	E	Total
L3 vertebra	3	-	4	1	13	21
L4 vertebra	-	-	1	2	5	8
L5 vertebra	-	-	-	1	4	5
Total	3	-	5	4	22	34
At final follow up						
L3 vertebra	2	-	-	3	16	21
L4 vertebra	-	-	-	1	7	8
L5 vertebra	-	-	-	-	5	5
Total	2	-	-	4	28	34

The mean pain score before any intervention, (conservative or surgical) was  $8.5 \pm 1.1$  (range of 7 to 10) on VAS. Ten patients were managed conservatively by a brief period (1 to 5 days) of bed rest followed by immobilization in a brace (thoracolumbosacral orthosis) for a period of 10 to 12 weeks (Figure 1).



**Fig 1:** Forty-four year old male with burst fracture of L3 managed in a TLSO brace. A. Initial flexion and extension lateral view radiographs B. MRI sagittal section having thecal sac indentation. C. Final follow-up at 26 months showing healed fracture with maintenance of lumbar lordosis.

The remaining 24 patients were treated by surgical intervention which included indirect reduction with posterior pedicle screw fixation (n = 17), trans-pedicular decompression with mesh cage reconstruction and posterior pedicle screw instrumentation (n = 6) and trans-pedicular decompression with posterior pedicle screw instrumentation and posterior fusion (n = 1) (Table II; Figure 2, Figure 3).

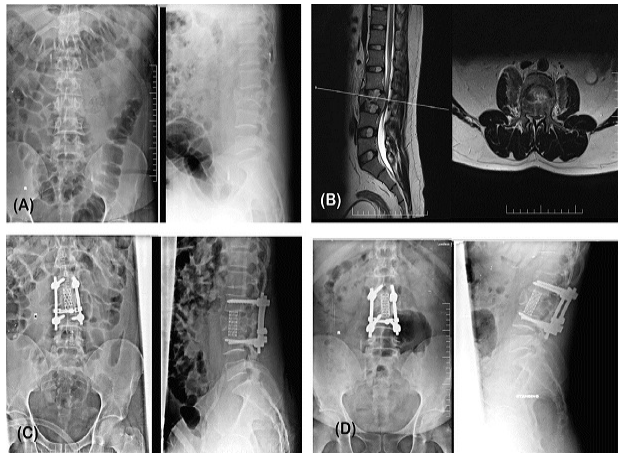


**Fig 2:** Twenty one year old male having burst fracture L4 managed by indirect decompression with short posterior pedicle screw fixation. A. Initial AP and lateral view radiographs of L/S spine. B. MRI sagittal and axial cuts having thecal sac indentation. C. Post-operative AP and lateral View. D. Final AP and lateral view radiographs at 29 months.

In all cases short segment pedicle screw fixation involving only three segments or vertebrae, including the fractured vertebra, was performed except for two cases of indirect decompression in which long segment pedicle screw fixation was used. All the surgically managed cases were approached posteriorly. Anterior approach was not performed in any of our cases.

The final follow up ranged from 24 to 39 months with an average follow up of  $27.9 \pm 4.3$  months. At the final follow up the average VAS was  $1.6 \pm 0.9$  (range of 0 to 3). The neurological status at final follow up as per Frankel Grade is elaborated in Table II and III. No patient with intact neurological status had any deterioration in the follow up period regardless of the treatment modality. The neurological status in patients with neuro deficit had improved by an average of 1.1 Frankel Grade except two patients of complete cauda equina, who did not show any improvement at final follow up. One patient with complete cauda equina recovered and had Frankel Grade of D at final follow up.

All the patients with isolated nerve root lesions had complete neurological recovery. Functional outcome at final follow up was graded as Excellent in 25 (73.5%), Good in 5 (14.7%), Fair in 2 (5.9%) and Poor in 2 (5.9%) patients (Table II). All the patients treated non-operatively had excellent results at the final follow up.



**Fig 3:** Twenty seven years old male with burst fracture L3 managed by posterior only approach (trans-pedicular decompression and mesh cage reconstruction) and pedicle screw fixation. A. Initial AP and lateral aspect L/S radiographs. B. MRI sagittal and axial cuts. C. Post-operative radiographs. D. Final follow up radiographs at 26 months.

#### 4. Discussion

Lower lumbar fractures are rare fractures with very few reports and series in the literature [15]. Most of the literature pertaining to burst fractures is on the thoracolumbar fractures which are more common and are usually associated with neurological injury and sagittal misalignment [11, 16]. And hence all the classification systems and guidelines for management are those for the thoracolumbar region. There is no classification system for lower lumbar fractures which are unique in anatomy, biomechanics and neurology and most spine surgeons use the Dennis classification system for these fractures as well [1, 5].

The lower lumbar spine is lordotic with its apex at L3 vertebra, is flexible in terms of flexion extension arc and in addition is protected by strong ligaments, muscles and the pelvic brim which make fractures at this level less common and even if they occur, high energy trauma is required and they are usually stable [6, 15, 16]. Motor vehicle trauma and fall from height constitutes most common mode of injury. 6 Falls were responsible for lower lumbar burst fractures in 61.8% patients in our study. Our 29.4% (n = 10) patients had associated injuries. Dai LY (2002) had associated injuries in 68.5%, which may be explained on the basis of higher incidence of vehicular crashes (44.4%) in their series. 1 Abdominal injuries of hollow and solid viscera, requiring laprotomy, have been associated with lumbar fractures in 80%. Green DA *et al* (1991) in their series of 16 patients with flexion distraction injuries of lumbar spine had half of their patients suffering from associated abdominal injuries and all were the result of vehicular trauma with seat belt in place [17, 18]. Our study had two cases with associated abdominal trauma and both were wearing seat belts at the time of vehicular accident. Non spinal skeletal injuries like fractures of calcaneum and tibia are commonly associated and must always be evaluated [15, 19]. In our series calcaneal fracture was the most common associated fracture.

The optimal treat of lower lumbar fractures is a point of debate with no clear cut guidelines on the indications for operative intervention. A general consensus is that spinal canal compromise more than 40%, kyphosis of more than 25°, loss of anterior vertebral height more than 50%, instability and presence of neurodeficit are indications for surgical intervention [15, 20, 21].

We have managed patients with canal compromise of more than 50% by bracing without any neurological deterioration and excellent results at the final follow up. One case of nerve root lesion in our series was managed by bracing and showed complete neurological recovery at follow up. Even good results have been seen in unstable lower lumbar fractures, managed by conservative treatment [22]. The aim of surgery in these fractures is decompression of the spinal canal with restoration of the anterior vertebral height and lumbar lordosis and stabilization involving minimal vertebral levels [15, 21, 23]. Fusion if required should also be restricted to minimal levels. Long segment stabilization and or fusion have been associated with flat back, implant failure and degeneration in adjacent segments [6, 22, 23, 24]. There is also controversy regarding surgical approach which can be anterior, posterior or combined. Anterior approach carries risk to the great vessels that lie in vicinity but has the advantage of direct access to the pathology and reconstruction of anterior and middle column of the spinal segment and is usually recommended in patients with severe grades of neurodeficits that requires carpectomy [15, 25, 26]. Some surgeons use a combined approach in which decompression is done by anterior approach and stabilization by posterior approach. Nowadays trend is a transpedicular decompression along with placement of the mesh cage and posterior pedicle screw stabilization via same posterior approach [27]. In our series all the cases have been operated by posterior approach only. No case has been approached anteriorly in our series.

Indirect reduction using pedicle screw system was done in our series by an open posterior approach in 17 patients. Nowadays this can be done by a percutaneous technique and we do not have any experience with these techniques [28, 29]. Short segment fixation is preferred in lower lumbar spine over long segment to preserve the motion segments [30]. Long segment stabilization was performed in only two cases in our series.

The pain score (VAS) in our series has improved from initial mean score of  $8.5 \pm 1.1$  to a mean of  $1.6 \pm 0.9$  at final follow up. Wang US *et al* (2013) in their series of 12 cases had improvement of mean VAS from 7.8 to 1.8 at final follow up which is comparable to that our study. 30 Mean VAS at final follow up in our series was 1 in the non-operative group and 1.8 in the operative group which is statistically significant (F-ratio value = 6.72; p-value = 0.014). Buttler JS *et al* (2007) in a series of 14 patients with L5 burst fractures had superior results at final follow up with regard to pain control in the cases managed conservatively [31].

Seybold EA *et al* (1999) in their multicentre study demonstrated no statistically significant difference in long term pain between operative and non-operative group. 6 Patients with long segment pedicle screw fixation have persistent local pain and more complications as compared to short segment instrumentation [22, 23, 24]. We had two patients with long segment posterior pedicle screw fixation and both had a pain score (VAS) of 3 at final follow up.

In our series 35.3% patients had a neurological loss at the time of injury which is comparable to 42.8% figures of a series by Seybold EA *et al* (1999). Half (n = 6) of the patients with neurological injury (n = 12) had recovered completely at

the final follow up. All the 5 patients with isolated nerve root lesions and one patient with incomplete cauda equine syndrome had complete neurological recovery. Patients with complete cauda equine syndrome did not have complete neurological recovery. Patients with neurological injury who have preserved anal tone and perineal sensations have a good prognosis of recovery<sup>[32]</sup>.

Andreychik *et al.* have found that isolated nerve root deficits at this level have good prognosis for spontaneous recovery with conservative treatment<sup>[33]</sup>. Dai LY *et al.* (2002) in their series had no significant difference in neurological recovery between operative and non-operative groups. They had better neurological recovery in incomplete lesions than complete lesions (Frankel grade A), irrespective of the modality of treatment, like that of our series. We could not compare the neurological recovery statistically between operative and non-operative groups in our series because most of the patients with neurological injury had received operative management (n = 11) while as only one such patient had been treated conservatively. This is the problem with most of the series in the literature, where neurological injuries associated with lower lumbar fractures are managed by decompression.

Overall, 88% patients with lower lumbar burst fractures in our series had excellent and good results as per Smiley-Webster functional scale. 11.8% (n = 4) patients could not return to their previous job or activity level and as a result 2 patients with fair results required change of job and daily activities and 2 patients with poor score had to leave their previous job.

## 5. Conclusion

Lower lumbar burst fractures are rare spine fractures resulting from high velocity trauma and are associated with higher percentage of non-spinal injuries. These can be managed by both conservative as well as operative interventions. Non-operative modality has a significant better control of local pain on long term basis than operative modality. Short segment stabilization should be preferred over long segment fixation. Neurological recovery is better in incomplete neurological lesions than complete ones like complete cauda equina syndrome. Isolated nerve root lesions have best prognosis in terms of recovery. Most of the patients return to their original jobs and activity level with either form of management. So both modalities of treatment are viable options for management of these fractures.

Shortcoming of this study is that it is not a randomized prospective study and fractures with neurological injury were managed almost exclusively by surgical decompression. So the outcome of neurological injury managed by two modalities could not be compared.

## 6. References

- Dai LYLD. Low lumbar spinal fractures: management options. *Injury, Int J Care Injured.* 2002; 33:579-82.
- Ballock RT, Mackersie R, Abitbol JJ, Cervilla V, Resnick D, Garfin SR. Can burst fractures be predicted from plain radiographs? *J Bone Joint Surg Br.* 1992; 74:147-50.
- Formby PM, Wagner SC, Pisano AJ, Van Blarcum GS, Kang DG, Lehman RA. Outcomes After Operative Management of Combat-Related Low Lumbar Burst Fractures. *Spine.* 2015; 40:E1019-E1024.
- Levine MA, Edwards CC. Low lumbar burst fractures: reduction and stabilization using modular spine fixation system. *Orthopedics.* 1988; 11:1427-32.
- Panjabi MM, Oxland TR, Lin RM, McGowen TW. Thoracolumbar burst fractures: A biomechanical investigation of its multidirectional flexibility. *Spine* 1994; 19:578-85.
- Seybold EA, Sweeney CA, Fredrickson BE, Warhold LG, Bernini PM. Functional Outcome of Low Lumbar Burst Fractures. A multicentre Review of Operative and Nonoperative Treatment of L3-L5. *Spine.* 1999; 24:2154-61.
- An HS, Simpson MJ, Ebraheim NA, Jackson WT, Moore J, O'Malley NP. Low lumbar burst fractures: Comparison between conservative and surgical treatments. *Orthopedics,* 1992; 15:367-73.
- Chan DP, Seng NK, Kaan KT. Nonoperative treatment in burst fractures of the lumbar spine (L2-L5) without neurologic deficits. *Spine.* 1993; 18:320-25.
- Finn CA, Stauffer ES. Burst fractures of the fifth lumbar vertebra. *J Bone Joint Surg Am.* 1992; 74:398-403.
- Fredrickson BE, Yuan HA, Miller H. Burst fractures of the fifth lumbar vertebra. *J Bone Joint Surg Am.* 1982; 64:1088-94.
- Bhandutia AK, Gruskay JA, Helgeson MD, Yadlapalli NK, Gowda AL, Su BW *et al.* Treatments and Outcomes for Lower Lumbar (L3-L5) Burst Fractures. A Systematic Review. *Contemp Spine J.* 2011; 12(4):1-8.
- Frankel HL, Hancock DO, Hyslop G, Melzak J, Michaelis LS, Yngar GH *et al.* The value of postural reduction in the initial management of closed injuries of the spine with paraplegia and tetraplegia. *Paraplegia.* 1969; 7(1):179-92.
- Wallerstein SL. Scaling clinical pain and pain relief. In: Bromm B, ed. *Pain measurement in man: neurophysiological correlates of pain.* New York: Elsevier, 1984.
- Ozturk C, Ersozlu S, Aydinli U. Importance of greenstick lamina fractures in low lumbar burst fractures. *Int Orthop,* 2006; 30:295-8.
- Sansur CA, Shaffrey CI. Diagnosis and Management of Low Lumbar Burst Fractures. *Semin Spine Surg,* 2010; 22:33-7.
- McAfee PC, Yuan HA, Lasda NA. The unstable burst fracture. *Spine.* 1982; 7:365-73.
- Green DA, Green NE, Spengler DM, Devito DP. Flexion-Distractor Injuries to the Lumbar Spine Associated with Abdominal Injuries. *J Spinal Disord.* 1991; 4(3):312-8.
- Smith WS, Kaufer H. Patterns and mechanisms of lumbar injuries associated with lap type seat belts. *J Bone Joint Surg Am.* 1969; 51:239-54.
- Wasnich RD, Davis JW, Ross PD. Spine fracture risk is predicted by non-spine fractures. *Osteoporos Int.* 1994; 4:1-5.
- Kostuik JP. Anterior fixation for burst fractures of the thoracic and lumbar spine with or without neurological involvement. *Spine.* 1988; 13:286-93.
- Mikles MR, Stchur RP, Graziano GP. Posterior instrumentation for thoracolumbar fractures. *J Am Acad Orthop Surg.* 2004; 12:424-35.
- Chan DP, Seng NK, Kaan K. Non operative treatment in burst fractures of the lumbar spine (L2-L5) without neurologic deficits. *Spine.* 1993; 18:320-5.
- Wiggins GC, Ondra SL, Shaffrey CI. Management of iatrogenic flatback syndrome. *Neurosurg Focus.* 2003; 15:E8.
- Court-Brown CM, Gertzbein SD. The management of burst fractures of the fifth lumbar vertebra. *Spine.* 1987;

- 2:308-12.
25. Oprel PP, Tuinebreijer WE, Patka P, den Hartog D. Combined anterior–posterior surgery versus posterior surgery for thoracolumbar burst fractures: a systematic review of the literature. *Open Orthop J.* 2010; 4:93-100.
  26. Khare GN, Kockhar VL, Lal Y. Chance's fracture of the fourth lumbar vertebra. *Injury.* 1989; 20(5):303-4.
  27. Zhang JW, Xiao BP, Xu RM, Zhao LJ, Ma WH, Ruan YP. Analysis of safety and effect of reconstructing anterior and middle columns by single posterior approach in treating lumbar burst fractures. *Chin J Traumatol.* 2009; 12:107-12.
  28. Foley KT, Gupta SK. Percutaneous pedicle screw fixation of the lumbar spine: preliminary clinical results. *J Neurosurg Spine.* 2002; 97:7-12.
  29. Gahr RH, Strasser S, Strasser E, Schmidt OI. Percutaneous internal fixation of thoracolumbar spine fractures. *Top Spinal Cord Inj Rehabil.* 2006; 12:45-54.
  30. Wang US, Ju C, Kim SW, Wang HS, Lee SM. Short Segment Screw Fixation without Fusion for Low Lumbar Burst Fracture: Severe Canal Compromise but Neurologically Intact Cases. *Korean J neurotrauma.* 2013; 9:101-5.
  31. Butler JS, Fitzpatrick P, Ni Mhaolain AM, Synnott K, O'Byrne JM. The management and functional outcome of isolated burst fractures of the fifth lumbar vertebra. *Spine,* 2007; 32:443-7.
  32. Taylor TK, Coolican MJ. Injuries of the conus medullaris. *Paraplegia.* 1988; 26:393-400.
  33. Andrychik D, Aander D, Senika K, Stauffer S. Burst fractures of the 2nd through 5th lumbar vertebrae. *J Bone Surg Am.* 1996; 78:1156-66.