International Journal of Orthopaedics Sciences

ISSN: 2395-1958
IJOS 2016; 2(4): 150-153

www.orthopaper.com
Received: 25-08-2016
Accepted: 26-09-2016

Dr. Pramod G
Consultant, Orthopedician, Chikkaballapura, Karnataka, India

Dr. Vijayakumar AV
Assistant Professor, AJ Shetty Medical College, Mangalore, Karnataka, India

Correspondence
Dr. Vijayakumar AV
Assistant Professor, AJ Shetty Medical College, Mangalore, Karnataka, India

Evaluation of the results of locking compression plate in the treatment of fractures lower end of femur

Dr. Pramod G and Dr. Vijayakumar AV

DOI: http://dx.doi.org/10.22271/ortho.2016.v2.i4c.25

Abstract
Elderly patients with severe osteoporosis add further to the difficulties in management of fractures around knee which requires restoration of articular congruency for painless free movements of joint. Loss of stable fixation in osteoporotic bones is of great concern in such elderly patients. Locking compression plates with its numerous advantages is of great use in such circumstances. In this study 20 patients with both open and closed fracture of distal femur were studied. All the cases were treated from 1st November 2012 to September 30th 2014 under the Department of Orthopaedics. In our study of 20 patients belonging to AO type A and C of distal femur fractures, four patients belonged to A2, five patients to A3, one to C1, five to C2 and five to C3 type fractures respectively. Majority of fractures belonged to type C fracture which was 55% and remaining 45% belonged to type A fractures. This indicates that type C fractures occur more commonly than type A. From our study we conclude that DF-LCP, the "internal fixator" is a safe and reliable implant although careful preoperative planning and case selection are important factors which determine the final outcome.

Keywords: Locking compression plate, femur fracture, DF-LCP

Introduction

In the last few decades, rapid industrialization and the fast pace of life have brought alike both comforts and catastrophe like high velocity road traffic accidents, crippling many young lives. Fractures of the distal femur constitute a heterogenous group of injuries affecting knee. High energy injuries tend to occur in young males, whereas low energy injuries commonly occur in elderly females. Fracture lower end of femur and upper end of tibia are often difficult to treat and they are associated with many complications. These fractures have got wide variety of fracture patterns and they are commonly associated with injuries such as open wounds, patellar fractures and ligament disruption. These serious injuries have the potential to produce significant long-term disability especially when they are associated with extensive articular cartilage damage, marked bone comminution, and severe soft tissue injury.

In the early 1960s, there was a great reluctance towards operative management of these fractures because of high incidence of infection, non-union, malunion, inadequate fixation and lack of proper instruments, implant as well as antibiotics. Then, the traditional management of displaced fracture supracondylar of femur was along the principle of Watson Jones [1] & John Charnley [2]. This comprised of skeletal traction, manipulation of fracture and external immobilization in the form of casts and cast bracings. These methods however, met with problems like deformity, shortening, prolonged bed rest, knee stiffness, angulation, joint incongruity, malunion, quadriceps wasting, knee instability and post-traumatic osteoarthritis.

The trend of open reduction and internal fixation has become evident in the recent years with good results being obtained with the AO blade plate, dynamic condylar screw, intramedullary supracondylar nail & other implant system like locking compression plates.

Elderly patients with severe osteoporosis add further to the difficulties in management of fractures around knee which requires restoration of articular congruency for painless free movements of joint. Loss of stable fixation in osteoporotic bones is of great concern in such elderly patients. Locking compression plates with its numerous advantages is of great use in such circumstances [3].

Methodology

In this study 20 patients with both open and closed fracture of distal femur were studied. All the cases were treated from 1st November 2012 to September 30th 2014 under the Department of Orthopaedics.

The following protocol was observed for patients with fracture lower end of femur

1. General and systemic examination as well as local examination of the patient.
2. Thorough examination of patient to rule out head/ chest/ abdominal/spinal or pelvic injury.
3. Evaluation of patients in terms of:

a. Age
b. Sex
c. Mode of trauma
d. Period between injury and arrival.

4. Musculo-skeletal examination of patient to rule out associated fractures
5. Stabilization of patient with intravenous fluids, oxygen and blood transfusion as and when required.
6. Careful assessment of injured limb as regards to neurovascular status.
7. Primary immobilization of involved limb in Thomas splint with a Cotton pad below the distal fragment
8. Radiological assessment: Anteroposterior and true lateral views of injured whole femur to whole leg to rule out other injuries.

Inclusion criteria

1. Patients with lower third femoral fractures aged 20 years and above.
2. Patients willing for treatment and given informed written consent.

Exclusion criteria

1. Patients with pathological fractures of lower third of femur other than osteoporosis.
2. Patients below 20yrs of age
3. Patients not willing for treatment.
4. Patients managed conservatively for other medical reasons.
5. Lower third femoral fractures with neurovascular deficit.

Implant Used

- The plate and screws are manufactured from 316L stainless alloy with gun drilling technique
- • The locking compression plates are available from 5 holed to 16 holed. With 4.5 mm thickness plate for lower end of femur.
- Anatomically precontoured plate head with soft edges
- •. Locking screws in the head of the plate for a secure support.
- The head of the locking screw is threaded which gets locked to the plate as it is tightened
- LCP combi-holes in the plate shaft – Intraoperative choice between angular stability and/or compression.

Results

Table 1: Gender Distribution

Sex	Number of Cases	Percentage
Male	17	85%
Female	3	15%
Total	20	100%

Table 2: Age Distribution

Age in Yrs	Number of Cases	Percentage
21-30	7	35%
31-40	6	30%
	3	15%
51-60	2	10%
>60	2	10%
Total	20	100%

Table 3: Mechanism of injury

Mechanism of Injury	Number of Cases	Percentage
RTA	15	75%
Self-Fall	5	25%
TOTAL	20	100%

Table 4: Supracondylar fracture

Supracondylar Fracture	Number of Cases	Percentage
Muller's A1	0	0%
Muller's A2	4	20%
Muller's A3	5	25%
Muller's B1	0	0%
Muller's B2	0	0%
Muller's B3	0	0%
Muller's C1	1	5%
Muller's C2	5	25%
Muller's C3	5	25%
Total	20	100%

Table 5: Plate size

Plate Size	Number of Cases	Percentage
4-6 Holed	8	40%
7-9 Holed	8	40%
9-12 Holed	4	20%
>12 Holed	0	0%
Total	20	100%

Table 6: Union in Weeks

Union in Weeks	Number of Cases	Percentage
<16 Weeks	0	0%
16-18 Weeks	13	65%
19-20 Weeks	7	35%
21-22 Weeks	0	0%
Delayed-Union	0	0%
Non-Union	0	0%
Total	20	100%

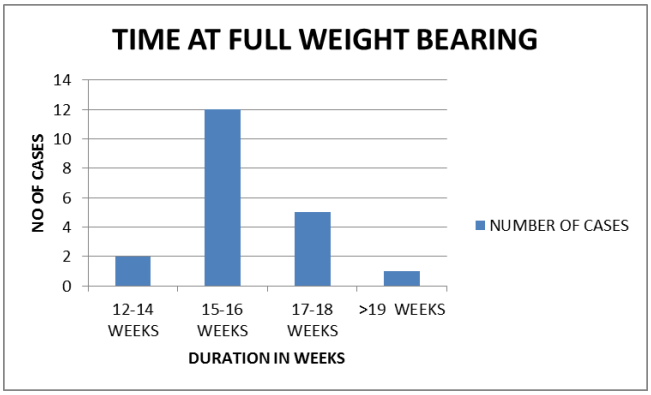

Fig 1: Time at full weight bearing

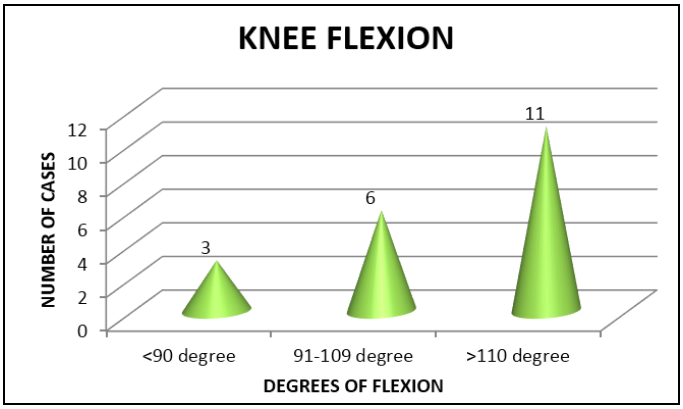

Fig 2: Knee flexion

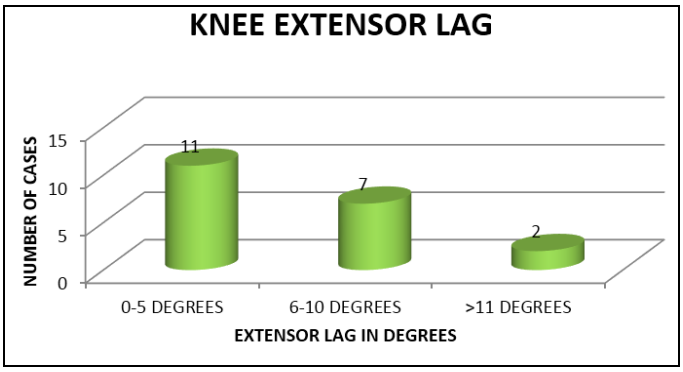

Fig 3: Knee extension

Table 7: Outcome

Functional Results	Number of Cases	Percentage
Excellent	12	60%
Good	6	30%
Fair	2	10%
Poor	0	0%
Total	20	100%

Discussion

Fractures in the distal femur have posed considerable therapeutic challenges throughout the history of fracture treatment. Most of these surgical failures were due to inadequate fixation of the fracture fragments (Mize *et al* 1982) [4]. The prognostic factors for supracondylar fracture included age, intra-articular involvement, methods of treatment, timing of joint motion, etc (Neer *et al* 1967; Morre1987) [5, 6].

The Locking Compression Plate (LCP) system offers a number of advantages in fracture fixation combining angular stability through the use of locking screws with traditional fixation techniques. However, the system is complex, requiring careful attention to biomechanical principles and good surgical technique. The 'angular stability' provided by LCP at the plate-screw interface, allows extra-periosteal fixation of the plate to the bone. By preserving periosteal blood supply to the bone it adresses the importance of the biological factors involved in fracture healing. The principles offlexible fixation are employed where the goal is for indirect healing with the formation of callus. Although the LCP system offers a number of advantages in fracture management, its successful use requires careful pre-operative planning, consideration of biomechanical principles, and the use of the appropriate plate and screws combined with good surgical technique. Failure to address these issues can lead to potential pitfalls in terms of implant breakage or non-union. LCP is a single beam construct where the strength of its fixation is equal to the sum of all screw-bone interfaces rather than a single screw's axial stiffness and pullout resistance in unlocked plates [48]. Its unique biomechanical function is based on splinting rather than compression resulting in flexible stabilisation, avoidance of stress shielding and induction of callus formation [7].

The DF-LCP is a further development from the LISS, which was introduced in the mid to late 1990's [8]. The main difference between the DF- LCP and the LISS is that the LISS utilises an outrigger device for shaft holes, functioning essentially as a locking guide jig, which is attached to the distal part of the plate and guides the placement of the proximal locking screws. Whereas the shaft holes on the DF-LCP are oval allowing for the options of a compression screw or a locking screw.

This leads to a more precise placement of the plate, as it is able to be compressed more closely to the bone. In our study of 20 patients the mean age of the patients was 45years and there were 17 males (85%) and 3 females (15%). The present study does not show a biphasic age distribution of the patient population as seen in studies (Bell *et al*, 1992) [9]. This is a reflection of the mechanism of injury which was high energy trauma in 70% of our patients of which most of whom were younger. The reason being that, in male patients there was more outdoor activities, so they were more prone to vehicular accident and majority females being house wives were less exposed to road traffic accidents.

Likewise, Yeap and Deepak [10], conducted a retrospective review of 11 patients who were fixed with Titanium Distal femur locking compression plate and reported higher incidence in males compared to females and the mean age in their study was 44 years. Mongkon Luechoowong [11], analysed retrospectively medical records of 19 patients who underwent LCP plating for complex distal femoral fractures and reported higher incidence in males than females and the mean age in the study was 41.6 years. Yang Teng-heng *et al* [12], studied retrospectively clinical data of 35 patients with distal femur fractures treated with locking compression plate and reported higher incidence in males than females and a mean age of 38 years.

In our study most of the injuries were caused by road traffic accidents affecting mostly males. We had 15 (75%) RTA injuries and 5 (25%) Falls. There were no sports or industrial accidents. Yeap and Deepak [13], reported higher incidence of RTA (7 patients) than Falls (3 patients).

In our study of 20 patients belonging to AO type A and C of distal femur fractures, four patients belonged to A2, five patients to A3, one to C1, five to C2 and five to C3 type fractures respectively. Majority of fractures belonged to type C fracture which was 55% and remaining 45% belonged to type A fractures. This indicates that type C fractures occur more commonly than type A. Yeap and Deepak [10], reported 4 patients of A1, 2 of A3, 1 of C1, 1 0f C2 and 3 of C3 type fractures. Yang Teng-Heng *et al* [12], reported 8 patients of A1, 5 of A2, 5 of A3, 4 of B2, 5 of C1, 3 of C2 and 5 of C3 type fractures. High energy trauma is one of the major contributory factor for C type distal femoral fractures. They are associated with severe comminution and are unstable.

The average time interval between injury and surgery in our study was 7 days with a range of 2 – 8 days. No significant change in results were obtained even though when the surgery was done at 8th day. In a study by Seinshiemer [13] there is a positive correlation between time delay and final outcome. According to them surgery should be conducted preferably within a week. Yeap and Deepak [10] reported average number of days from injury to surgery as 9.9 days with a range of 4 to 19 days.

In our study, associated injuries were present in 20% of patients. One patient had ipsilateral tibial shaft fracture, one ipsilateral proximal tibia fracture, one ipsilateral patella fracture, one ipsilateral superior pubic rami fracture which delayed the rehabilitation & increased the duration of stay at hospital. Yeap and Deepak [10] reported one patient who sustained multiple fractures including lung injury which required ventilation. Therefore, associated injuries play a role in the course of treatment and rehabilitation of the distal femoral fractures. Average duration of hospitalization in our study was 19 days, increased because of other associated injuries and the need for the strict postoperative physiotherapy which affected the course of treatment and rehabilitation. The majority of patients preferred to stay in hospital till the sutures were removed due to social reasons. Yeap and Deepak [10], reported average duration of hospitalisation of 17.2 days with a range of 8 to 34 days.

The average time to union was 4 months (16 weeks) in our study. Successful fracture union was defined as complete bridging callus in three cortices, together with painless full weight bearing. Radiological union of the fracture i.e. characterized by cortex to cortex healing and bridging callus of the fracture in both AP and lateral views of follow up x-rays, was considered as satisfactory union. Time to union increased with increase in age of the patient. Time to union in Type C fractures generally was found to be longer compared to Type A fractures. Yeap and Deepak [10], reported average time to union to be 18 weeks with a range from 6weeks to 36 weeks excluding one patient. Mongkon Luechoowong [11], average time to union as 17 weeks with a range of 12–38 weeks. Kim KJ *et al* [14], reported mean time to union at postoperative 15 weeks with a range of 13–20 weeks. We conclude that time to union in distal femoral fractures are generally longer than usual fracture union due to high incidence of comminution and osteoporosis. Type C fractures took longer time to unite compared to Type A fractures.

Conclusion

The new fixation system offers many fixation possibilities and has proven its worth in complex fracture situations especially in extensive comminution of femoral condyles with intra-articular involvement and osteoporosis where other fixation devices are incompetent. The DF-LCP has shown excellent to satisfactory results in majority of intra articular fractures (AO type C). It may excellent to satisfactory results in majority of intra articular fractures (AO type C). It may substitute a conventional plate and screw system (compression method) in treatment of complex distal femoral fractures especially in osteoporotic bone. In addition MIPPO technique with minimum soft tissue handling lessens the chances of infection when compared to other conventional methods, but a great expertise with good skills is required for the same. However a more comprehensive study with longer follow up periods is essential to throw light into the advantages, complications & possible disadvantages of the use of LCP by MIPPO with special attention to long term outcomes.

References

1. Wilson JN. Watson Jone's: Fractures and Joint Injuries. 6th, 1982, 1003-070.
2. Charnley John. The closed treatment of common fractures. 3rd ed, 197-204.
3. Hugh Owen Thomas. Quoted by Rockwood CA, Green DP. Fractures in adult, 4th ed. 1996, 2, 1972-1993.
4. Mize RD, BucholzREetal, Surgical treatment of displaced comminuted fracture of distal end of femur. JBJS. 1982; 64-A(5):871-79.
5. Neer CS, Gratham SA, Shelton ML *et al*. Supracondylar fractures of adult femur. JBJS. 1967; 49-A:591-613.
6. Moore TJ, Watson T, Green SA *et al*. Complications of surgically treated supracondylar fractures of the femur. J Trauma. 1987; 27:402-406.
7. Markmiller M, Konrad G, Sudkamp N. Femur-LISS and distal femoral nail for fixation of distal femoral fractures: are there differences in outcome and complications? Clin Orthop Relat Res. 2004; (426):252-257.
8. Frigg R, Appenzeller A, Christensen R *et al*. The development of the distal femur Less Invasive Stabilization System (LISS). Injury. 2001; 32:SC24â€"SC31.
9. Bell KM, Johnstone AJ, Court-Brown CM, Hughes SPF. Primary knee arthroplasty for distal femoral fractures in elderly patients. J Bone Joint Surg. 1992; 74B:400-402.
10. Yeap EJ, Deepak AS. Distal Femoral Locking Compression Plate Fixation in Distal Femoral Fractures: Early Results. Malaysian Orthopaedic Journal, ISSN1985 253352. 2007; 1(1):12-17.
11. The Locking Compression Plate (LCP) for Distal Femoral Fractures; Mongkon Luechoowong; Buddhachinaraj Medical Journal, January-April 2008, 25(1).
12. YANG Teng-heng, ZHONG Zhi-nian, LAO Ji-yi *et al*. locking compression plate in the treatment of distal femur fractures. Jilin Medical Journal. 2011-13
13. Seinsheimer F. Fractures of the distal femur. Clin Orthop. 1980; 153:169-179.
14. Kim KJ, Lee SK, Choy WS, Kwon WC, Lee DH. Surgical Treatment of AO Type C Distal Femoral Fractures Using Locking Compression Plate (LCP-DF); J Korean Fract Soc. Korean. 2010; 23(1):20-25.