

ISSN: 2395-1958  
IJOS 2015; 1(1): 07-11  
© 2015 IJOS  
www.orthopaper.com  
Received: 12-12-2014  
Accepted: 15-02-2015

**Dr. S.K. Venkatesh Gupta**  
Professor and HOD,  
Department of Orthopaedics,  
Mamata Medical College,  
Khammam, Telangana State,  
India

**Dr. Veera Shekar Valiseti**  
Postgraduate,  
Department of Orthopaedics,  
Mamata Medical College,  
Khammam, Telangana State,  
India

## Comparative study between dynamic hip screw vs proximal femoral nailing in inter-trochanteric fractures of the femur in adults

**S.K. Venkatesh Gupta, Veera Shekar Valiseti**

### Abstract

Inter-trochanteric fractures account for approximately half of the hip fractures in elderly; out of this, more than 50% fractures are unstable. The dynamic hip screw (DHS) has gained widespread acceptance in the last two decade and is currently considered as the standard device for comparison of outcomes. The DHS has been shown to produce good results but complications are frequent, particularly in unstable inter-trochanteric fracture. The advantage of Proximal Femur Nailing fixation is that it provides a more biomechanically stable construct by reducing the distance between hip joint and implant. The goal of this study is to compare the clinical and radiographical results of the DHS and PFN for the treatment of Inter-trochanteric hip fractures (Load bearing vs Load shearing). In our study we included 400 inter-trochanteric fractures, out of which 240 are treated with DHS fixation and 160 are treated with PFN. All surgeries done on traction table and are followed up at regular intervals of 4 weeks, 8 weeks, 12 weeks, 6 months and annually thereafter. The functional results are assessed with Harris Hip Score and observed 37.5% excellent results in DHS group and 66.2% excellent results in PFN group. We observed no statistically significant difference between two groups in view of late & early complications and time to union. We observed significantly better outcomes in PFN group for unstable inter-trochanteric fractures and in unstable fractures reduction loss is significantly lower in PFN group. We observed total duration of surgery is significantly lower in PFN group. We concluded that PFN may be the better fixation device for most unstable inter-trochanteric fractures.

**Keywords:** Inter-trochanteric fractures, DHS, PFN

### 1. Introduction

Inter-trochanteric fractures account for approximately half of the hip fractures in elderly; out of this, more than 50% fractures are unstable [1, 2]. The goal of treatment of any inter-trochanteric fracture is to restore mobility safely and efficiently while minimizing the risk of medical complications and restore the patient to pre-operative status. The dynamic hip screw (DHS) has gained widespread acceptance in the last two decade and is currently considered as the standard device for comparison of outcomes. The DHS has been shown to produce good results but complications are frequent, particularly in unstable inter-trochanteric fracture. The advantage of Proximal Femur Nailing fixation is that it provides a more biomechanically stable construct by reducing the distance between hip joint and implant [4, 8]. The goal of this study is to compare the clinical and radiographical results of the DHS and PFN for the treatment of Inter-trochanteric hip fractures (Load bearing vs Load shearing).

### 2. Materials and Methods

400 Inter-trochanteric hip fractures, which were surgically treated between January 2012 and January 2014 at our institution.

The fractures were divided into two groups for analysis:

Group 1 (240 patients—240 hips): Fractures treated with DHS

Group 2 (160 patients-160 hips): fractures treated with PFN

### Correspondence

**Dr. S.K. Venkatesh Gupta**  
Professor and HOD,  
Department of Orthopaedics,  
Mamata Medical College,  
Khammam, Telangana State,  
India

**Table 1:** Study Groups

Study Group	Sex M/F (190/210)	Age range	Fracture Pattern		
			A1	A2	A3
DHS	112/128	72.4 (65-80)	120	60	30
PFN	72/88	70.2 (63-78)	20	60	80

According to AO/OTA classification <sup>[1, 10]</sup>.

A1 fractures are simple, two-part fractures,

A2 fractures have multiple fragments

A3 fractures includes reverse oblique and transverse fracture patterns

**3. Exclusion Criteria <sup>[9]</sup>**

Patients who had less than 2 years of follow-up

Bilateral fractures (spontaneous)

Pathological fractures

Fractures associated with polytrauma

Pre-existing femoral deformity <sup>[1, 5]</sup> preventing hip screw osteosynthesis or intra-medullary nailing and Sub-trochanteric fractures <sup>[1, 6, 9]</sup> or fractures extending 5 cm distal to the inferior border of the lesser trochanter were excluded from study group.

For each of the 400 inter-trochanteric hip fractures recorded

1. Sex,
2. Age at the time of fracture,
3. Fracture type (AO/OTA classification),
4. Total operative time (the time that closed reduction was started to the time that the wound sutured),
5. Time to union (radiographical confirmation), and
6. Complications (early and late).

The decision for the type of the operation was based on surgeon’s preference and availability of the implant. Prior to hip surgery, each patient was evaluated by the same trauma team. The overall time from injury to surgery averaged 3.2 days (range: 1–6 days). Steps were taken to ensure that every individual was in the best possible medical condition at the time of surgery. All surgeries were performed on the traction table following closed reduction confirmed with fluoroscopy on two different planes.

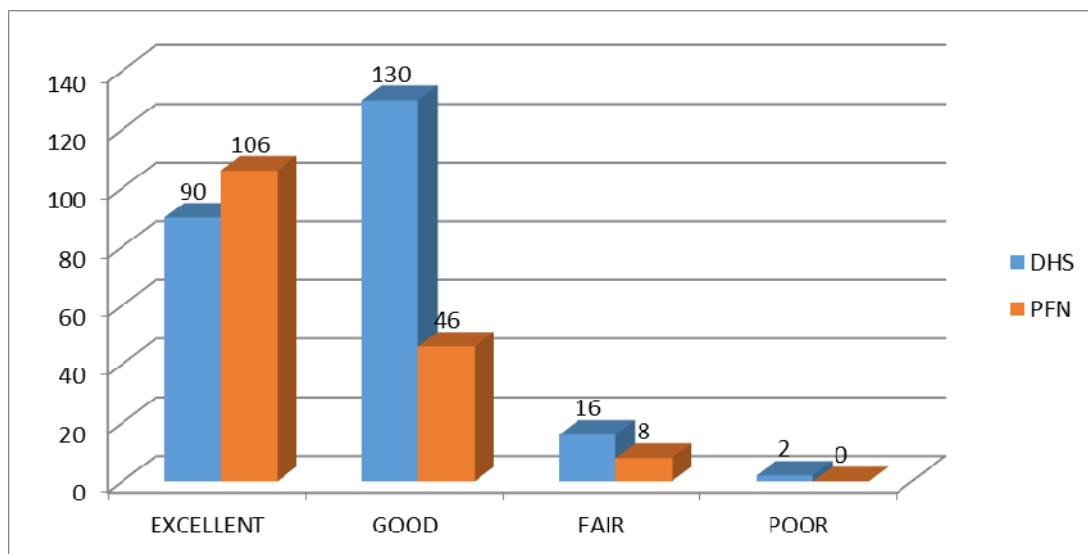
The clinical outcome for each group was analyzed, and intra

operative, early (within first month after hip fracture repair), and late complications (after first month) were recorded. Patients followed up at regular intervals of 4 weeks, 8 week, 12 weeks, 6 months and annually thereafter. Their functional outcome assessed with Harris Hip Scores.

Parameters	Grading of Harris Hip Score	
Pain	<70 Points	- Poor
Limp		
Distance walked		
Support	70-79 Points	- Fair
Sitting		
Enter public transportation		
Stairs	80-89 Points	- Good
Put on shoes and socks		
Absence of deformity		
Range of motion	90-100 Points	- Excellent

**4. Results**

In this study, patients with excellent results are 130(37.5%) in group 1 and 106(66.2%) in group 2, patients with good results are 130(54.1%) in group 1 and 46(28.2%) in group 2, patients with fair results are 16(6.6%) in group 1 and 8(5%) in group 2 and patients poor results are 4(1.6%) in group 1 and no patient with poor results in group 2 (listed in graph.1). Early complications we noted are prolonged drainage, hematoma, superficial infection and deep vein thrombosis (listed in table. 1). Late complications we noted are reduction loss (FIG.1), non union, implant failure and late infection (listed in table.2). There was no z-effect or reverse z-effect noted in this study



**Graph 1:** Functional Results

**Table 2:** Early Complications

Early Comlications	Group 1	Group 2	Total
Prolonged Drainage	3	0	3
Hematoma	0	3	3
Suerficial Infection	3	0	3
Deep Veinthrombosis	2	2	4
Total	8	5	13

**Table 3:** Late Complications

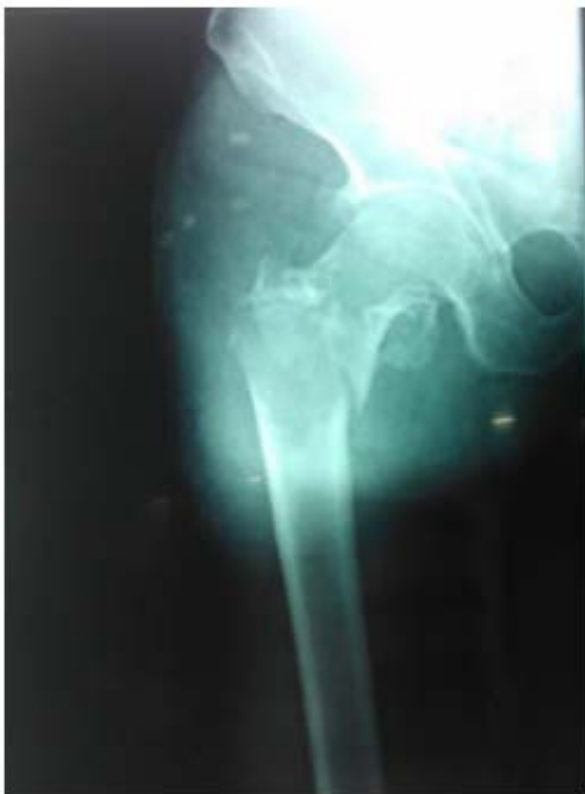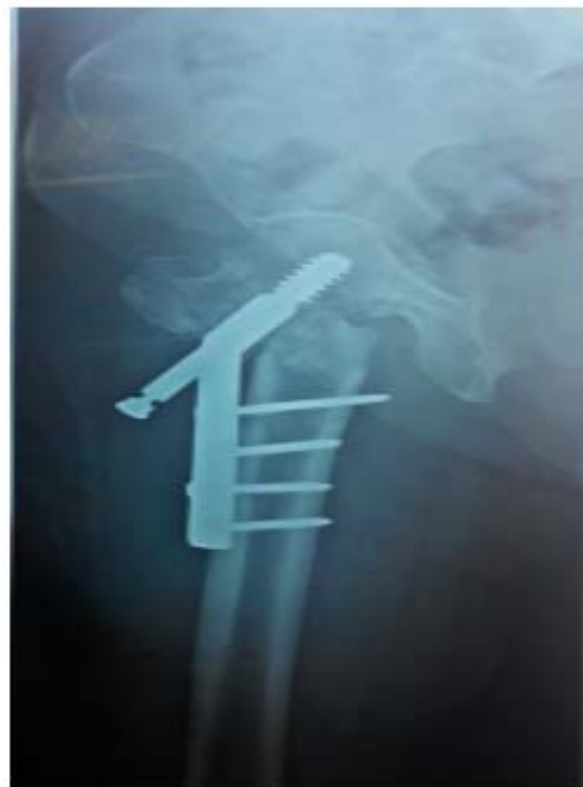Late mplications	Group 1	Group 2	Total
Reduction Loss	12	2	14
Nonunion	2	2	4
Impliant Failure	2	2	4
Late Infection	0	0	0
Total	16	6	22

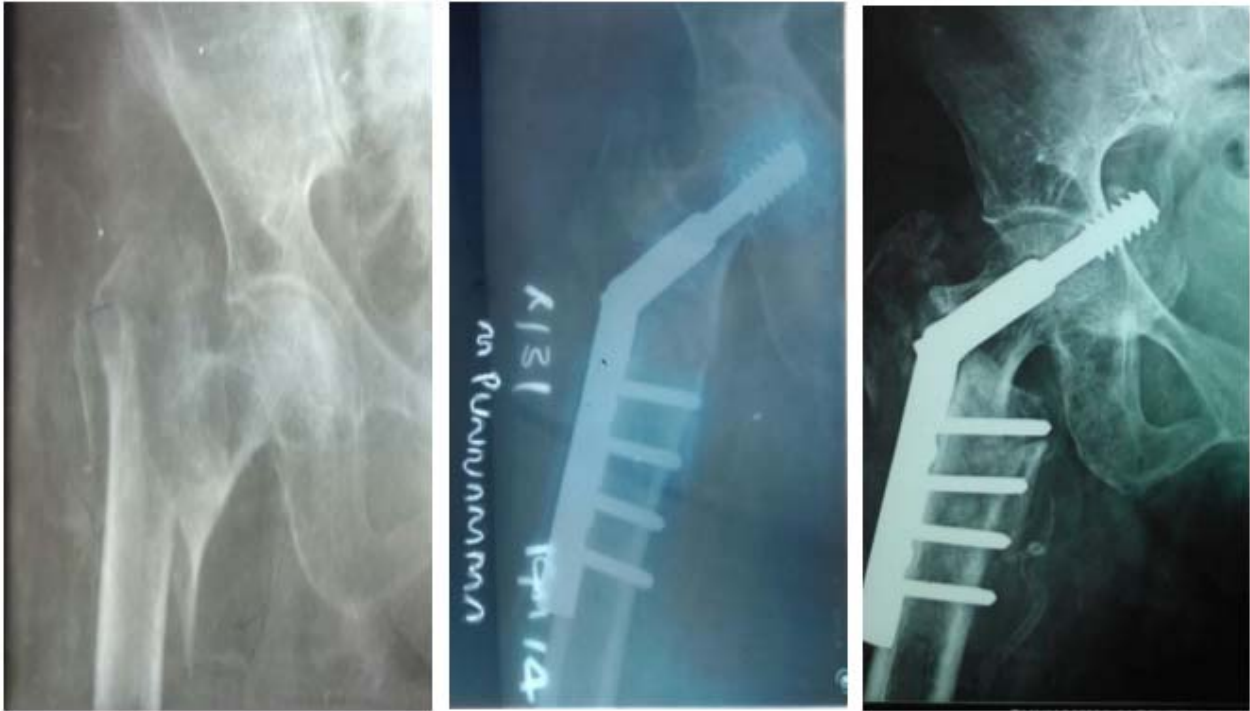### 5. Discussion

There was only one intra-operative complication in Group 1. A closed reduction could not be achieved, and open reduction was performed. There were three intra-operative complications in group 2. Two of them had a difficult closed reduction, and one had a difficult nail insertion. Here was no splintering of greater trochanter or femoral shaft in both groups. We observed one case with penetration of DHS screw into acetabulum (FIG.2) because of early complete weight bearing

against doctors advice.

A comparison of intra-operative, early and late complication rates revealed no statistically significant differences between study groups ( $P = 0.324$  for intra-operative complications,  $P = 0.223$  for early complications, and  $P = 0.357$  for late complications). A comparison of time to union demonstrated no statistically significant differences between study groups ( $P = 0.542$ ). The outcome of stable fractures treated with either DHS or PFN were similar, unstable inter-trochanteric fractures treated with PFN has significantly better outcomes with all having good results. Out of 30 A3 fractures in group 1, reduction loss occurred in 12 hips and in group 2 it is 2. In unstable fractures reduction loss is significantly lower in group 2 than group 1 ( $p < 0.005$ ). Total duration of surgery was significantly lower in group 2 than it was in group 1 ( $p < 0.005$ ) (Graph.2)

**A.** Preoperative view**B.** 3 months followup**Fig 1:** DHS reduction loss because of early wright bearing

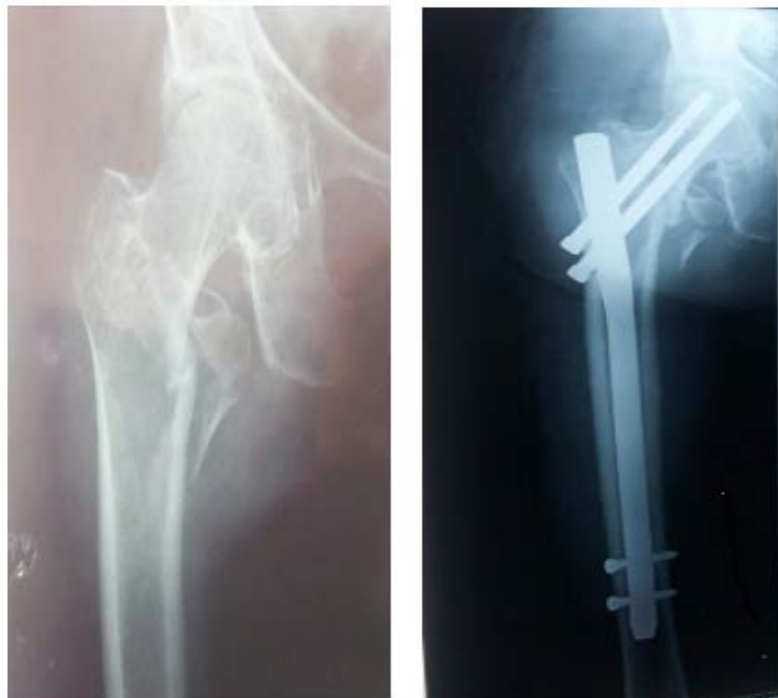

**Fig 2: A. PRE-OP X-RAY**

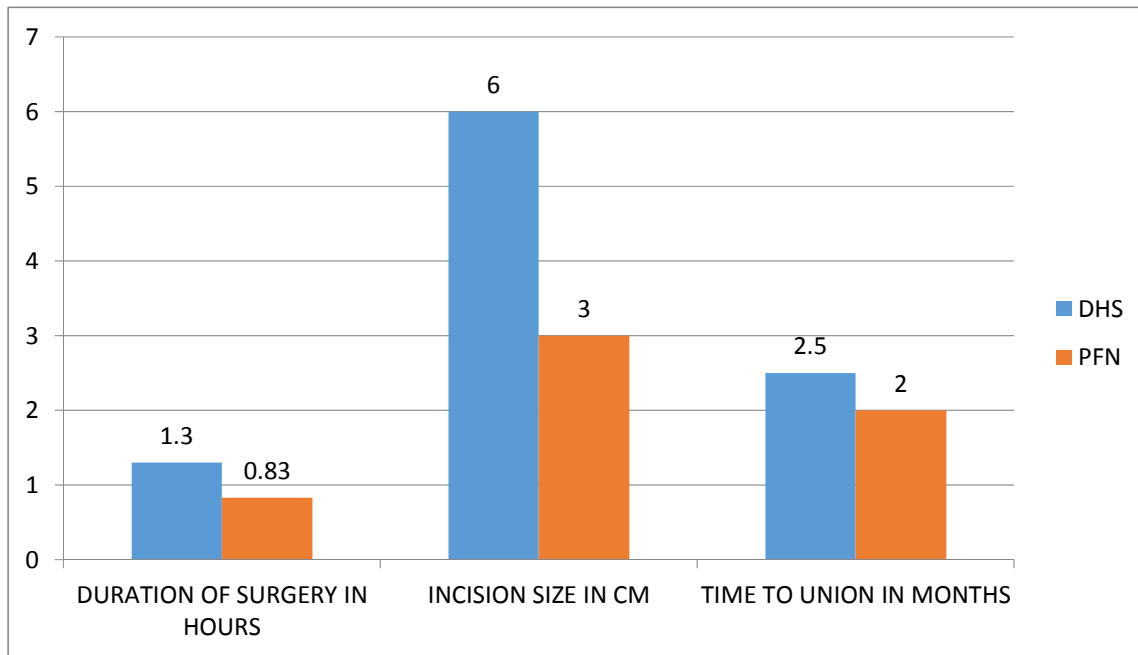
**B. IMMEDIATE POST-OP XRAY**

**C. AT 6 WEEKS**

Followup showing screw penetration into acetabulum (because of complete weight bearing walking against doctors advice)



**Fig 3: PFN FIXATION SHOWING PRE-OP X-RAY AND IMMEDIATE POST-OP X-RAY**



Graph 2.

## 6. Conclusion

Though PFN and DHS have similar outcomes in stable fractures, PFN has better functional outcome with unstable fractures. PFN requires shorter operation time and smaller incision; it has distinct advantages over DHS even in stable inter-trochanteric fractures. Hence from our study, PFN may be the better fixation device for most unstable inter-trochanteric fractures.

## 7. References

1. Robert BW, James Heckman D, Charles Court Brown M. Rockwood and Green's Fractures in Adults, 2(6), 1827-1844.
2. David Lavelle G. Fractures and dislocations of the hip chapter-52 in Cambell's Operative Orthopaedics, eleventh edition. Vol-3, 3237-3308.
3. David A, Von Der Heyde D, Pommer A. Therapeutic possibilities in trochanteric fractures". Orthopaede 2000; 29(4):294-301.
4. Kish B, Sapir O, Carmel A, Regev A, Masrawa S. Full weight bearing after unstable per and subtrochanteric fracture using proximal femur nail. J Bone Joint Surg (Br) 2001; 83-B, III, 289.
5. Christian B. The proximal femoral nail-a minimal invasive treatment of unstable proximal femoral fractures, Acta Orthop Scand 2003; 74(1):53-58.
6. Nuber S, Schoweiss T, Ruter A. Stabilization of unstable trochanteric femoral fractures: dynamic hip screw with trochanteric stabilization plate vs Proximal femoral nail Journal of orthopaedic trauma 2003; 17(4):316-317.
7. Ramakrishnan M, Prasad SS, Parkinson RW, Kaye JC. Management of subtrochanteric femoral fractures and metastases using long proximal femoral nail. Injury 2004; 35:184-190.
8. Ely Steinberg L, Nehemia Blumberg, Shmuel Deke. The fixation proximal femur nailing system: biomechanical properties of the nail and a cadaveric study" Journal of biomechanics 2005; 38:63-68.
9. Pajarinen J. pertrochanteric femoral fractures treated with a dynamic hip screw or a proximal femoral nail. A randomized study comparing post operative rehabilitation. JBJS (Br) 2005; 87(1):76-81.
10. Kenneth KJ, Joseph ZD. Hip fractures-A practical guide to management page, 191-252.